Contents

Heart

- Radiology of the cardiovascular system 2
- Normal heart X ray 6
- Radiological signs of cardiac chambre enlargement 8
- Cardiomegaly without characteristic shape 13
- Cardiomegaly with characteristic shape 18
  . Pericardial effusion (flask shaped heart) 18
  . Fallot tetralogy (boot shaped heart) 20
  . Transposition of great arteries (egg shaped heart) 21
- Isolated dextrocardia 22
- Dextrocardia with situs inversus 23

Chest

- Radiology of the respiratory system 24
- Normal chest X ray 26
- Unilateral opacity occupying one side 28
  . Pleural effusion 29
  . Lobar pneumonia 37
  . Lung fibrosis 42
  . Lung collapse 43
- Bilateral small opacities 47
  . Miliary shadows 48
  . Bronchopneumonia 50
  . Bronchiectasis 52
- Air fluid level 53
  . Lung abscess 54
  . Hydropneumothorax or pyopneumothorax 59
- Unilateral hypertranslucency 61
  . Pneumothorax 62
  . Emphysema 63
- Hilar shadows 64

Bones

- Radiology of long bones 65
- Normal bone 66
- Chronic hemolytic anemia 67
- Active rickets 69
- Healing rickets 71
- Healed rickets 73
- Osteogenesis imperfecta 74
- Osteopetrosis 76

Skull

- Normal skull X ray 78
- Microcephaly 79
- Increased intracranial tension 80
- Craniostenosis 83
- Chronic hemolytic anemia 84
- Intracranial calcification 85

Abdomen

- Congenital hypertrophic pyloric stenosis 87
- Duodenal atresia 89
- Intestinal obstruction (low obstruction) 90

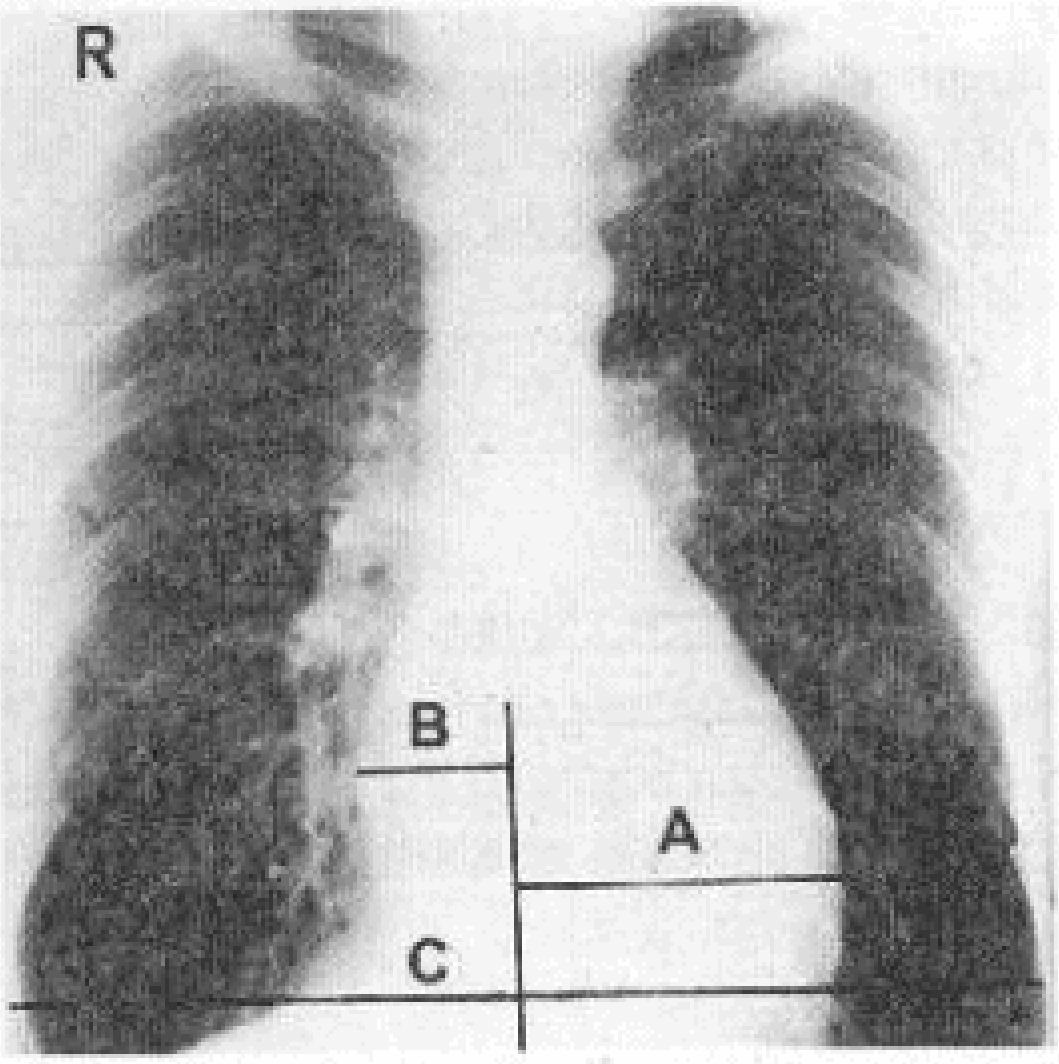

Comment as: *Cardio-thoracic ratio is normal or Cardio-thoracic ratio increased.*

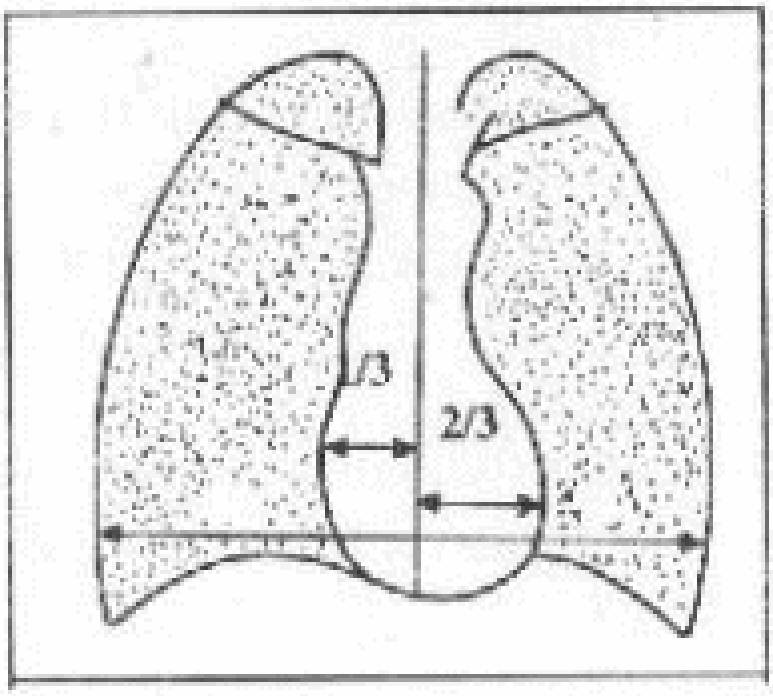

Normally, two third of the cardiac shadow lies to the left side of the middle line and one third to the right.

6- Cardiophrenic angle on the left side
It is the angle between the left copula of the diaphragm and left border of heart, normally it is acute angle

Normal heart X ray

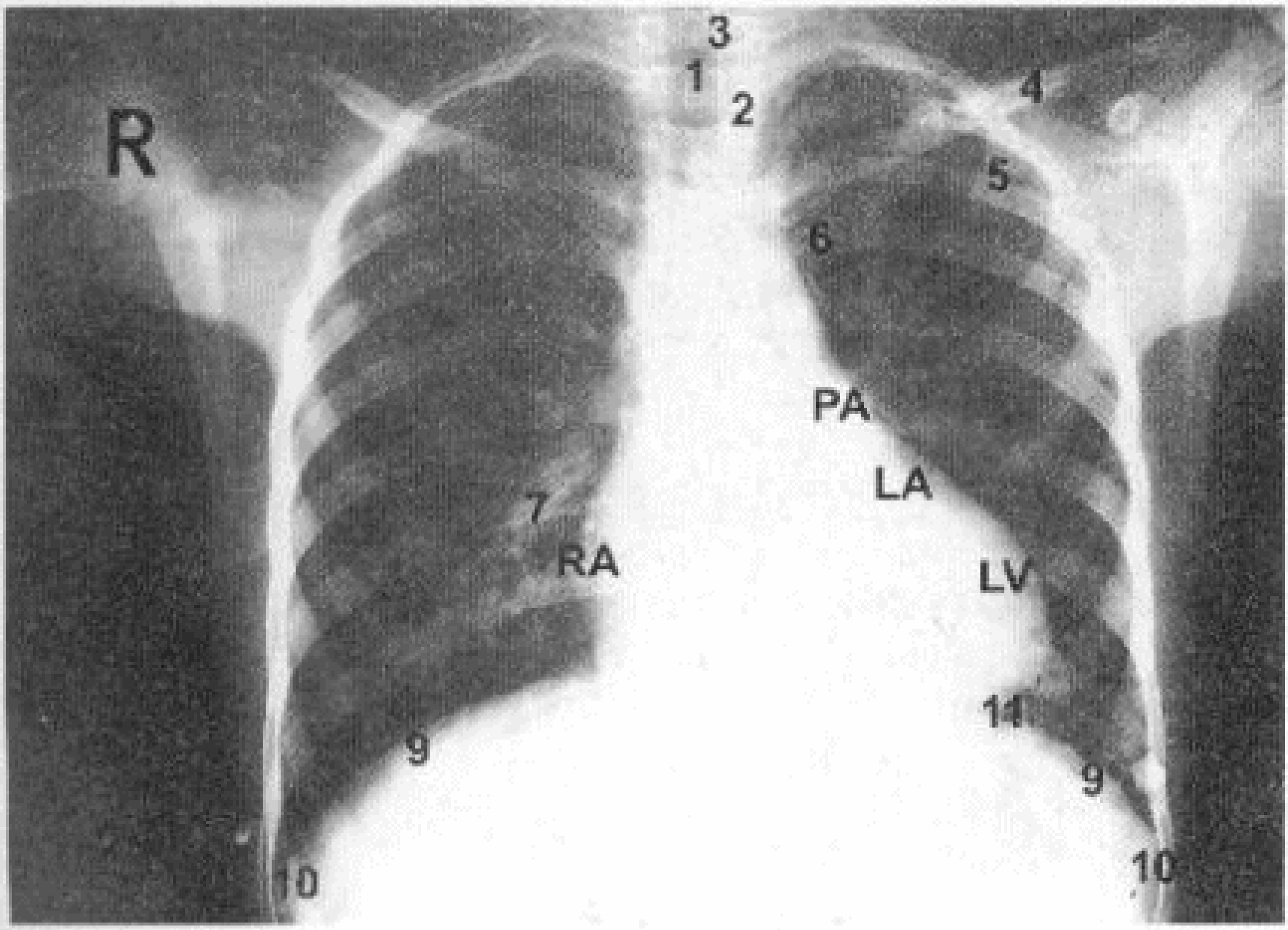

1- Tracheal air column
2- Vertebral column
3- Spinous processes of the vertebrae
4- Clavicles
5- Anterior ribs
6- Posterior ribs
7- Bronchovascular markings
8- Lung fields
9- Diaphragmatic copulae
10- Costophrenic angles
11- Cardiophrenic angle
RA: - right atrium
PA: - Pulmonary artery
LA: - left atrium
LV: - left ventricle

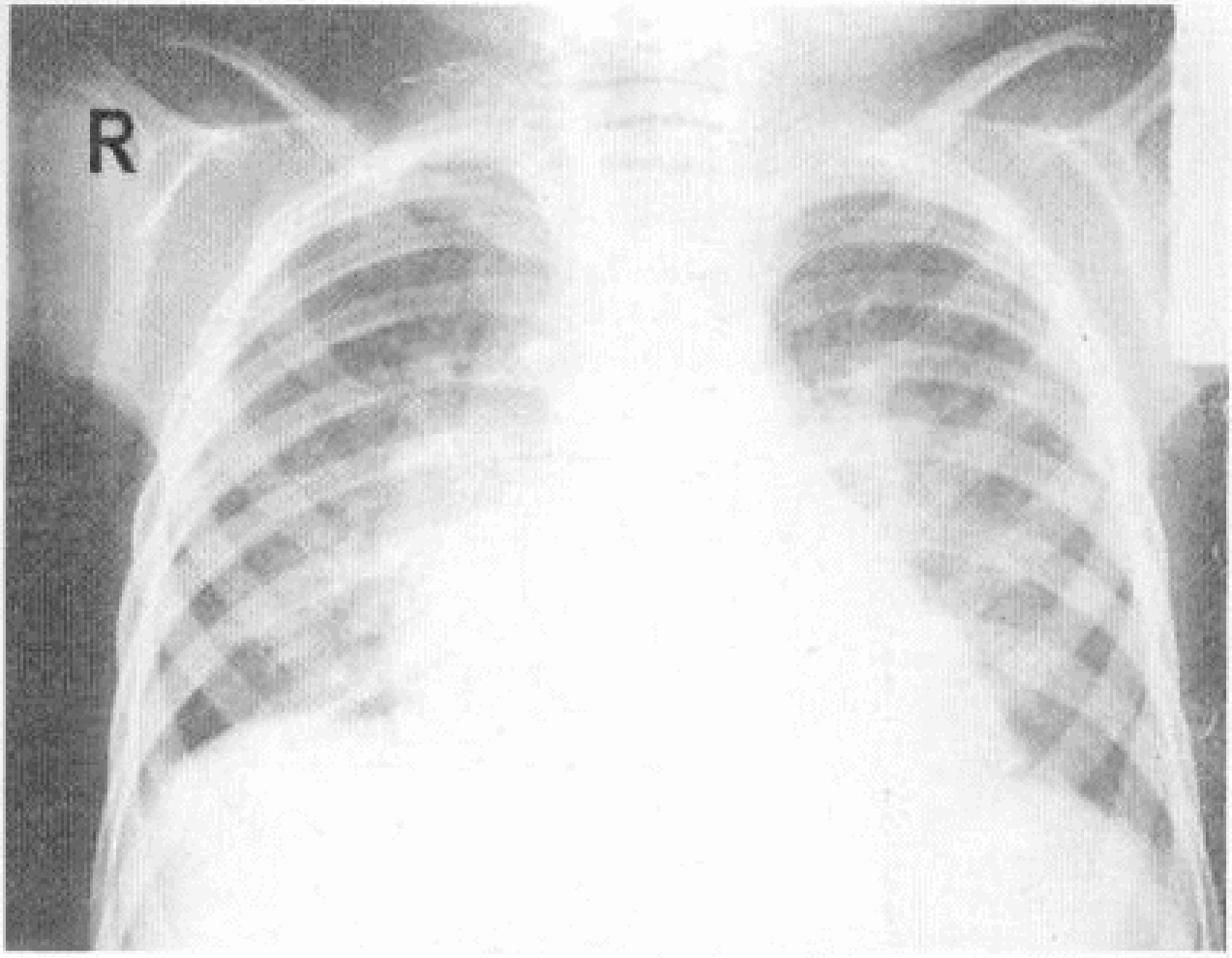

Left ventricular enlargement

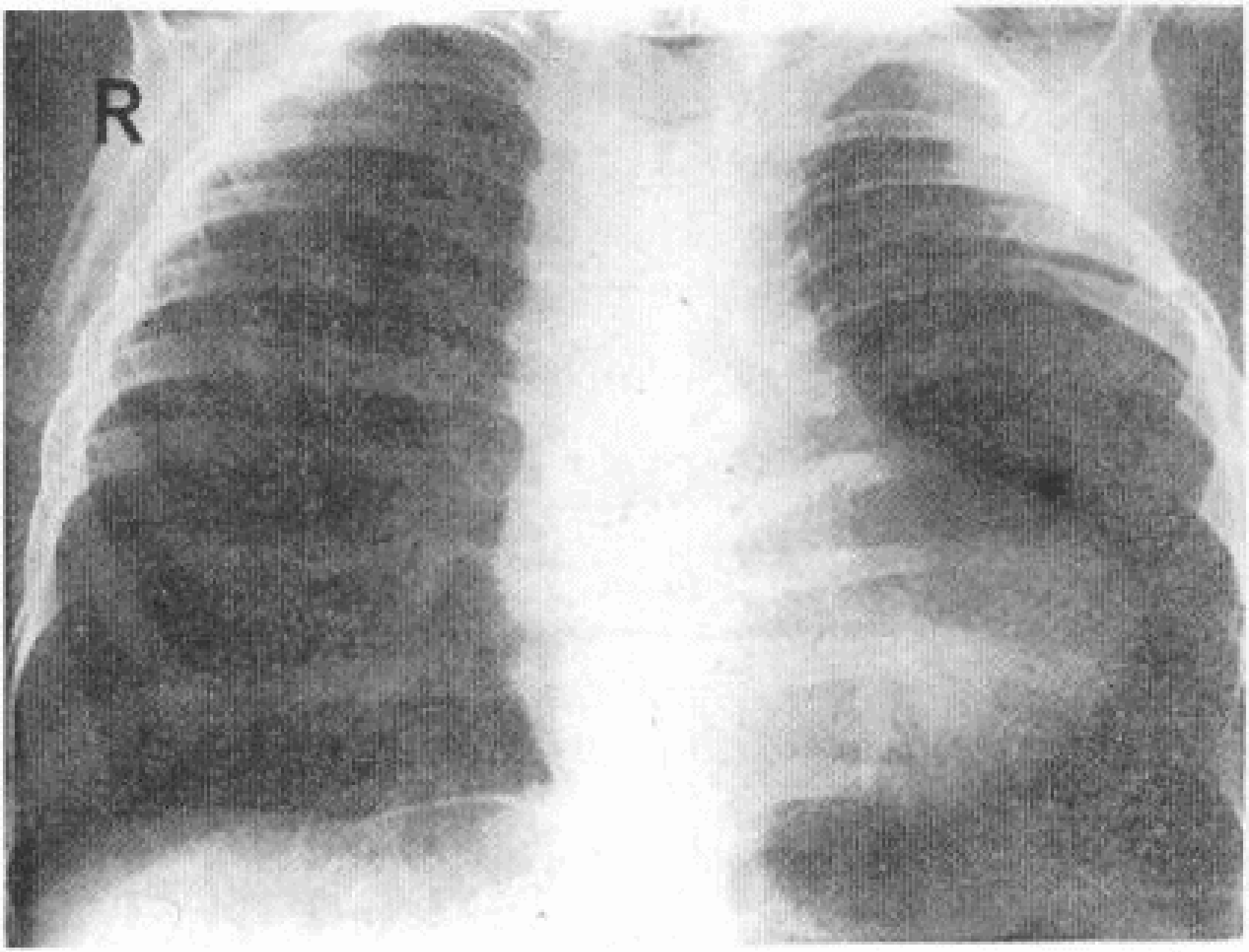

Right ventricular enlargement

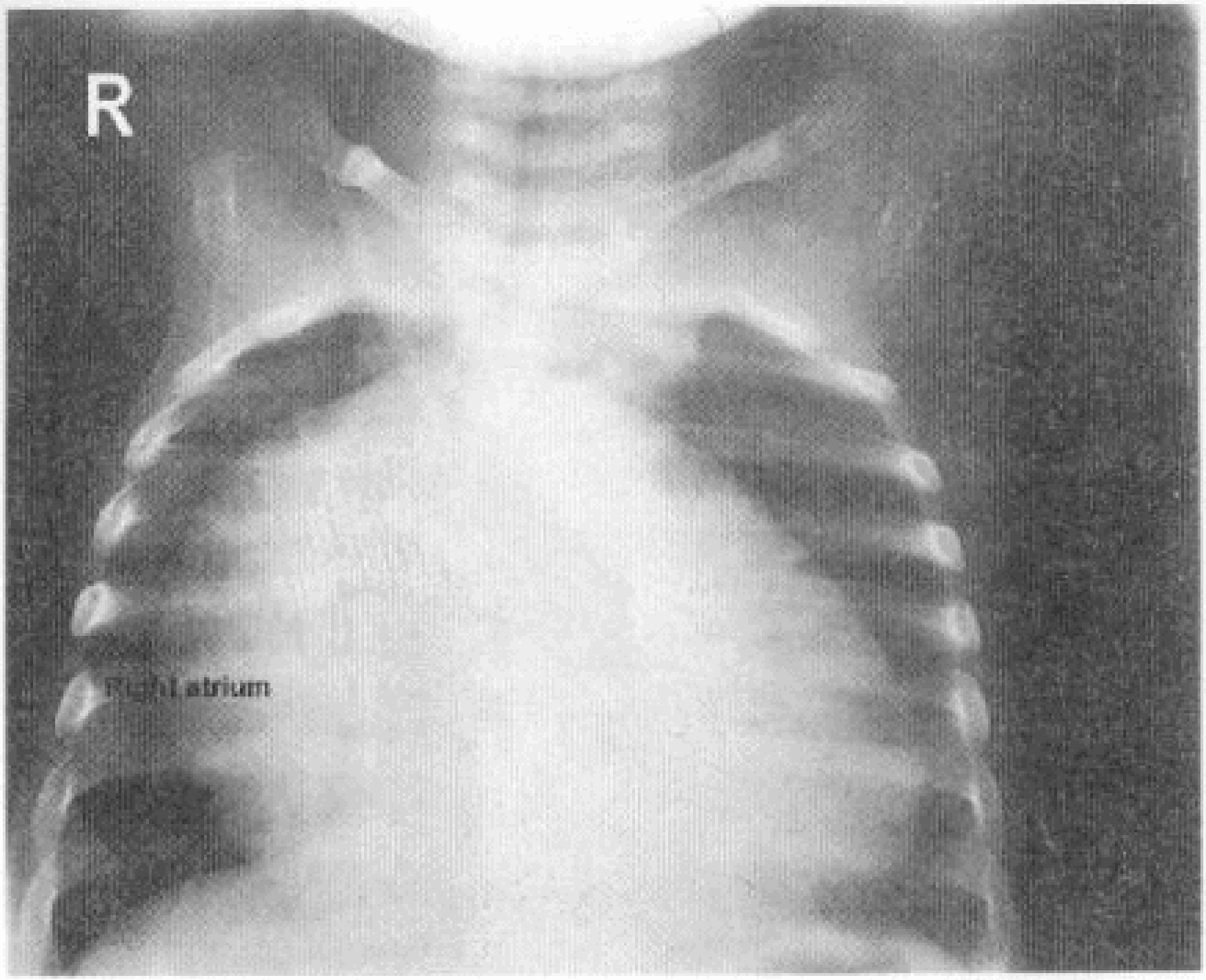

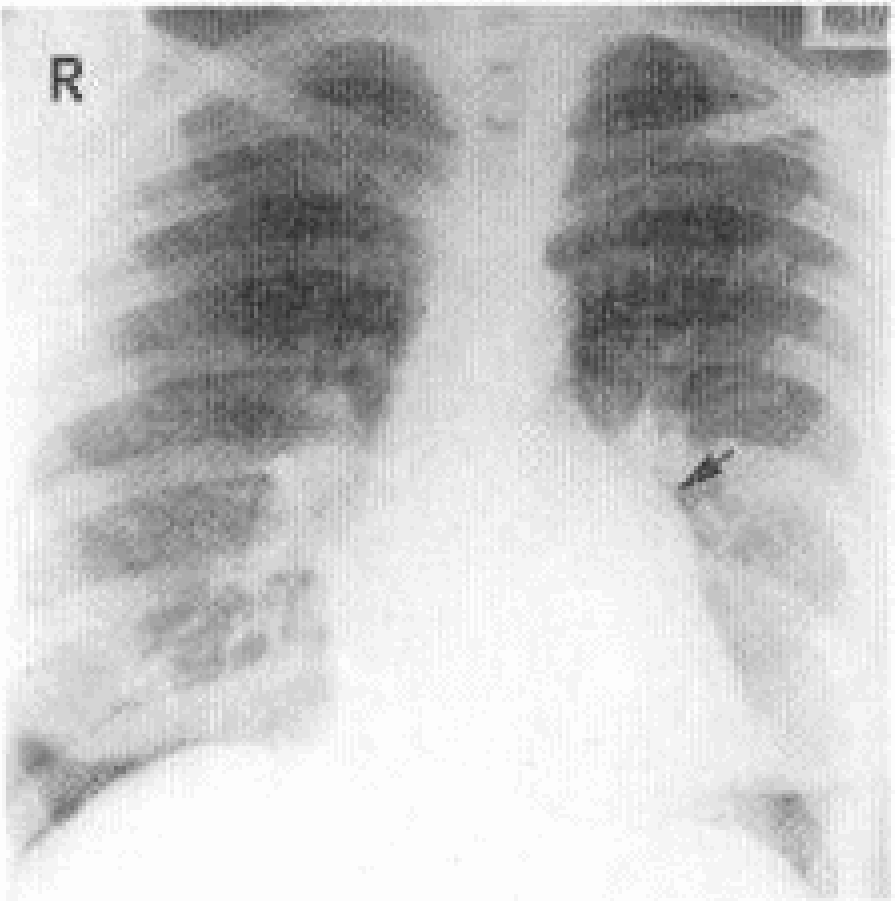

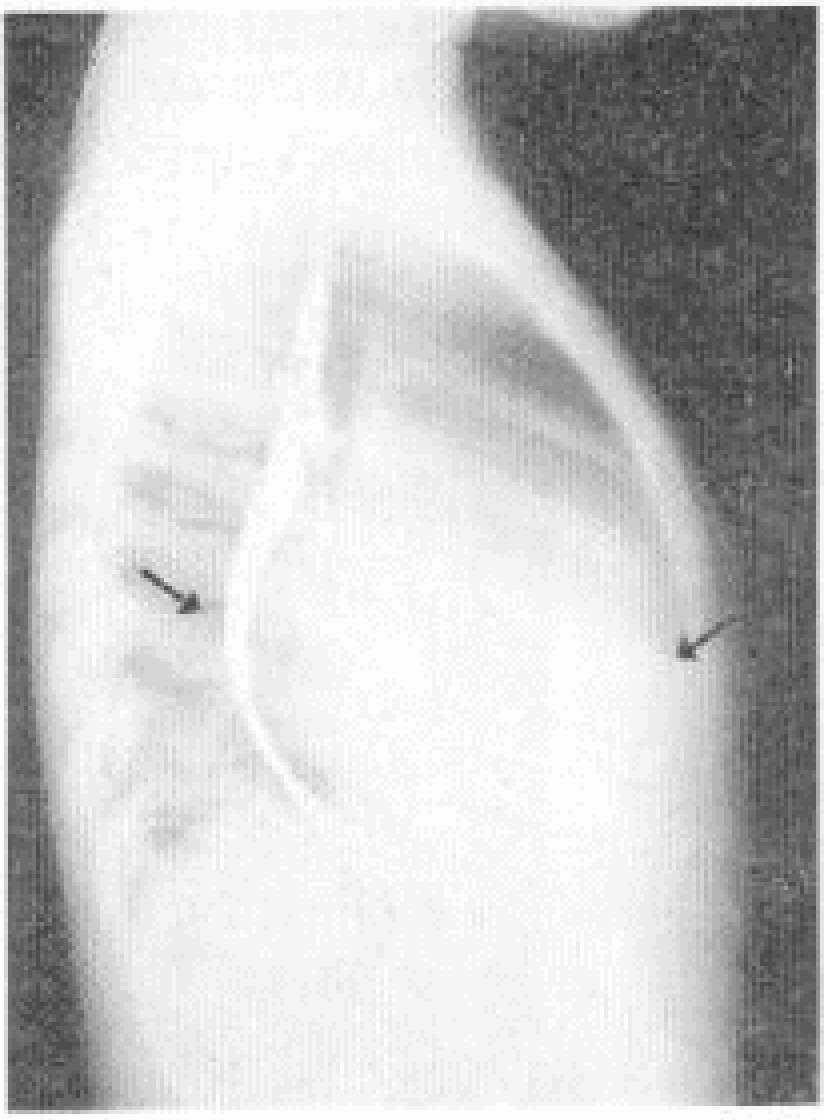

Left atrium dilatation

Radiological abnormalities of pulmonary blood vessels

1- Pulmonary plethora

. It results from increased blood flow to the lung e.g. ventricular septal defect

. Vascular markings are enlarged at the hilum and visible in the outer third of the lung filed.

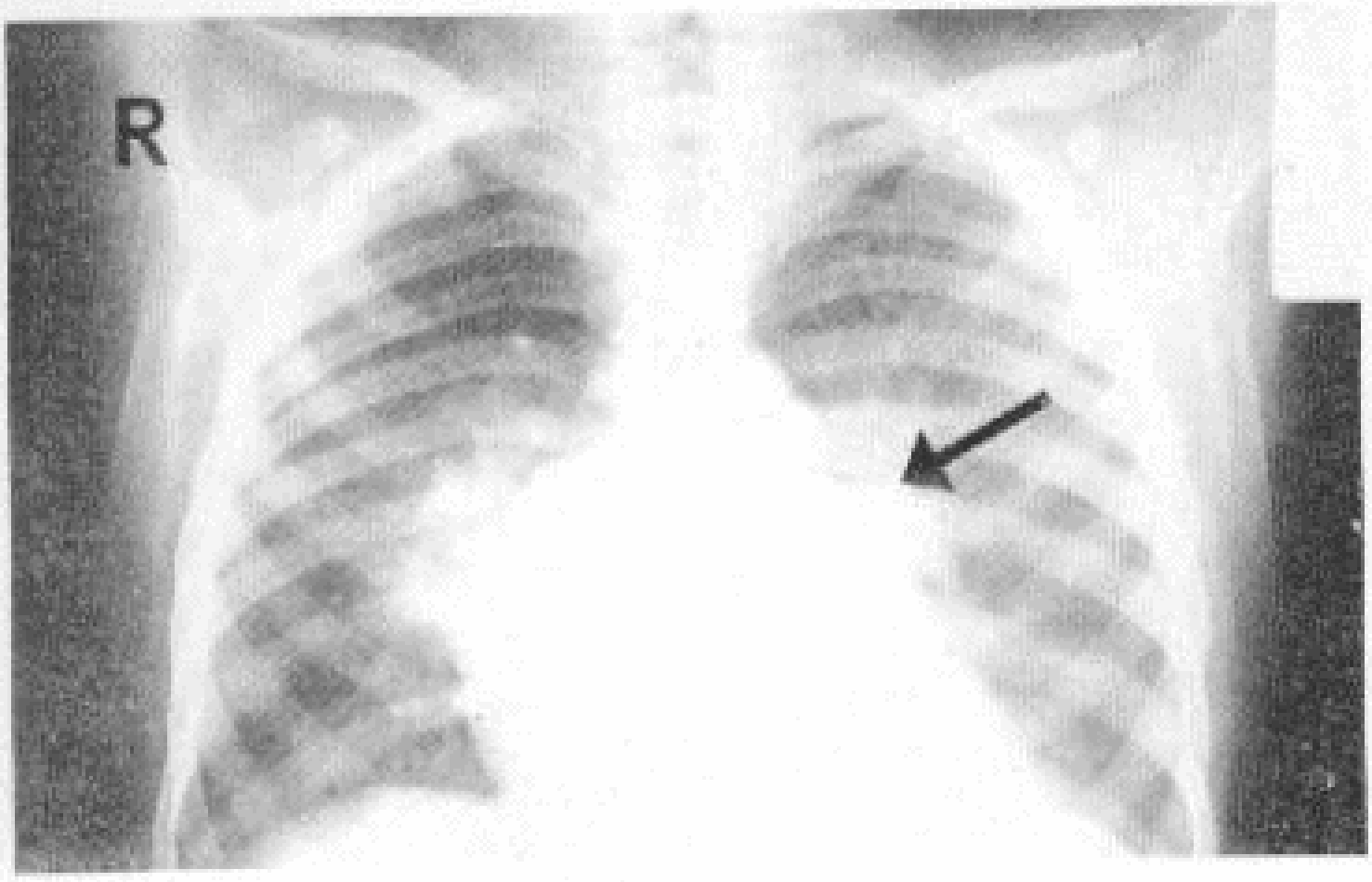

2- Pulmonary oligemia

. It results from decreased blood flow to the lung e.g. Fallot tetralogy

. The vascular markings are few and only seen in the hilum

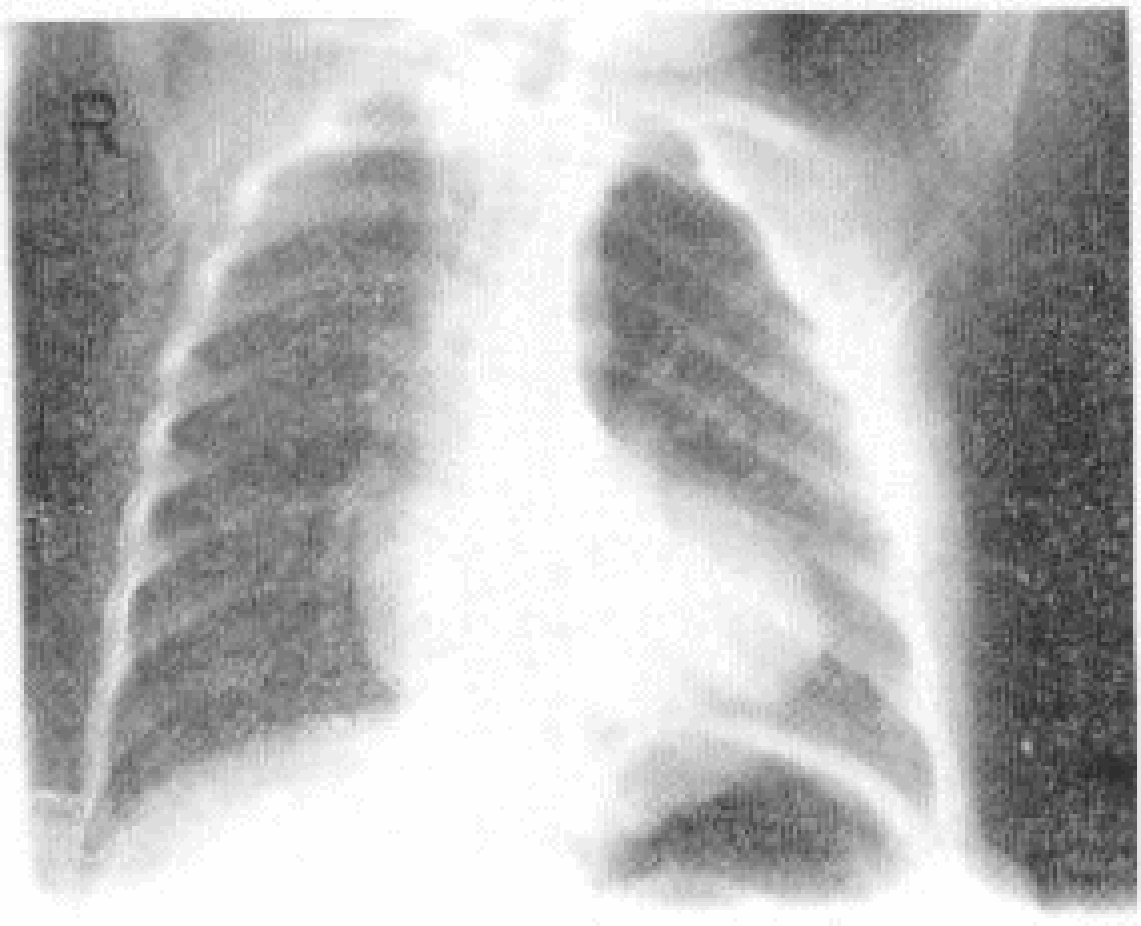

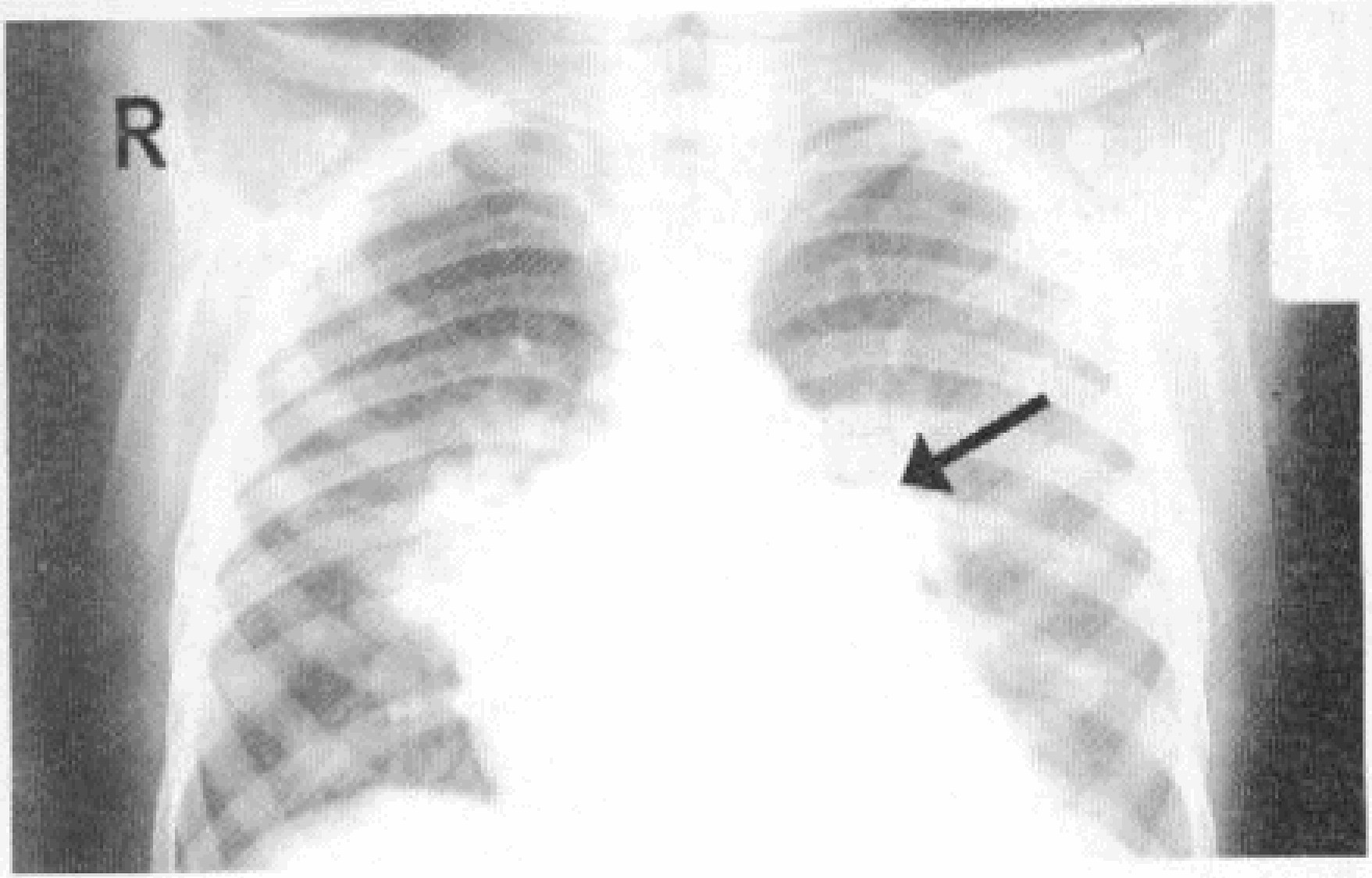

- Plain X ray chest and heart
- Postero-anterior view
- The patient is well centralized
- Costophrenic angles are free on both sides
- Cardio-thoracic ratio increased
- Cardiophrenic angle on the left side is obtuse
- Bulging left cardiac border on the second space and third space
- Bulging right cardiac border
- Pulmonary plethora

Radiological diagnosis (anatomical diagnosis)

Cardiomegaly due to enlargement of left ventricle, left atrium pulmonary artery and right atrium

Etiological diagnosis: - Cardiomegaly for differential diagnosis

- Rheumatic heart disease
  Mitral valve lesion alone or in association with aortic valve
- Congenital heart disease e.g. ventricular septal defect
- Myocarditis and heart failure e.g. viral myocarditis
- Cardiomyopathy e.g. congestive cardiomyopathy

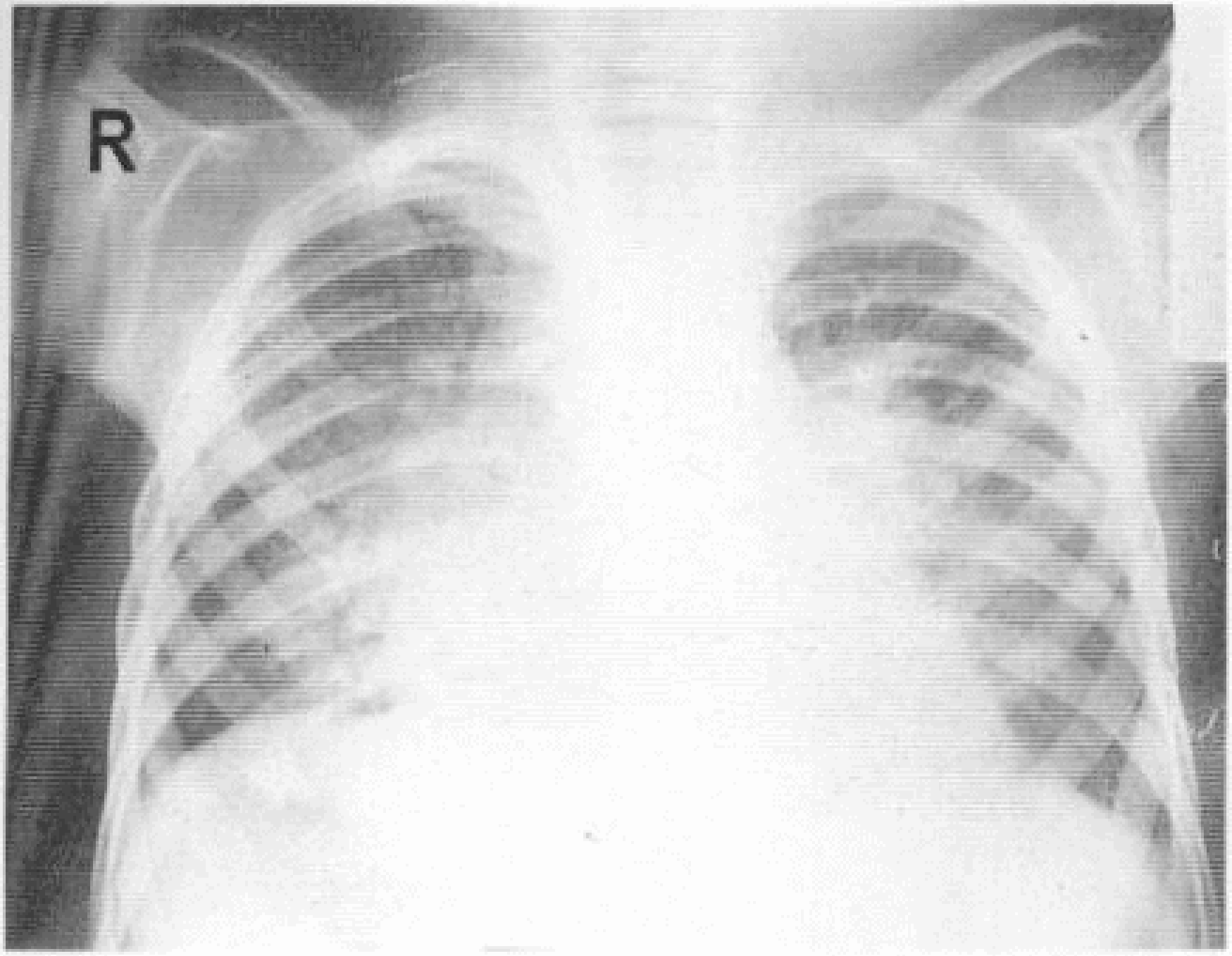

- Plain X ray chest and heart
- Postero-anterior view
- The patient is not well centralized
- Costophrenic angles are free on both sides
- Cardio-thoracic ratio increased
- Cardiophrenic angle on the left side is obtuse
- Straight left cardiac border (waist obliteration): mitralized heart
- Bulging right cardiac border
- Pulmonary plethora

Radiological diagnosis (anatomical diagnosis)

Cardiomegaly due to enlargement of left ventricle, left atrium, pulmonary artery and right atrium

Etiological diagnosis: - cardiomegaly for differential diagnosis

- Rheumatic heart disease
  Mitral valve lesion alone or in association with aortic valve
- Congenital heart disease e.g. ventricular septal defect
- Myocarditis and heart failure e.g. viral myocarditis
- Cardiomyopathy e.g. congestive cardiomyopathy

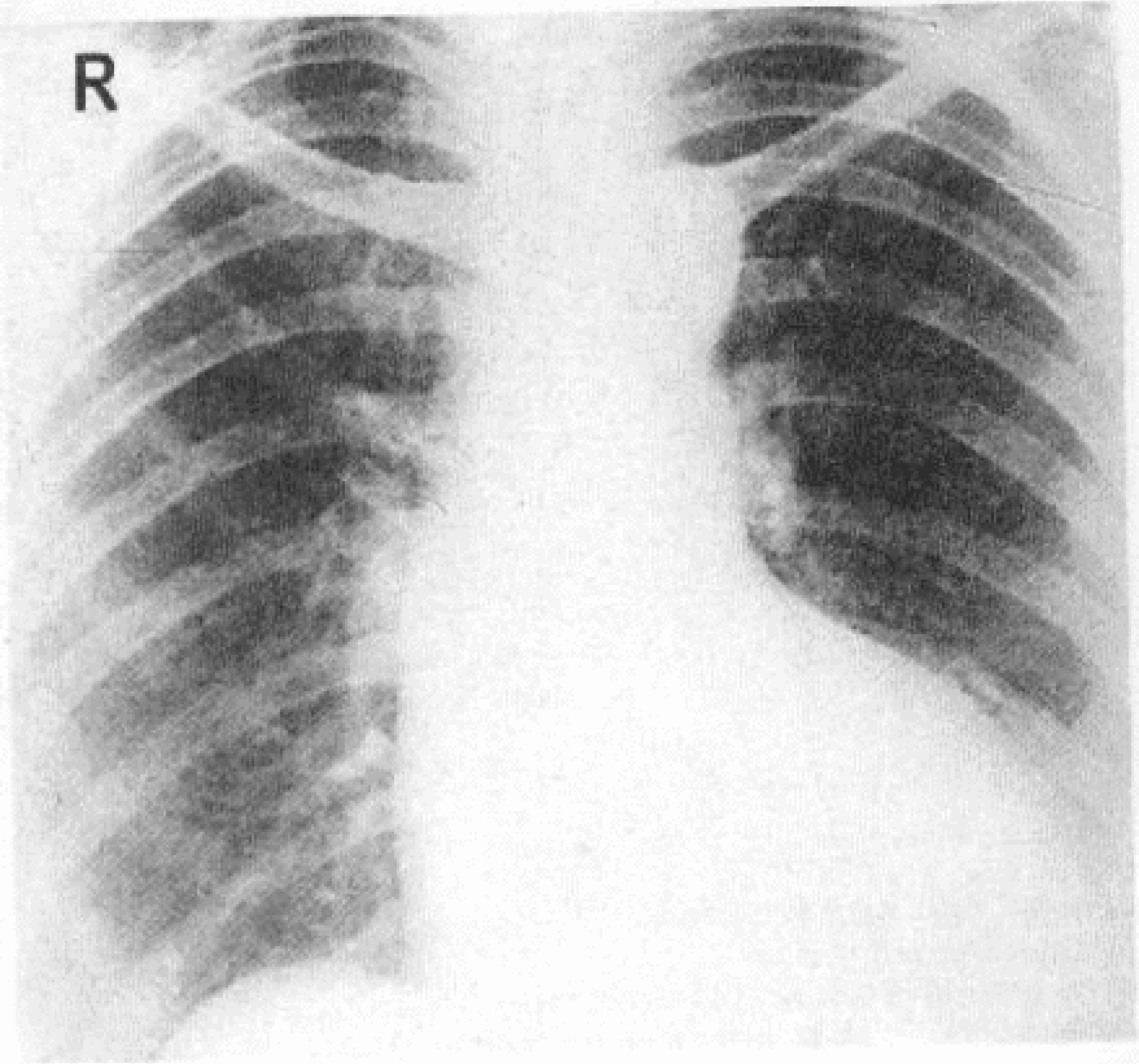

- Plain X ray chest and heart
- Postero-anterior view
- The patient is well centralized
- Costophrenic angles are free on both sides
- Cardio-thoracic ratio increased
- Cardiophrenic angle on the left side is obtuse
- Normal right cardiac border

Radiological diagnosis (anatomical diagnosis)

Cardiomegaly due to enlargement of left ventricle

Etiological diagnosis: - causes of left ventricular enlargement

- Aortic valve disease
- Systemic hypertension
- Mitral valve disease: mitral regurgitation

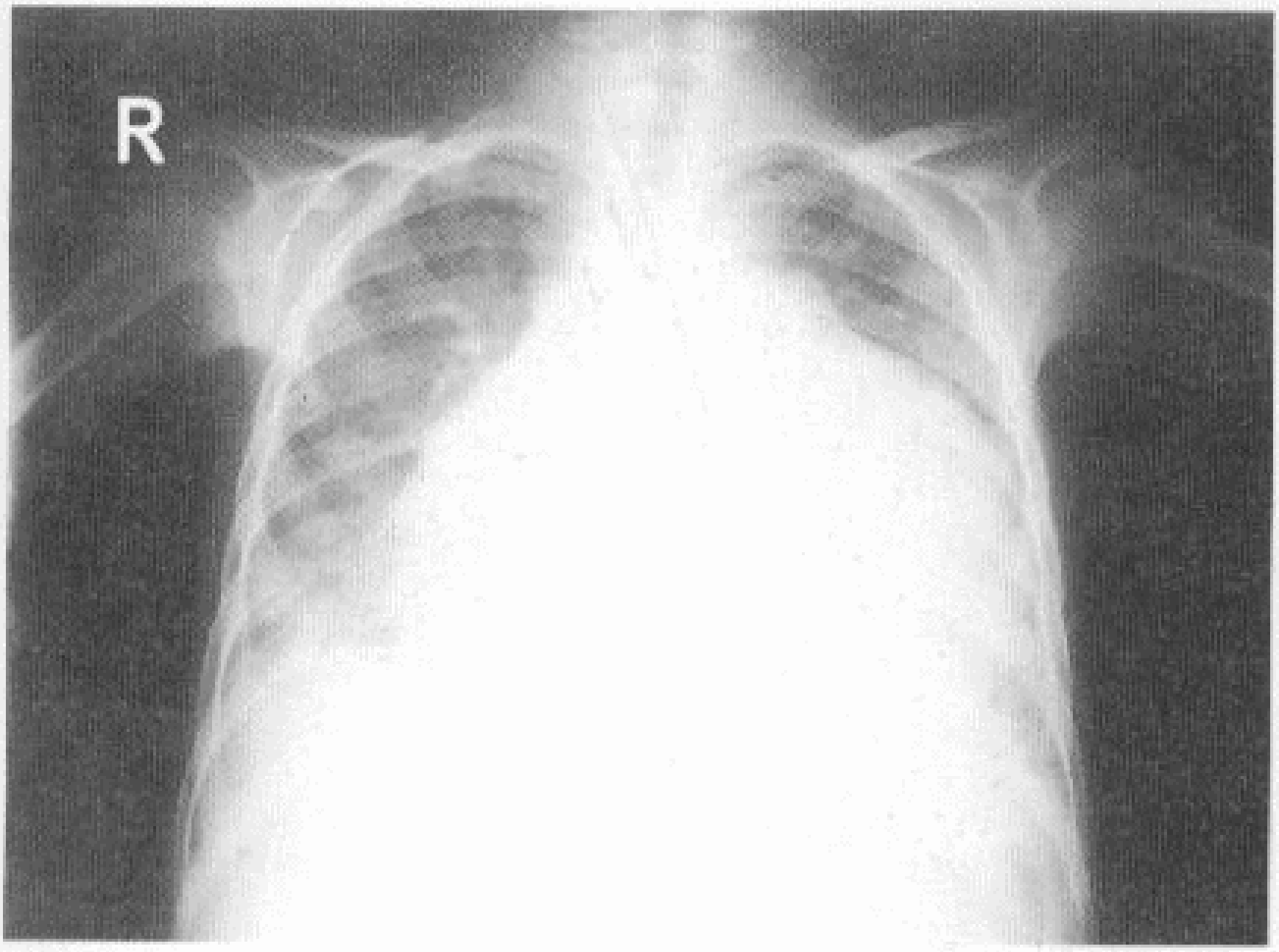

- Plain.X ray chest and heart
- Postero-anterior view
- The patient is well centralized
- Costophrenic angles are free on both sides
- Cardio-thoracic ratio increased markedly
- Cardiophrenic angle on the left side is obtuse
- Marked bulge of the left and right cardiac borders
- Increased in the pulmonary vascular markings

Radiological diagnosis (anatomical diagnosis)

Huge cardiomegaly due to marked enlargement of all cardiac chambers

Etiological diagnosis: - Cardiomegaly for differential diagnosis

- Rheumatic heart disease
  Mitral valve lesion alone or in association with aortic valve
- Congenital heart disease e.g. ventricular septal defect
- Myocarditis and heart failure e.g. viral myocarditis
- Cardiomyopathy e.g. congestive cardiomyopathy

However with huge cardiac shadow like this, pericardial effusion should be excluded by echocardiography

II- Cariomegaly with characteristic shape

1- Flask shaped heart: pericardial effusion

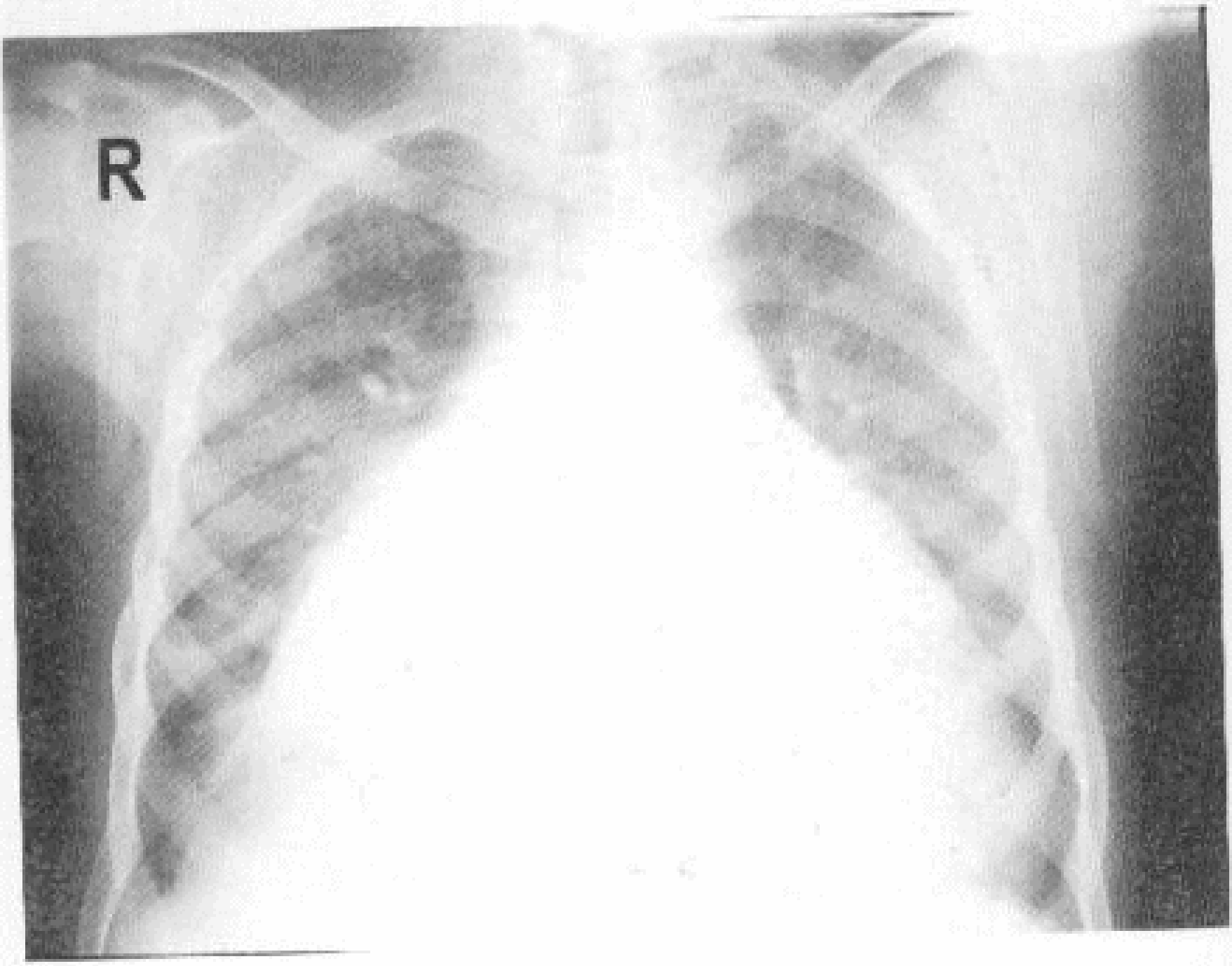

- Plain X ray chest and heart
- Postero-anterior view
- The patient is well centralized
- Costophrenic angles are free on both sides
- Cardiophrenic angle on the left side is acute
- Marked increase in the cardio-thoracic ratio
- Symmetrical bulge of the left and right cardiac borders
- The borders are very well defined (stenciled)
- Broad cardiac base(accumulation of fluid in the pericardial sac)
- Normal pulmonary vascular markings

Causes of pericardial effusion

- Serous: -
  Rheumatic disease: - rheumatic fever- systemic lupus
  Infections: - viral pericarditis- TB
- Pus: - suppurative pericarditis
- Blood: - trauma

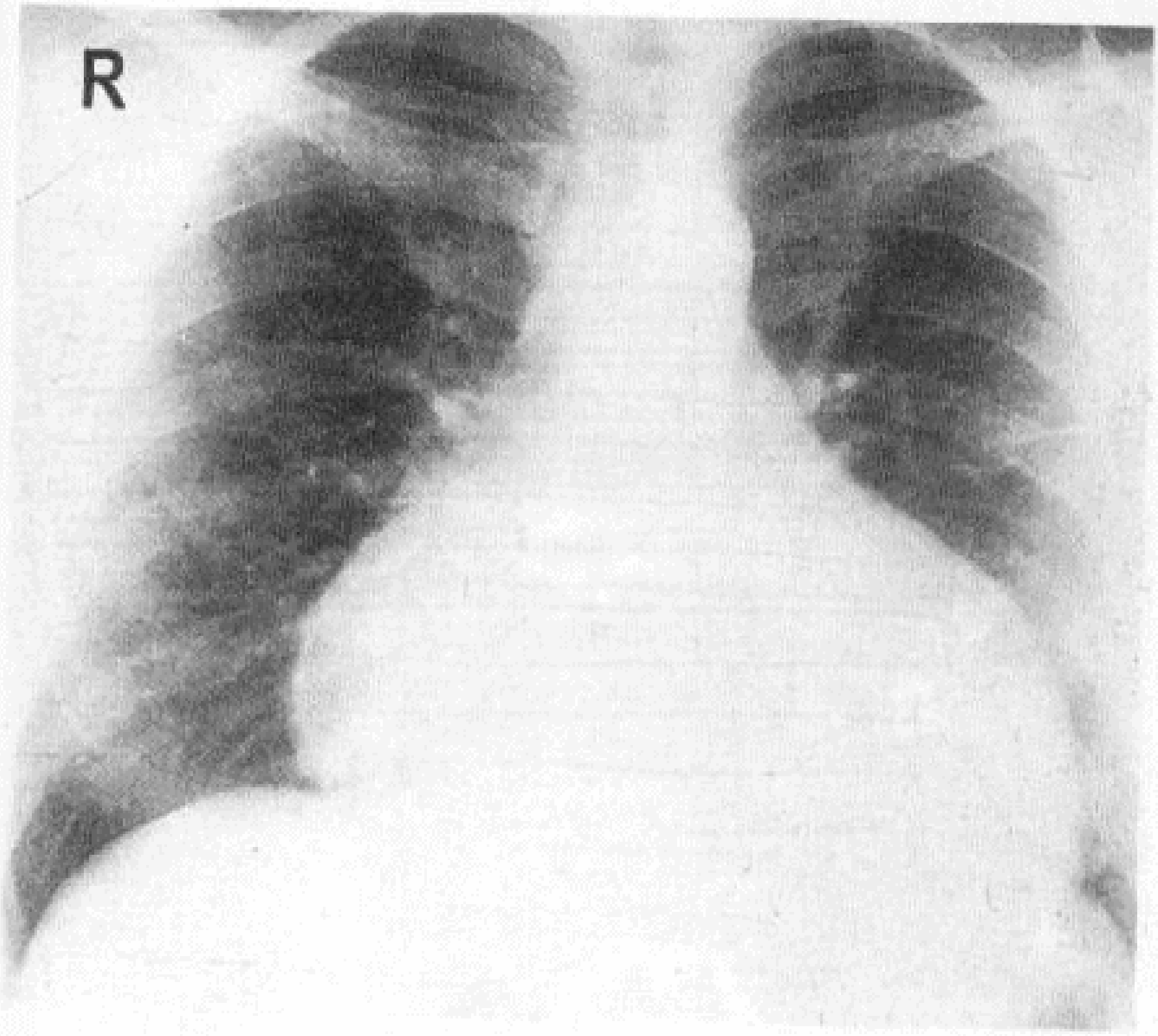

- Plain X ray chest and heart
- Postero-anterior view
- The patient is well centralized
- Costophrenic angles are free on both sides
- Cardiophrenic angle on the left side is acute
- Marked increase in the cardio-thoracic ratio
- Symmetrical bulge of the left and right cardiac borders
- The borders are very well defined (stenciled)
- Broad cardiac base(accumulation of fluid)
- Normal pulmonary vascular markings

Flask shaped heart: pericardial effusion

2- Boot shaped heart: Fallot tetralogy

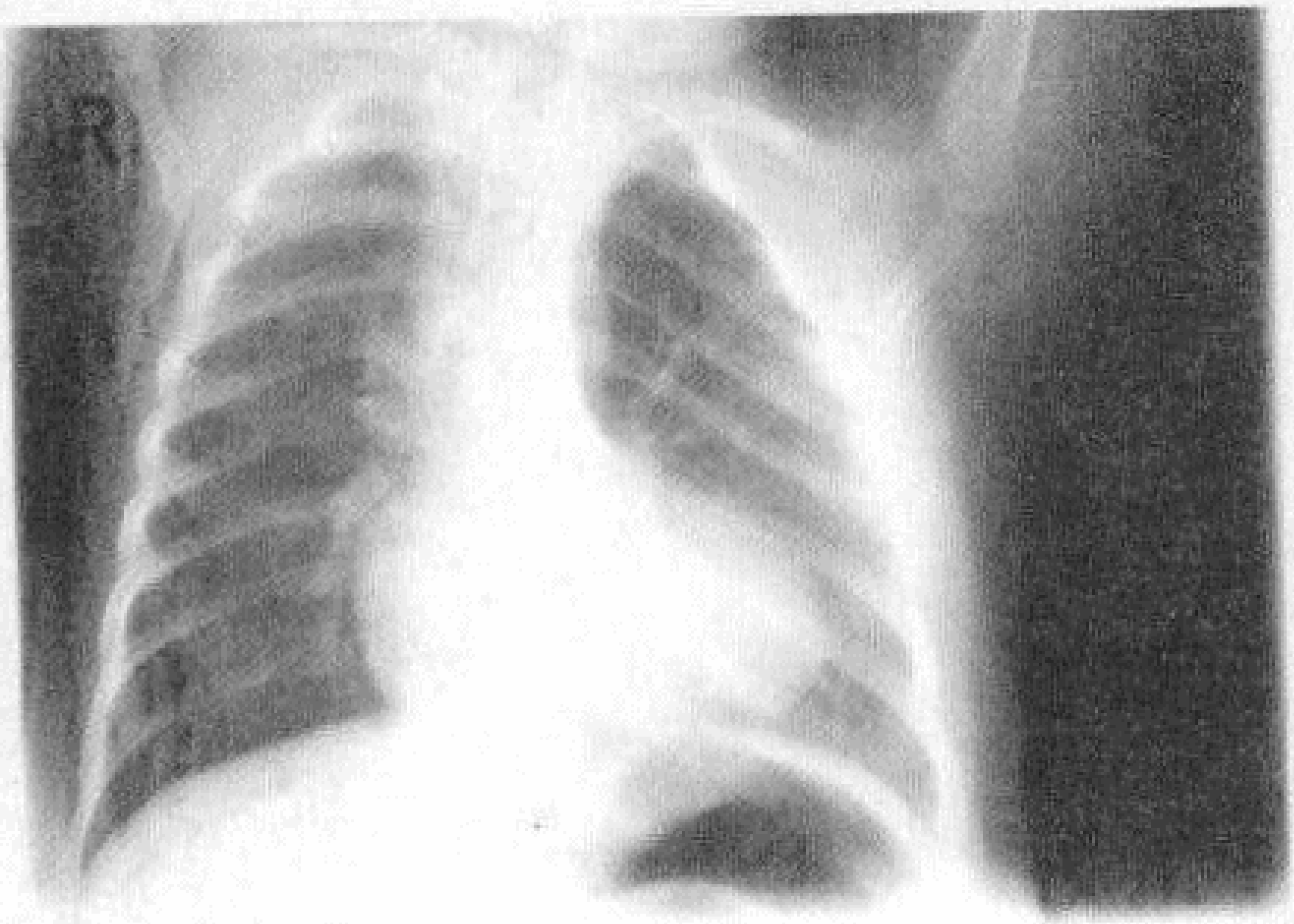

- Plain X ray chest and heart
- Postero-anterior view
- The patient is not centralized
- Costophrenic angles are free on both sides
- Cardio-thoracic ratio is normal or mildly increased
- Cardiophrenic angle on the left side is acute with uplifted apex
- Exaggerated waist (pulmonary hypoplasia)
- Decreased pulmonary vascular markings(lung oligemia)

3- Egg shape heart: transposition of great arteries (TGA)

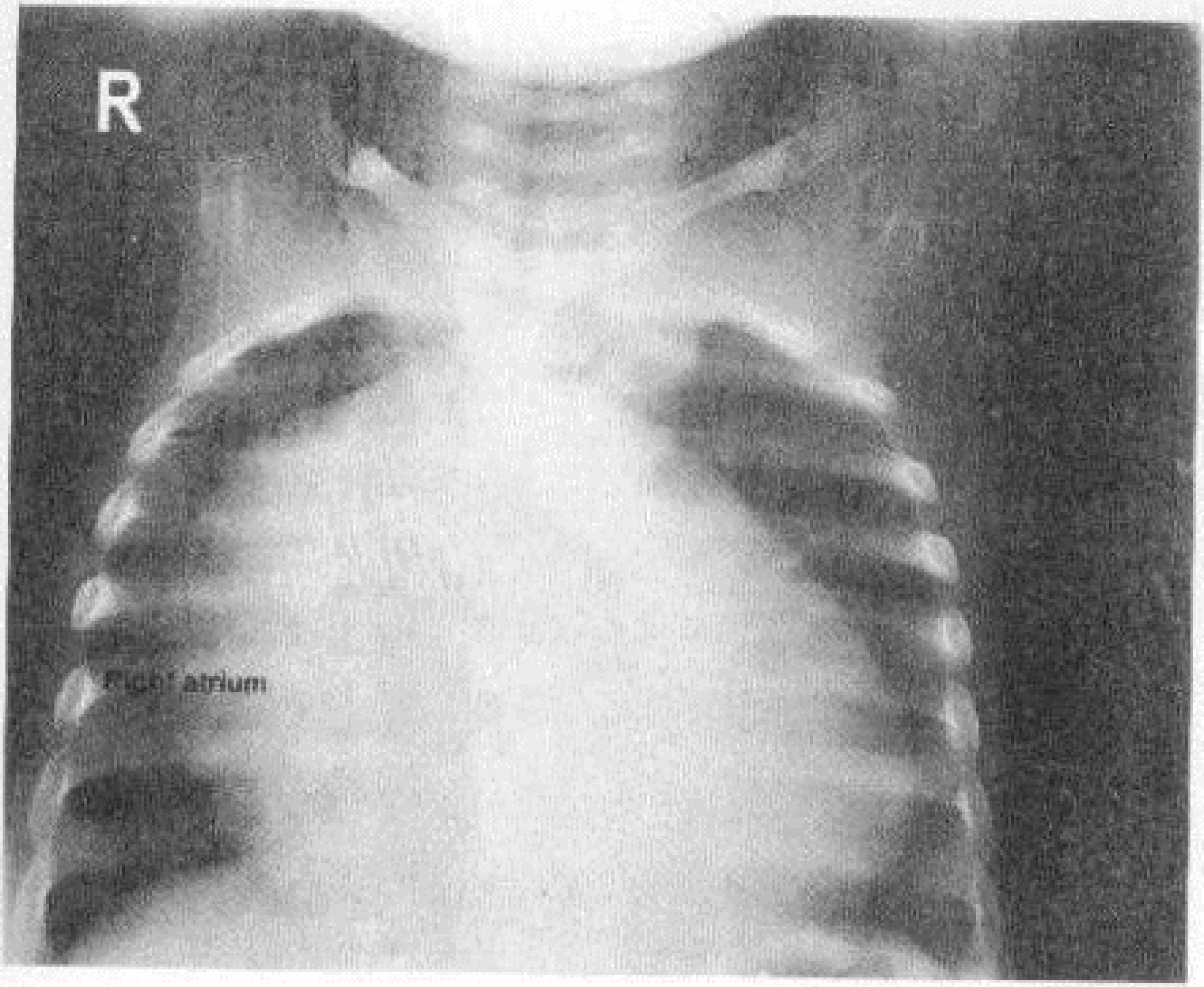

- Plain X ray chest and heart
- Postero-anterior view
- The patient is not centralized
- Costophrenic angles are free on both sides
- Cardio-thoracic ratio increased
- Cardiophrenic angle on the left side is acute (right ventricle)
- Marked bulge of the right border (right atrium)
- Narrow cardiac base (the aorta is displaced anteriorly)
- Increased pulmonary vascular markings

III- Abnormalities of the cardiac site

1- Isolated dextrocardia

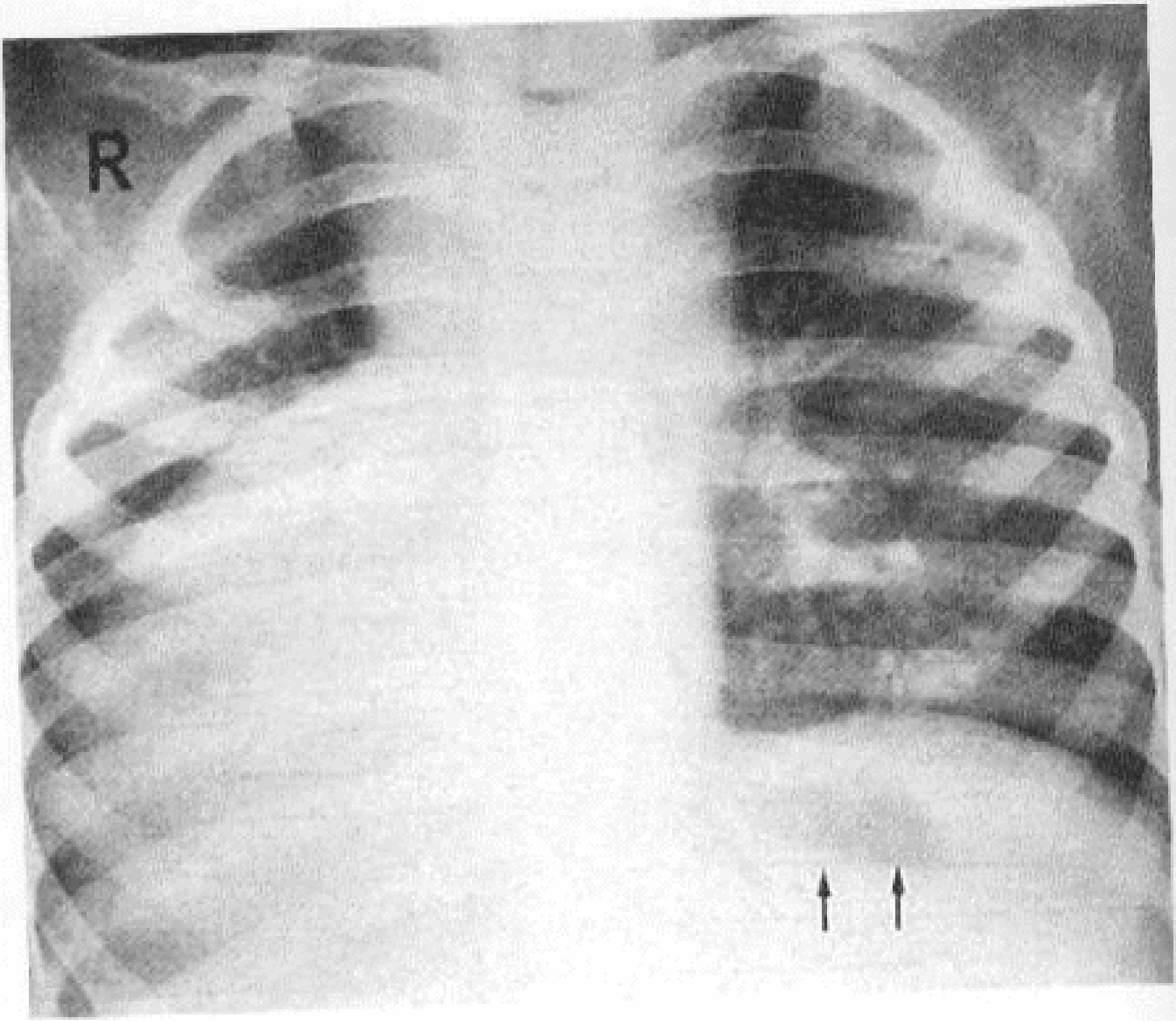

- Plain X ray chest and heart
- Postero-anterior view
- The patient is centralized
- Costophrenic angles are free on both sides
- Cardio-thoracic ratio is mildly increased

- Abnormal site of the heart
  . The heart lies mainly to the right side
  . The cardiac apex is on the right side
  . The left border is formed by right atrium while the right one is formed by pulmonary artery, left atrium and left ventricle
- The stomach is normal in site (gastric air bubbles on the left side)

2- Dextrocardia with situs inversus

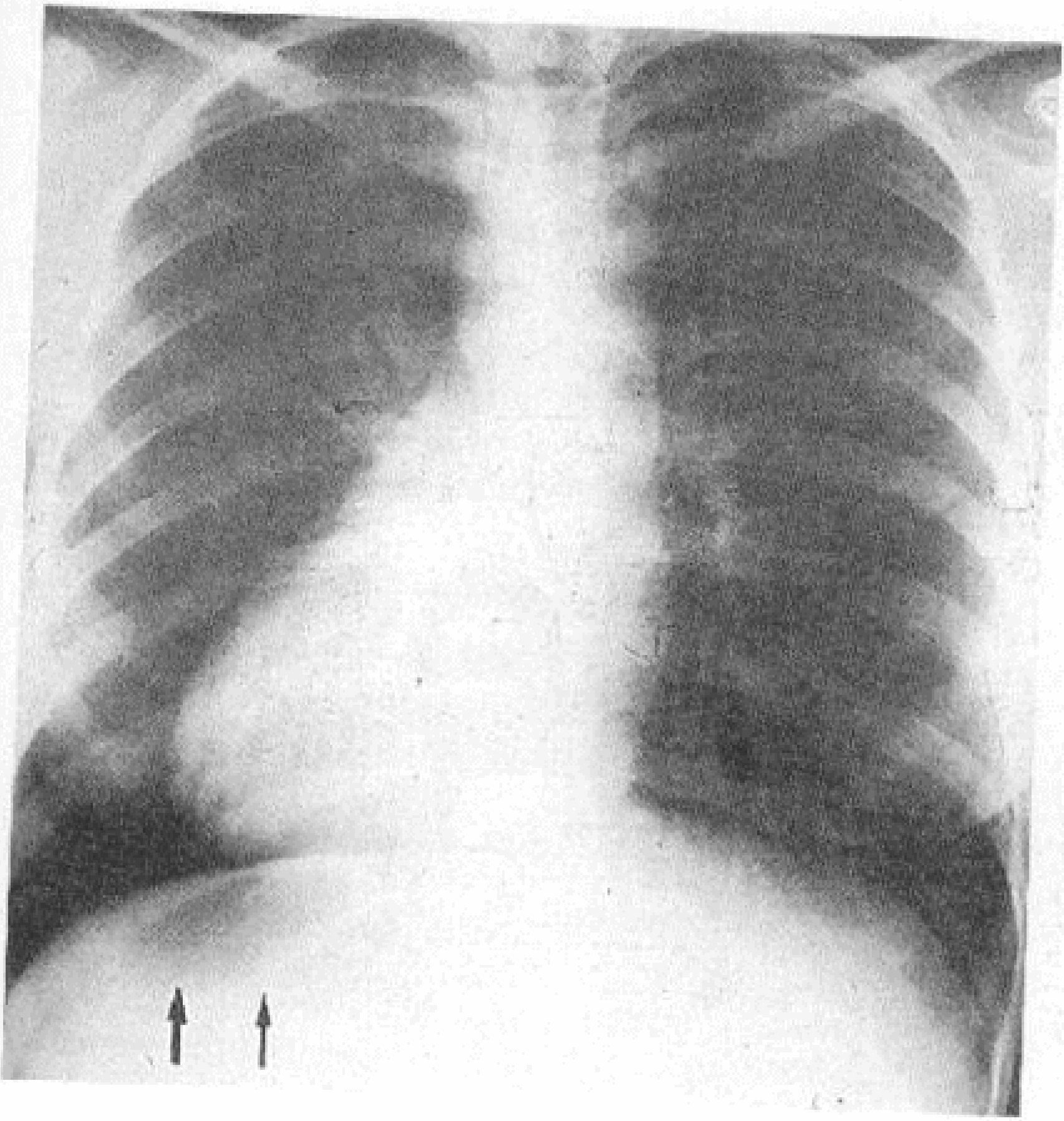

- Plain X ray chest and heart
- Postero-anterior view
- The patient is centralized
- Costophrenic angles are free on both sides
- Cardio-thoracic ratio is normal
- Abnormal site of the heart
  . The heart lies mainly to the right side
  . The cardiac apex is on the right side
  . The left border is formed by right atrium while the right one is formed by pulmonary artery, left atrium and left ventricle
- Abnormal position of the stomach and liver (gastric air bubbles on the right side while the liver shadow is on the left side)

Normal chest X ray

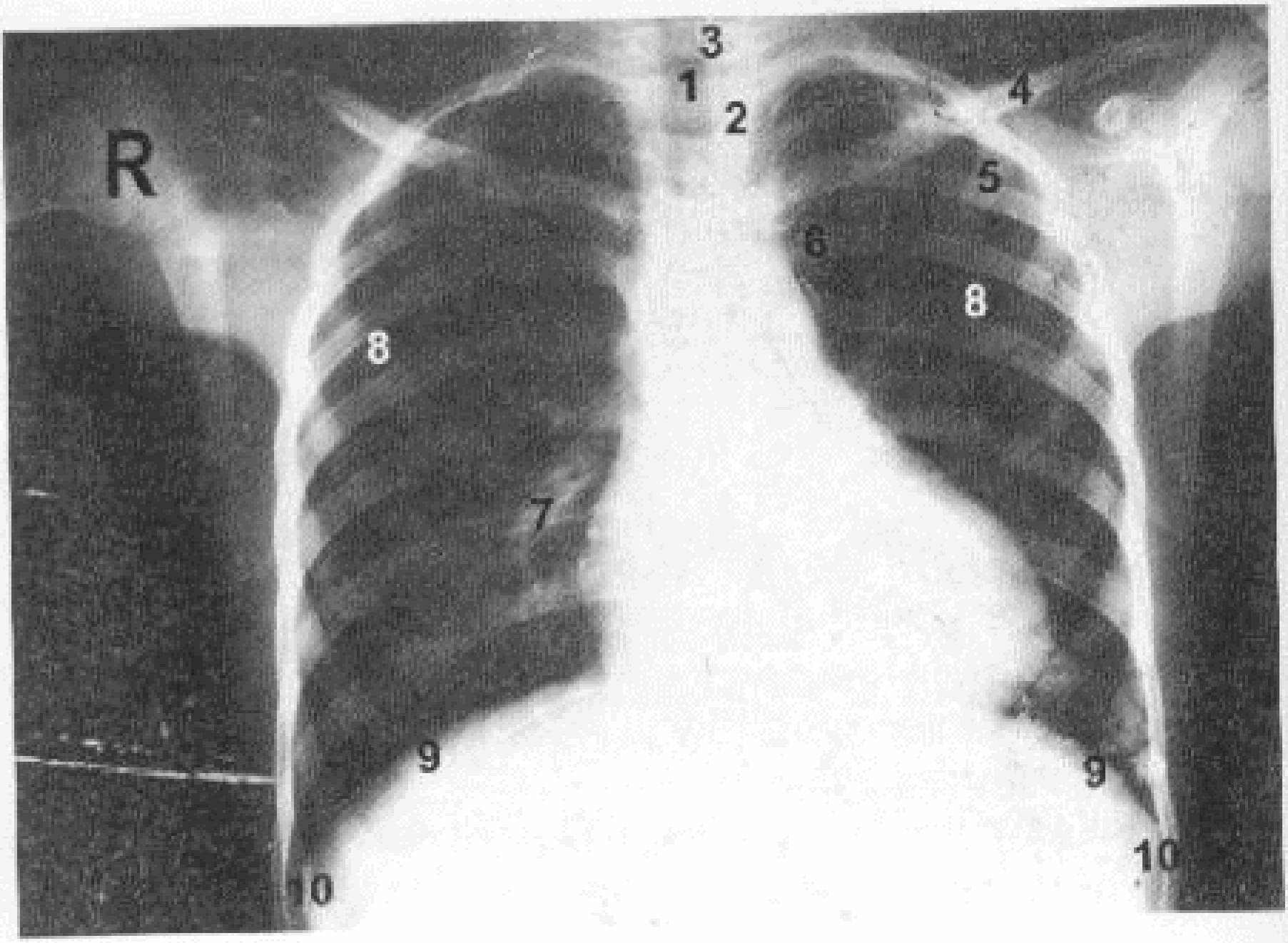

1- Tracheal air column
2- Vertebral column
3- Spinous processes of the vertebrae
4- Clavicles
5- Anterior ribs
6- Posterior ribs
7- Bronchovascular markings
8- Lung fields
9- Diaphragmatic copulae
10- Costophrenic angles

1- Pleural effusion

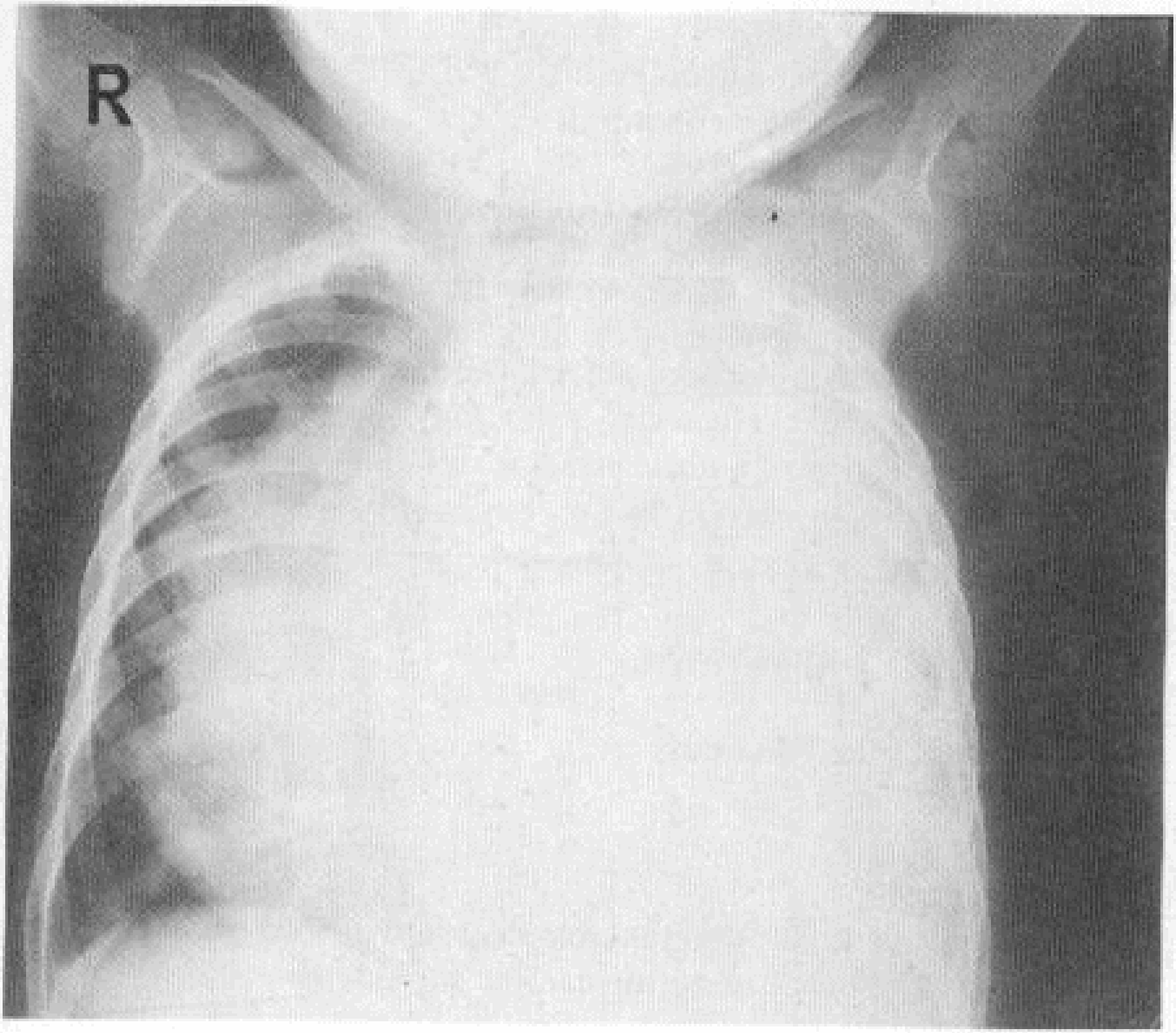

- Plain X ray chest and heart
- Postéro-anterior view
- The patient is centralized
- Costophrenic angle on the right side is free,
- Costophrenic angle on the left side is obliterated by homogenous opacity occupying all the left hemithorax.
- The mediastinum is shifted to the opposite side of the lesion

Left side massive pleural effusion

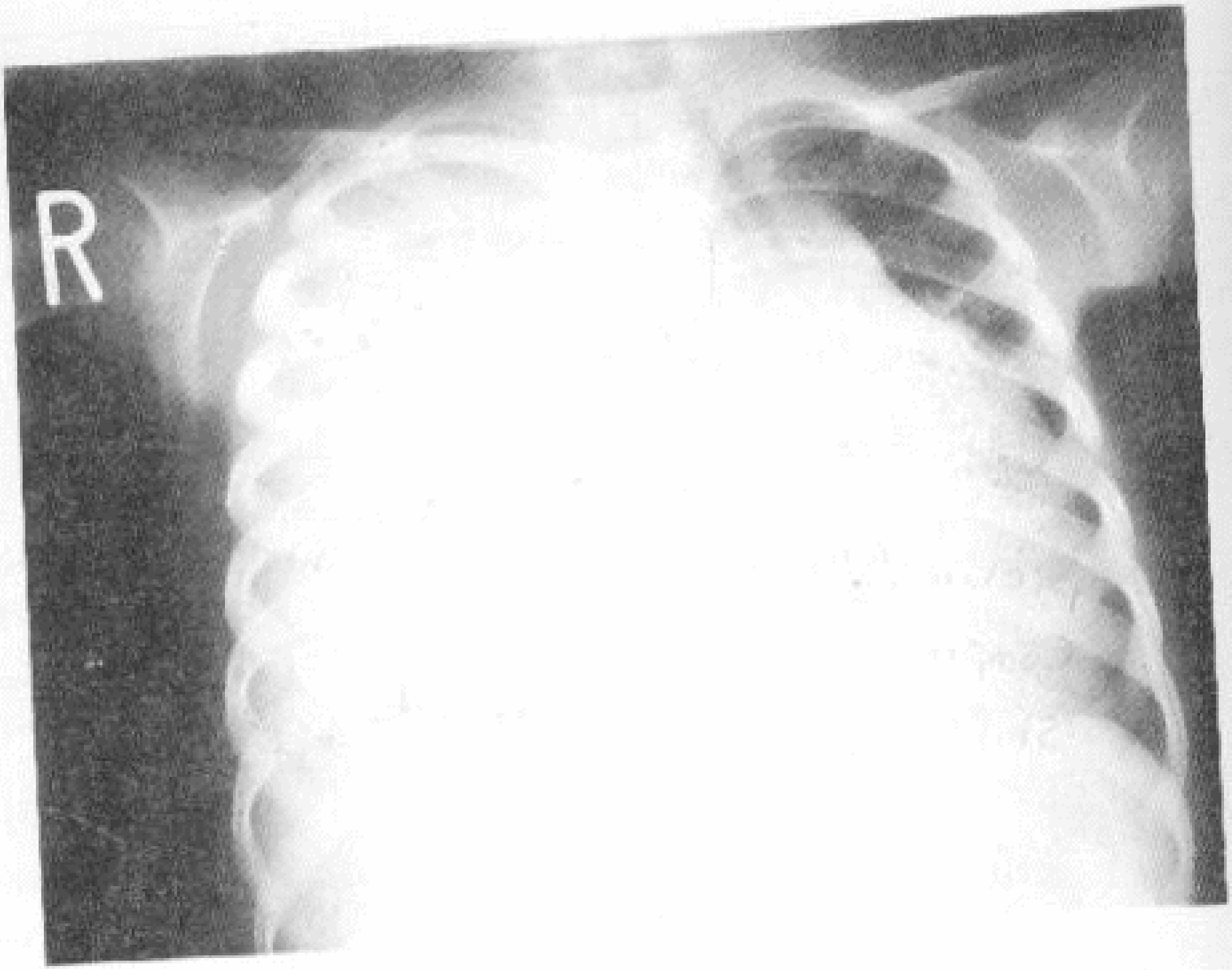

- Plain X ray chest and heart
- Postero-anterior view
- The patient is centralized
- Costophrenic angle on the left side is free
- The right costophrenic angle is obliterated by homogenous opacity occupying all the right hemithorax
- The mediastinum is shifted to the opposite side of the lesion

<u>Right side massive pleural effusion</u>

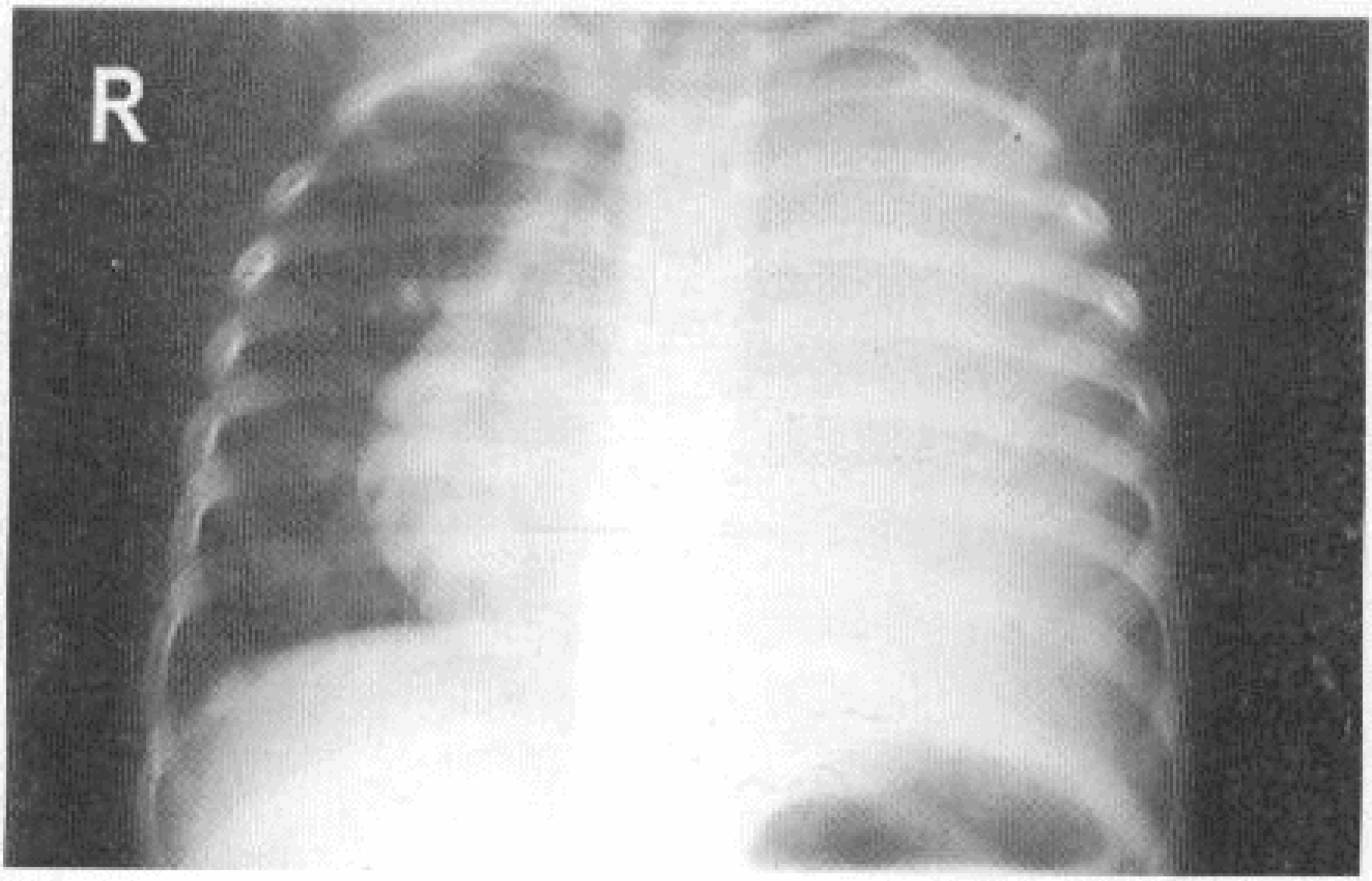

- Plain X ray chest and heart
- Postero-anterior view
- The patient is centralized
- The right costophrenic angle is free
- The left costophrenic angle is obliterated by homogenous opacity occupying all the left hemithorax
- The mediastinum is shifted to the opposite side of the lesion

<u>Left side massive pleural effusion</u>

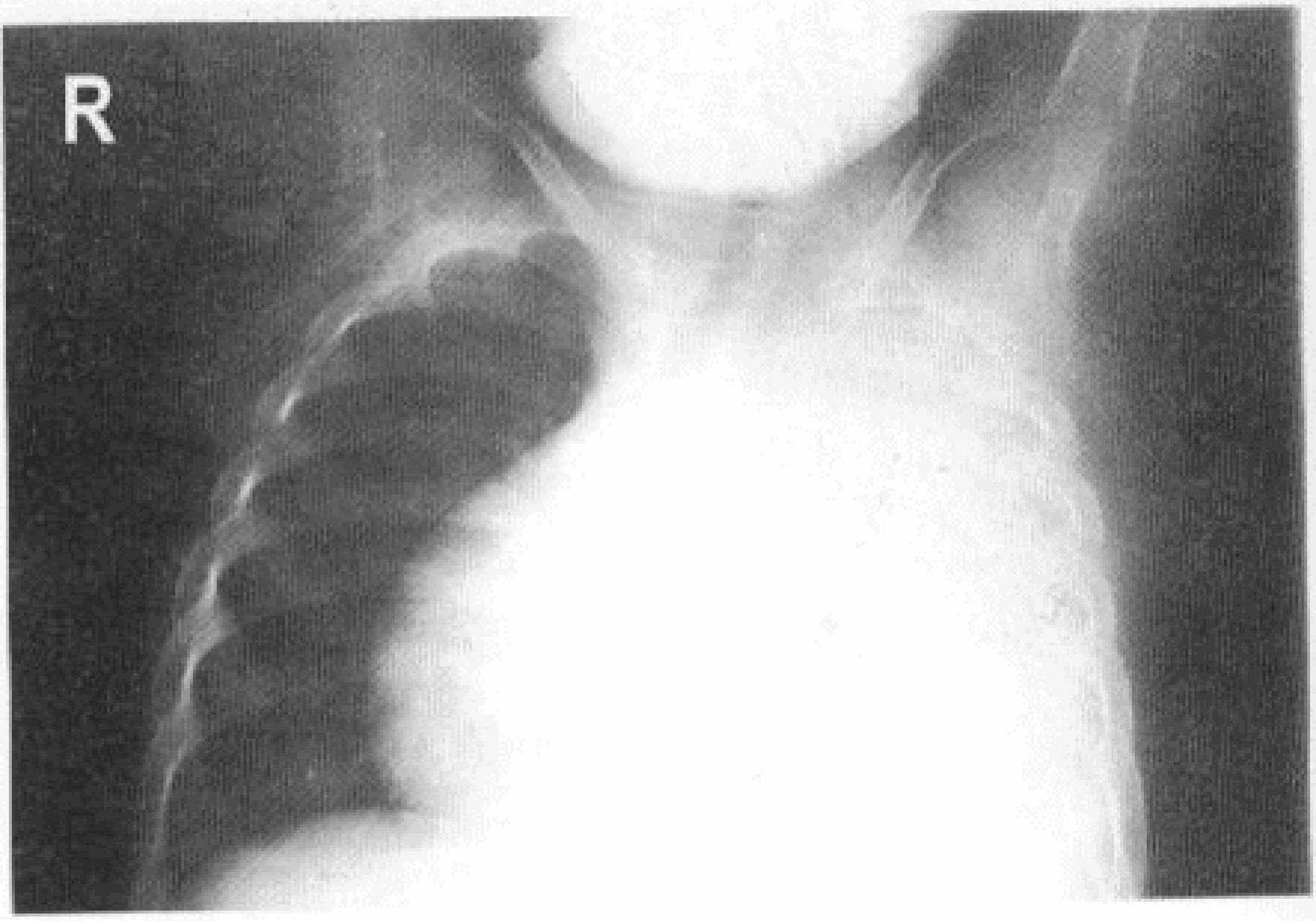

- Plain X ray chest and heart
- Postero-anterior view
- The patient is centralized
- The right costophrenic angle is free
- The left costophrenic is obliterated by homogenous opacity occupying all the left hemithorax
- The mediastinum is shifted to the opposite side of the lesion

<u>Left side massive pleural effusion</u>

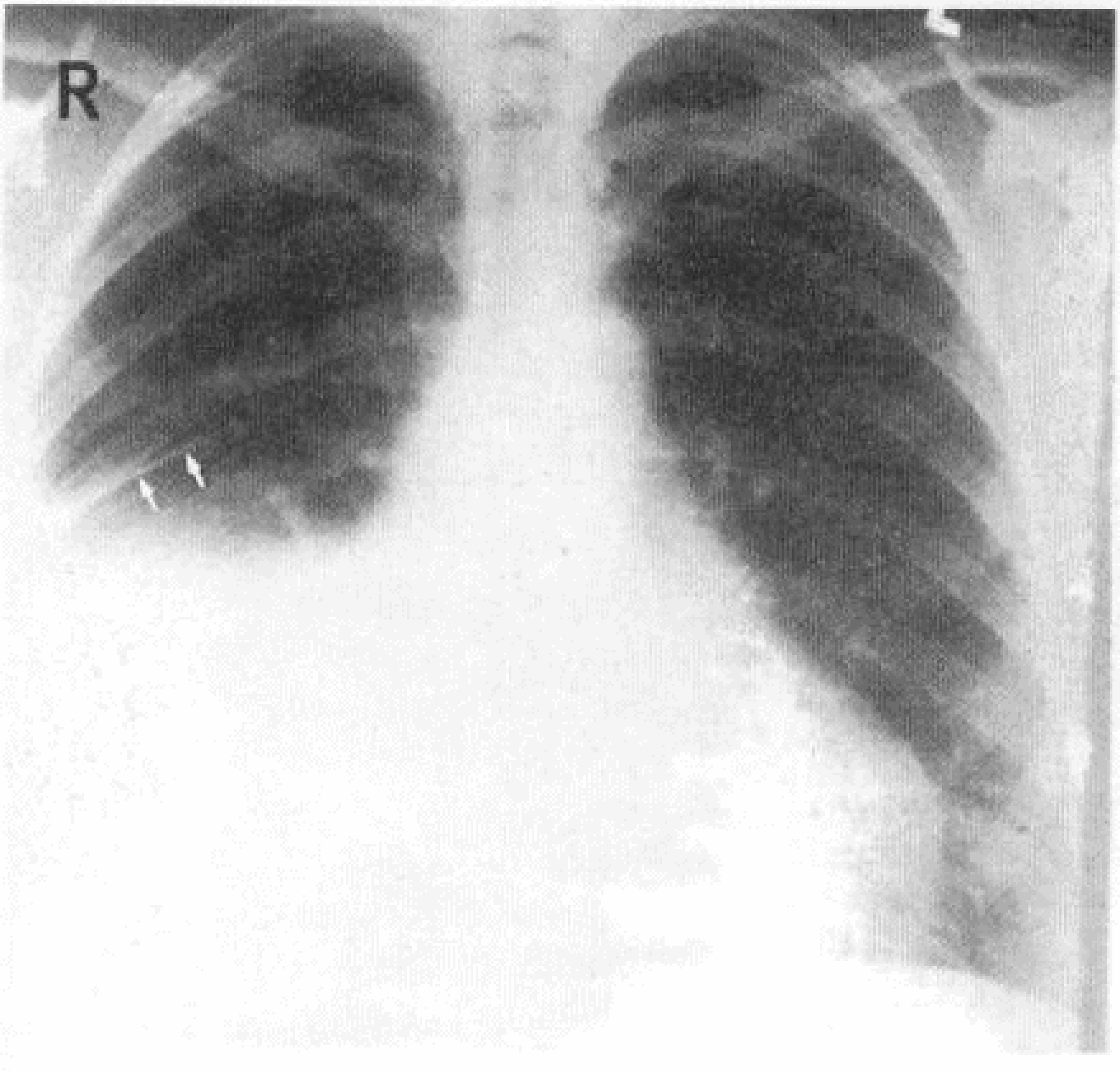

- Plain X ray chest and heart
- Postero-anterior view
- The patient is centralized
- Costophrenic angle on the left side is free.
- Costophrenic angle on the right side is obliterated by homogenous opacity with concave upper border (raising to the axilla)
- The mediastinum is shifted to the opposite side of the lesion

<u>Right side moderate pleural effusion</u>

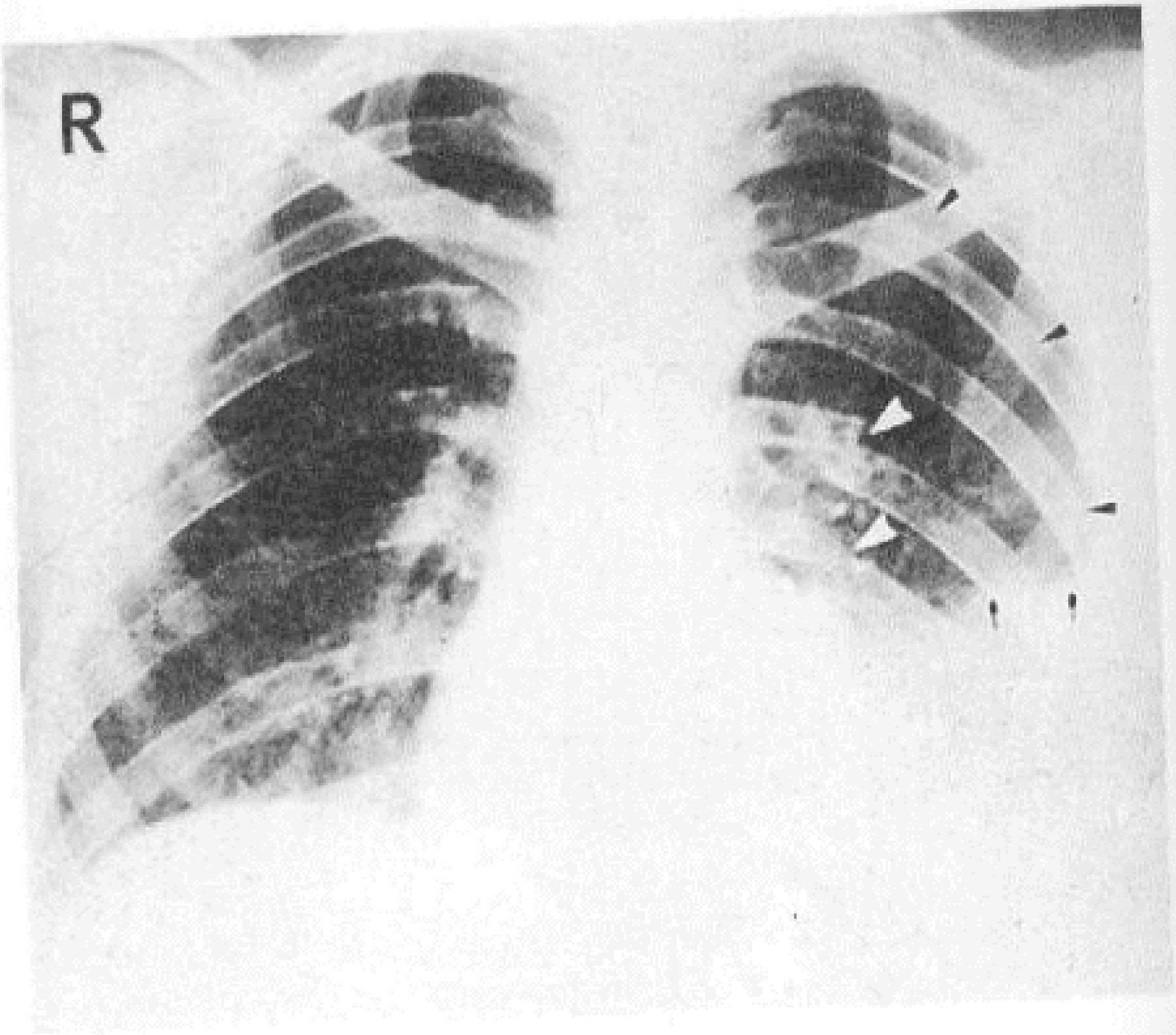

- Plain X ray chest and heart
- Postero-anterior view
- The patient is not centralized
- Costophrenic angle on the right side is free
- Costophrenic angle on the left side is obliterated by homogenous opacity with concave upper border raising to the axilla
- The mediastinum is shifted to the opposite side of the lesion. There is rib fractures (the arrows) due to chest trauma

Left side moderate pleural effusion (hemothorax)

2- Lobar pneumonia

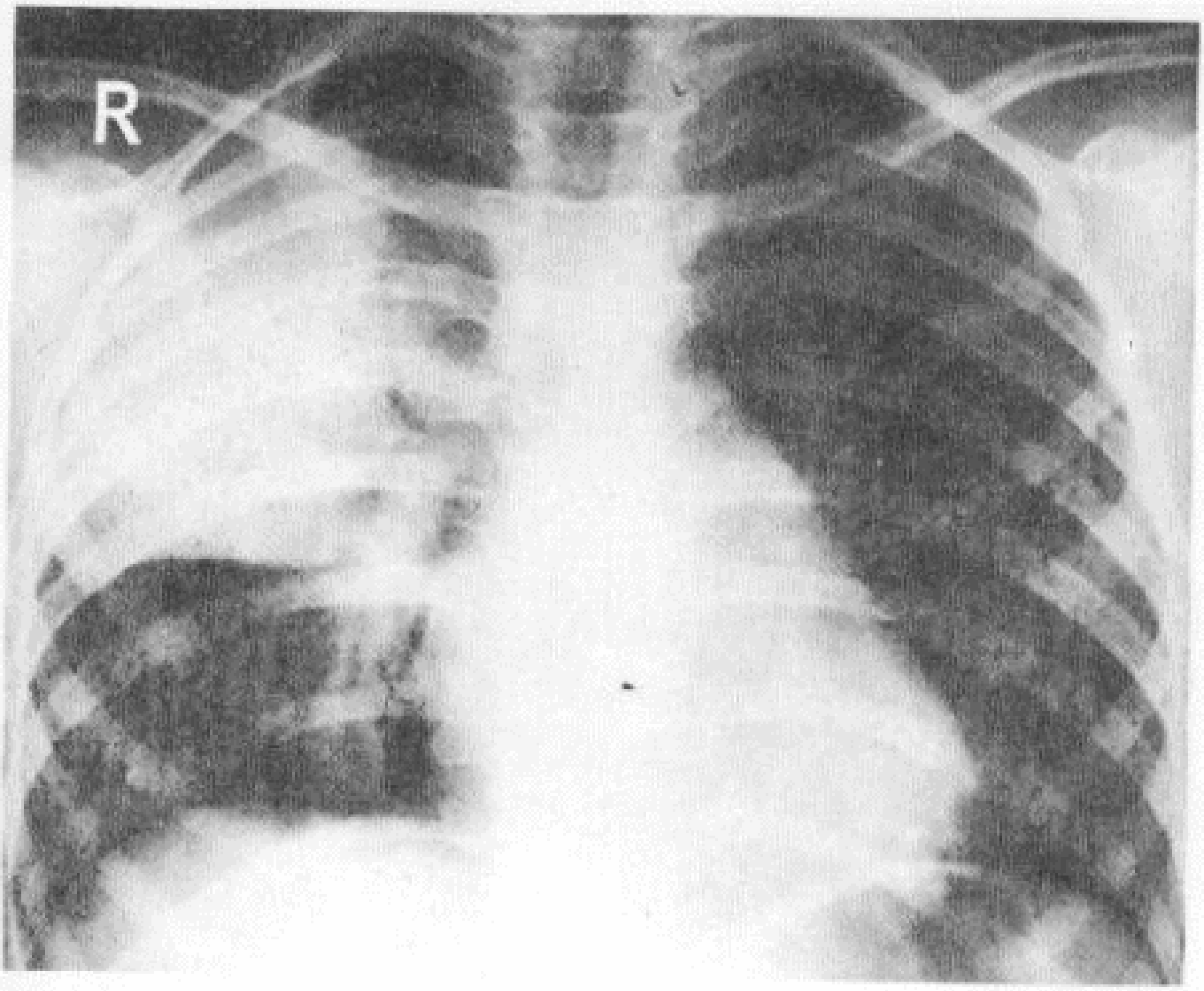

- **Plain X ray chest and heart**
- **Postero-anterior view**
- **The patient is centralized**
- **Costophrenic angles are free on both sides**
- **There is homogenous opacity on the upper and middle zone of the right lung**
- **Central mediastinum**

Right side lobar pneumonia

Causes of lobar pneumonia

- The most important: -pneumococci
- Other organism: - TB-Klebsiella-H.influenza

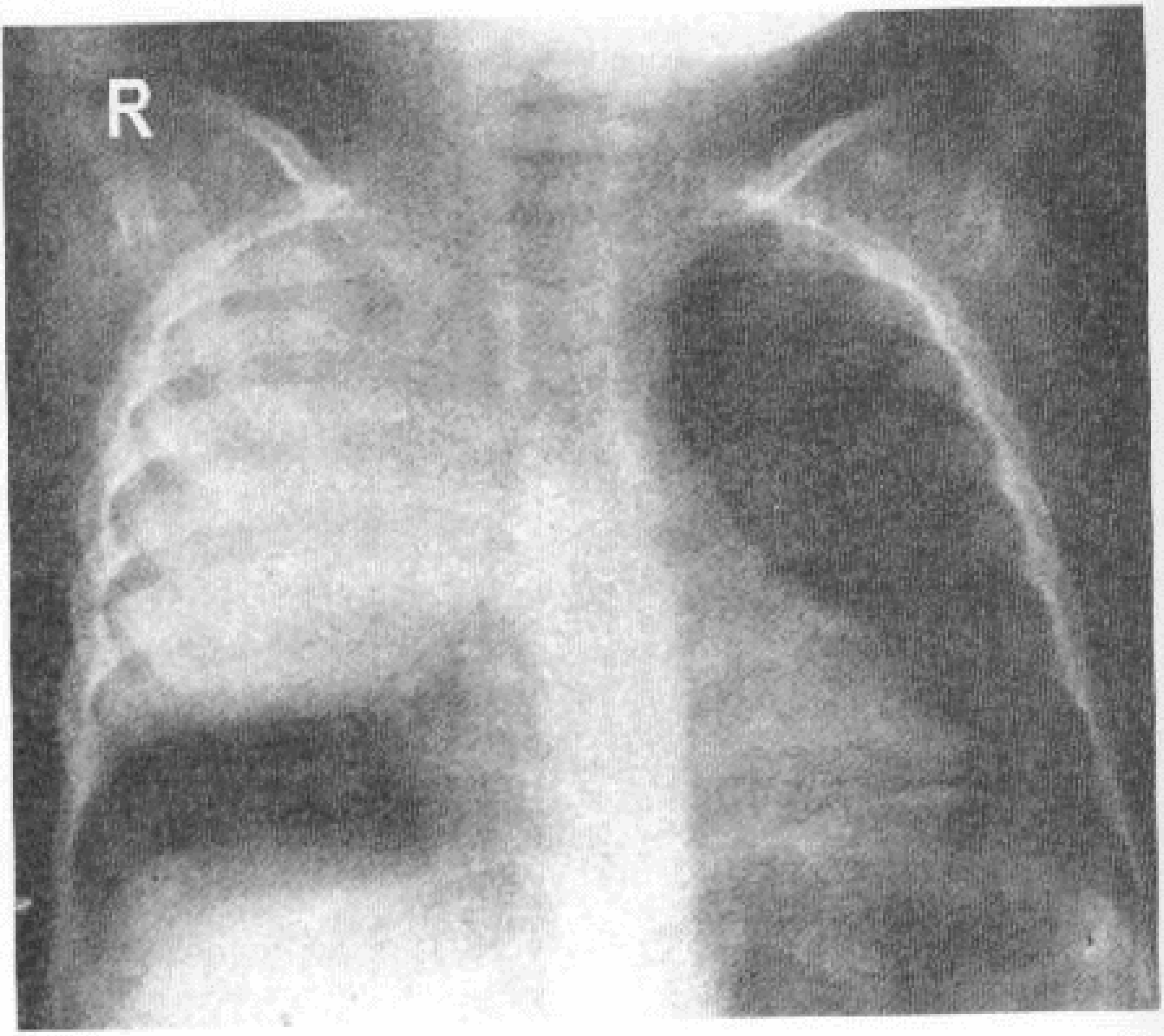

- Plain X ray chest and heart
- Postero-anterior view
- The patient is centralized
- Costophrenic angles are free on both sides
- There is homogenous opacity on the upper and middle zone of the right lung
- Central mediastinum

<u>Right side lobar pneumonia</u>

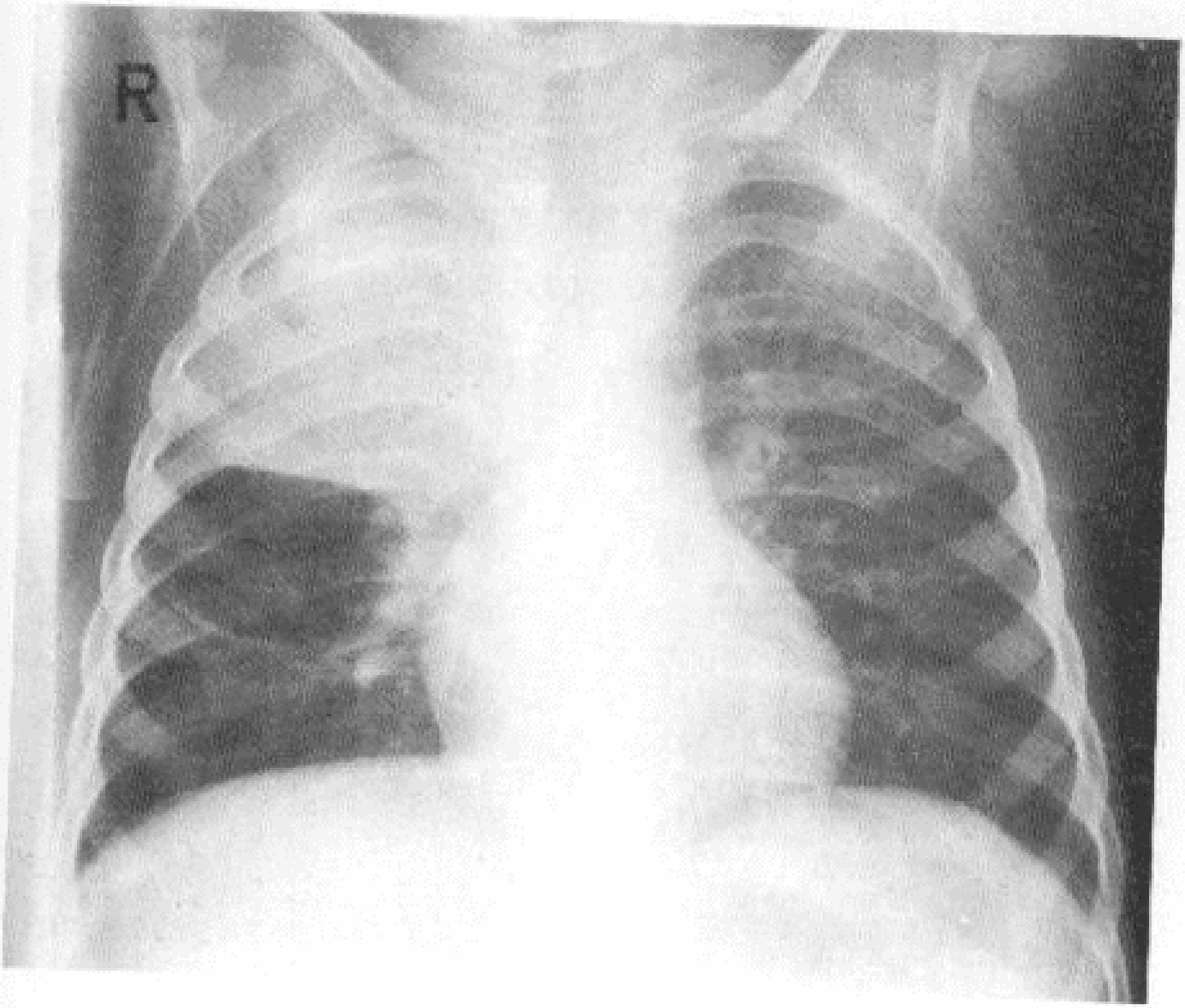

- Plain X ray chest and heart
- Postero-anterior view
- The patient is not centralized
- Costophrenic angles are free on both sides
- There is homogenous opacity on the upper and middle zone of the right lung
- Central mediastinum

Right side lobar pneumonia

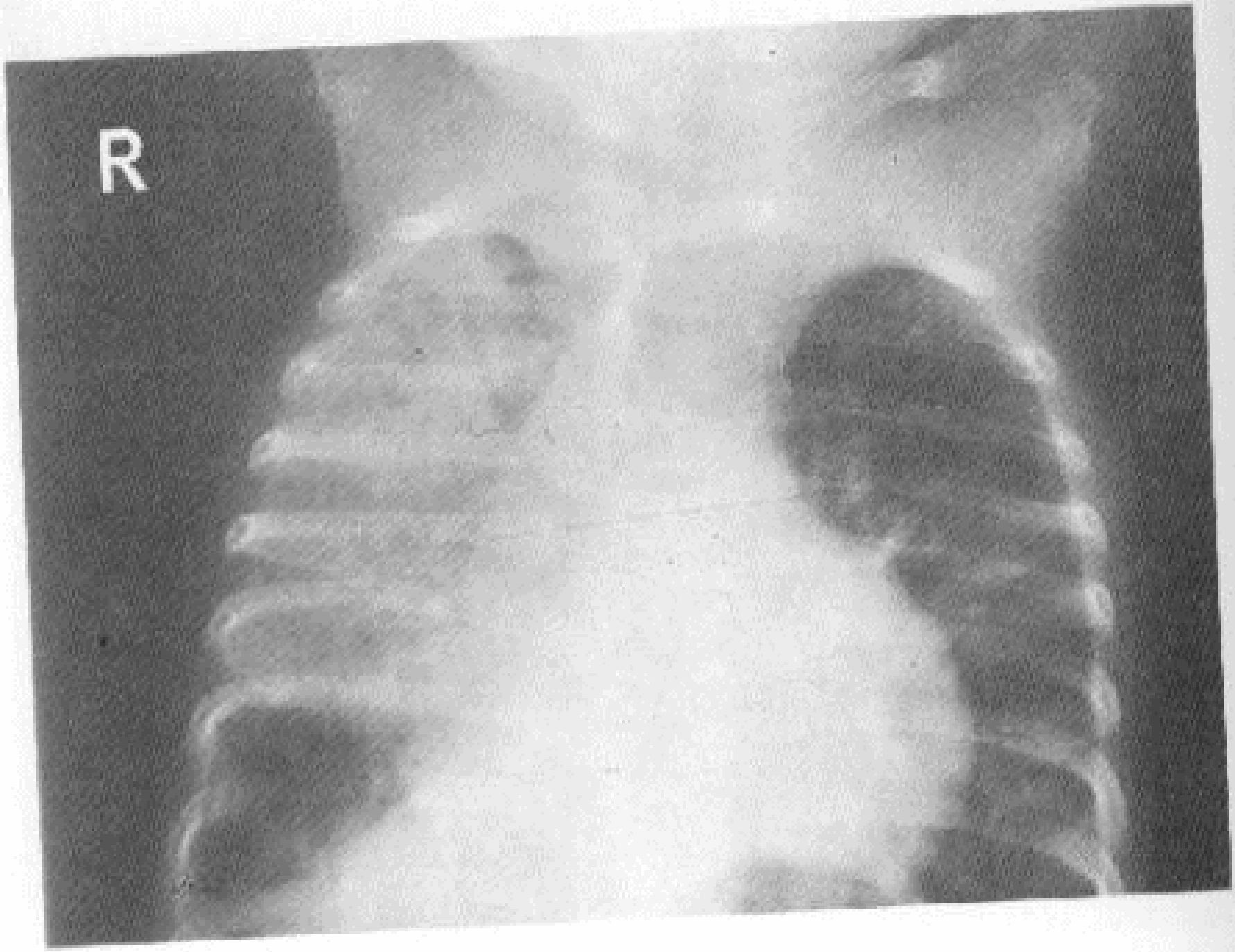

- Plain X ray chest and heart
- Postero-anterior view
- The patient is not centralized
- Costophrenic angles are free on both sides
- There is heterognous opacity on the upper and middle zone of th
  right lung
- Central mediastinum

<u>Right side lobar pneumonia (on resolution)</u>

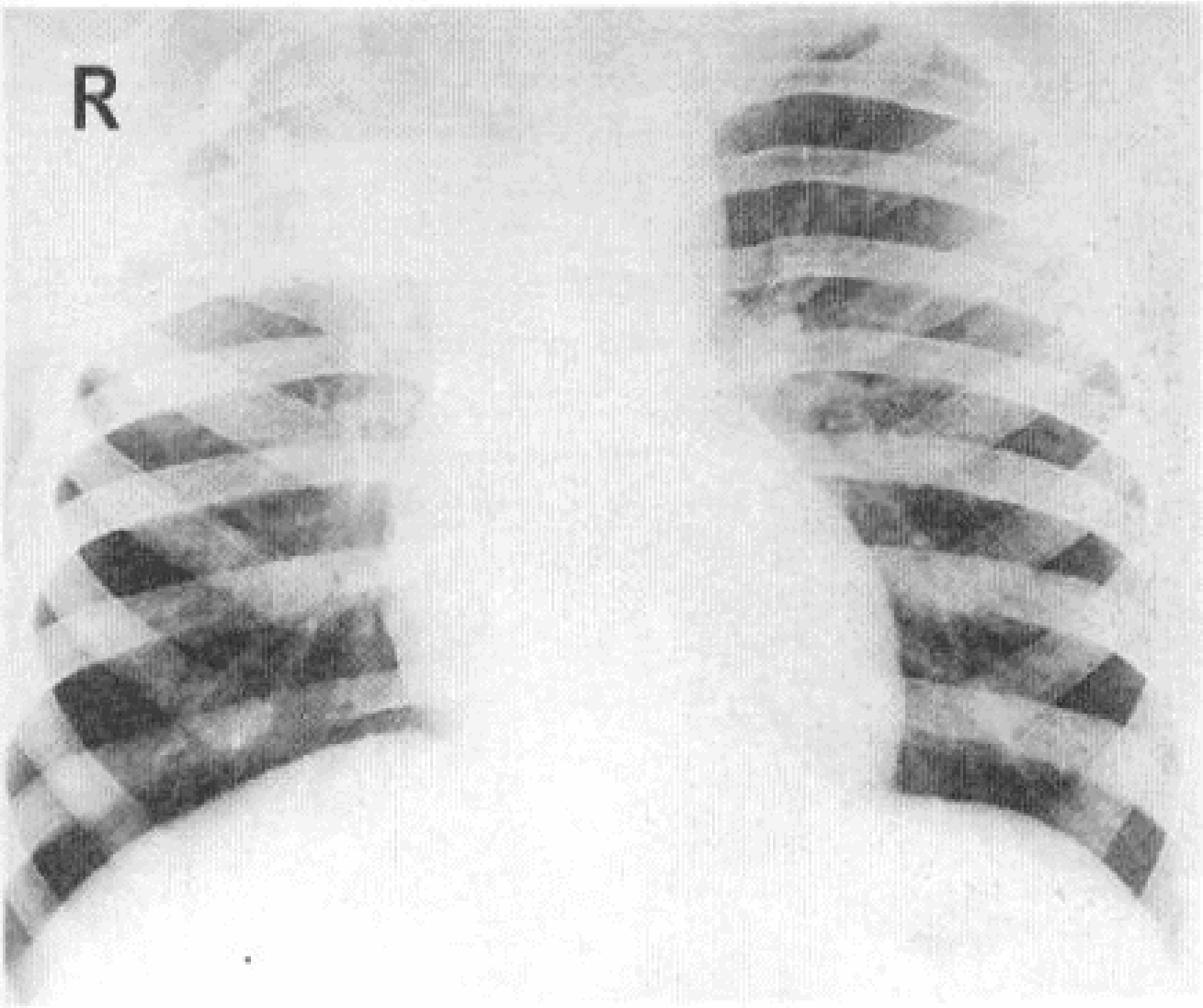

- Plain X ray chest and heart
- Postero-anterior view
- The patient is centralized
- Costophrenic angles are free on both sides
- There is homogenous opacity on the upper zone of the right lung
- Central mediastinum

<u>Right side lobar pneumonia affecting the upper lobe</u>

3- Lung fibrosis

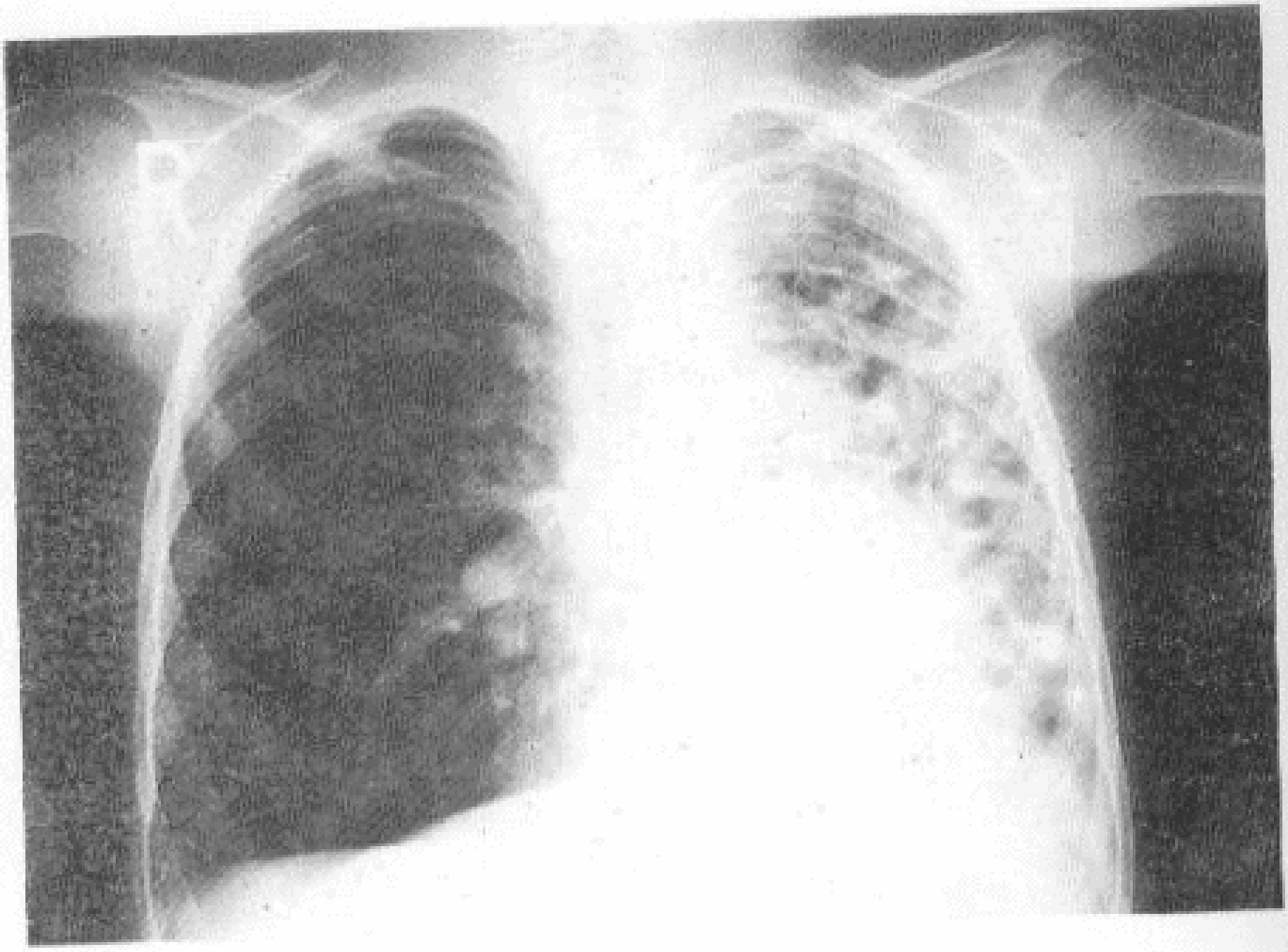

- Plain X ray chest and heart
- Postero-anterior view
- The patient is centralized
- There is heterogeneous opacity occupying most of the left lung
- The mediastinum is shifted to the same side of the lesion

Left side massive fibrosis

Causes of lung fibrosis
- Tuberculosis
- Emyema (improperly drained)
- Bronchiectasis

4- Lung collapse

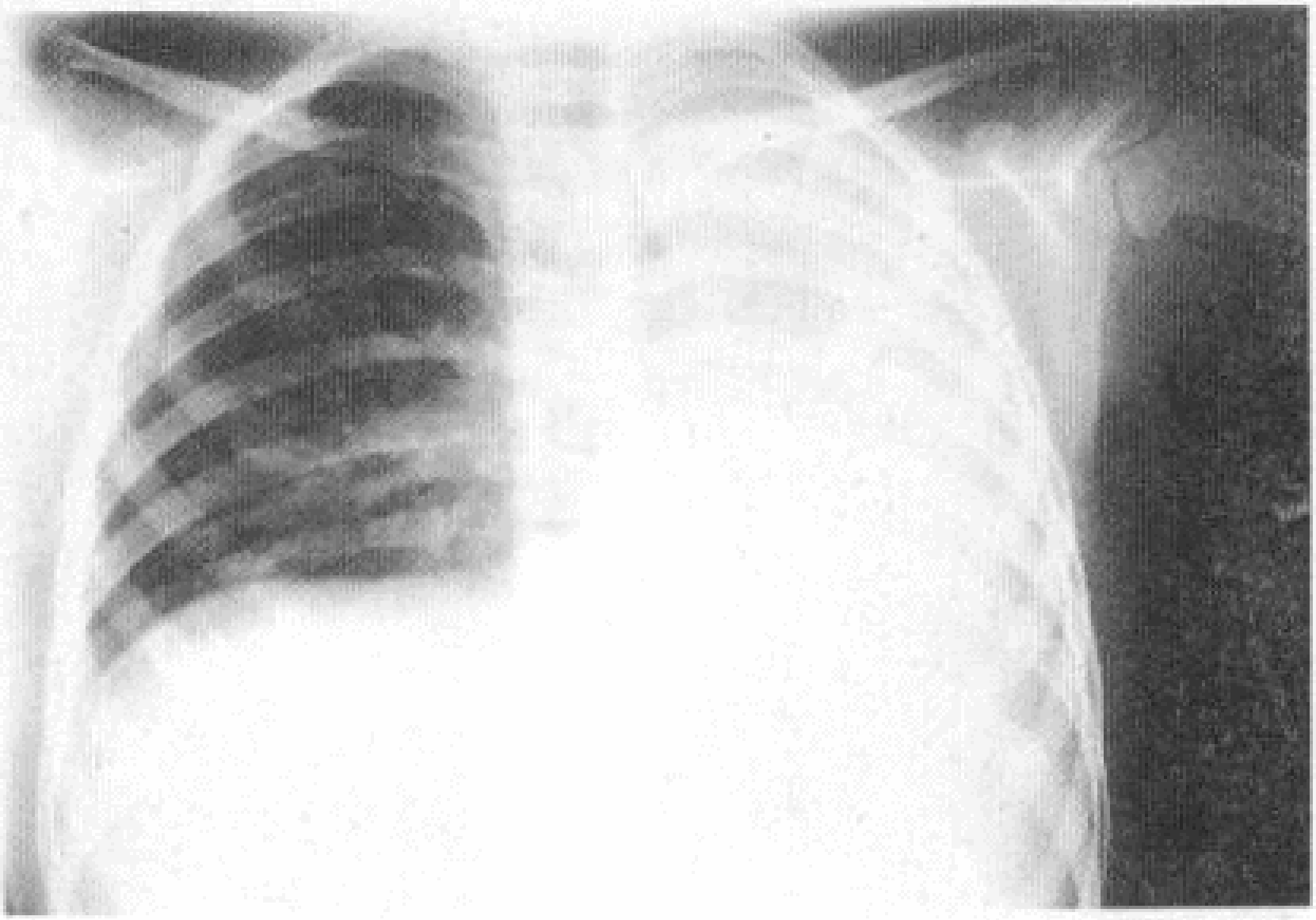

- Plain X ray chest and heart
- Postero-anterior view
- The patient is centralized
- Costophrenic angles are free on both sides
- There is homogenous opacity occupying all the left hemithorax
- The mediastinum is shifted to the same side of the lesion

Left side massive collapse

Causes of lung collapse

- Intrabronchial obstruction :- foreign body- mucous plug- granuloma (TB) Treated by bronchoscopic removal
- External compression: Enlarged lymph nodes- tumor

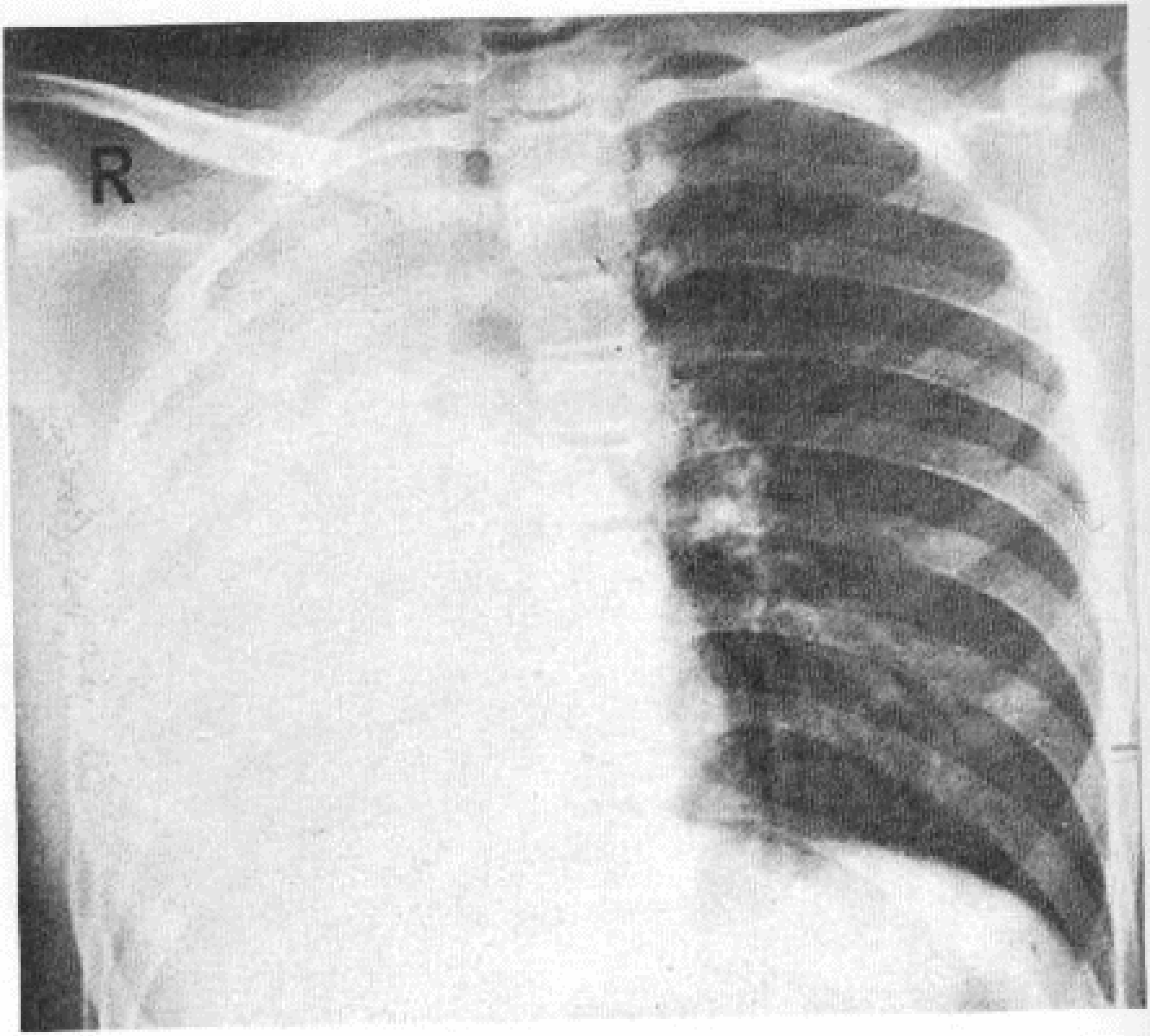

- Plain X ray chest and heart
- Postero-anterior view
- The patient is centralized
- Costophrenic angles are free on both sides
- There is homogenous opacity occupying all the right hemithorax
- The mediastinum is shifted to the same side of the lesion

Right side massive collapse

Lobar collpase

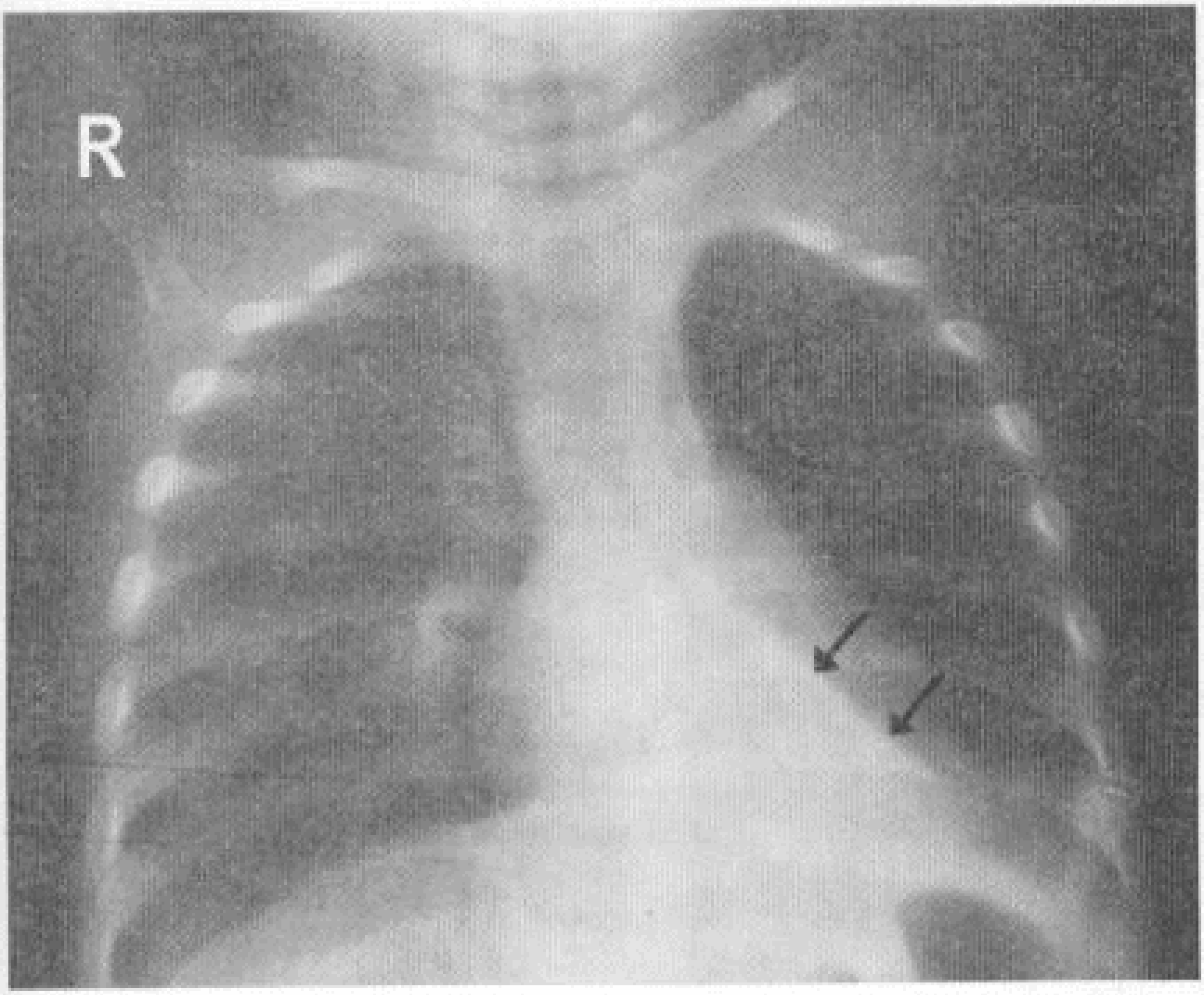

- Plain X ray chest and heart
- Postero-anterior view
- The patient is not centralized
- Costophrenic angles are free on both sides
- There is homogenous opacity on the left side (the arrows)
  Triangular in shape with
  Sharp upper border,
  Rretrocardic in position (behind the cardiac shadow)
- The upper lobe of the left lung is more translucent (compensatory emphysema)

Left lower lobe collapse

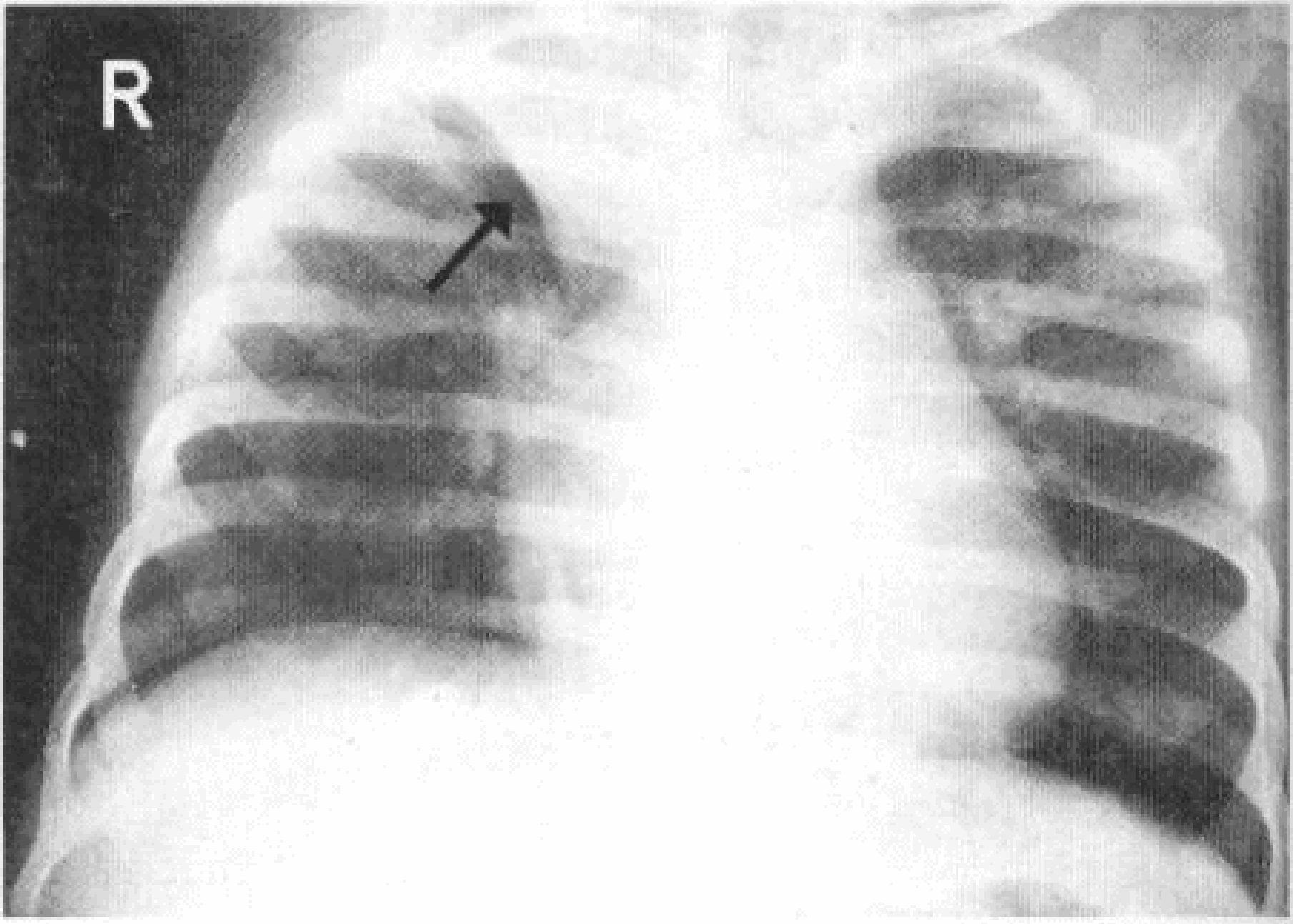

- Plain X ray chest and heart
- Postero-anterior view
- The patient is not centralized
- Costophrenic angles are free on both sides
- There is homogenous opacity on the right side (the arrows)
  Triangular in shape with
  <u>Concave sharp lower border,</u>

<u>**Right upper lobe collapse**</u>

1- Miliary shadows

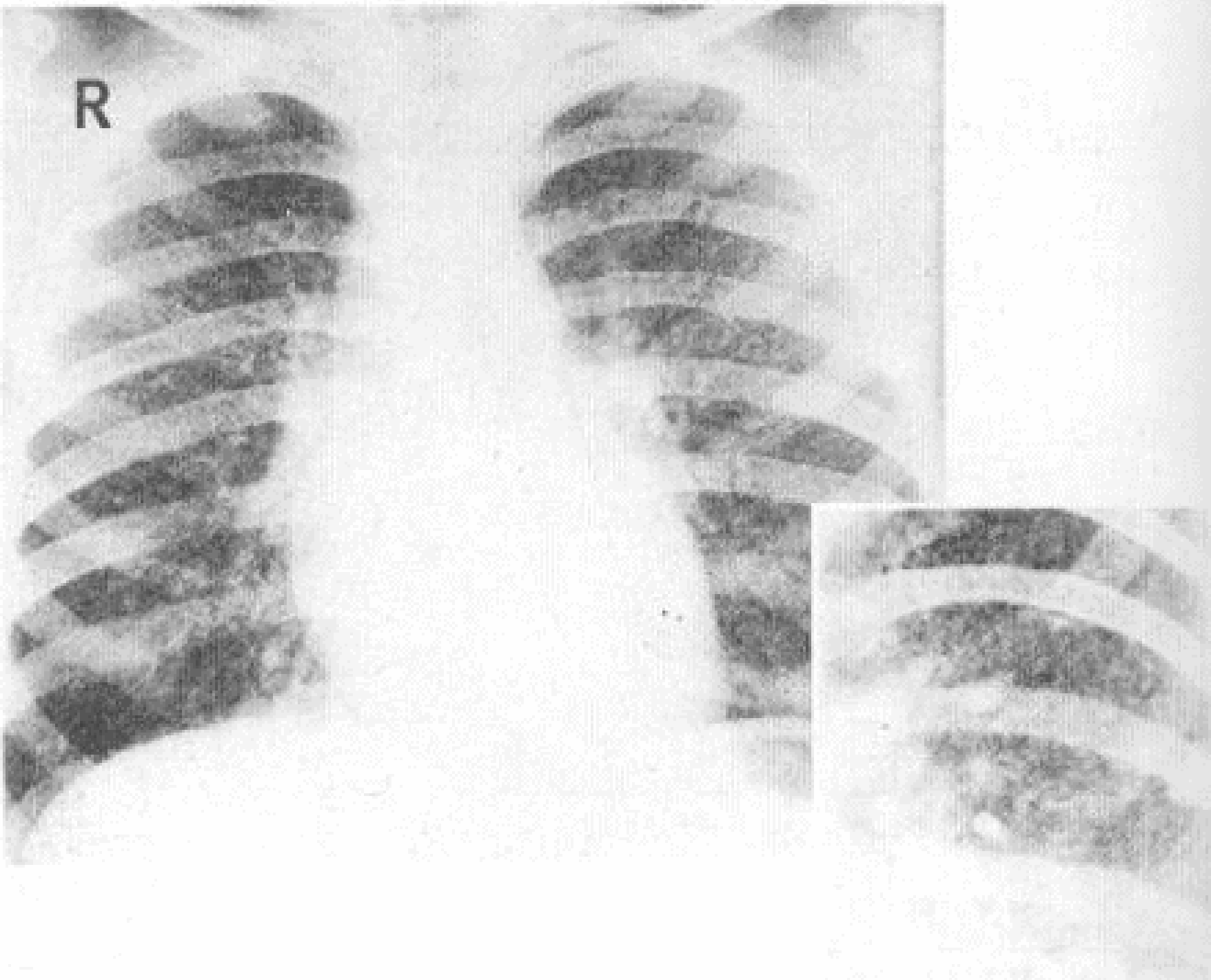

- **Plain X ray chest and heart**
- **Postero-anterior view**
- **The patient is centralized**
- **Costophrenic angles are free on both sides**
- **There are multiple small lesions with well defined outline distributed on both lung fields**
- **Central mediastinum**

Miliary shadows for differential diagnosis

Causes

- Tuberculosis
- Toxoplasmosis
- Histocytosis
- Hemosidrosis
- Viral pneumonia

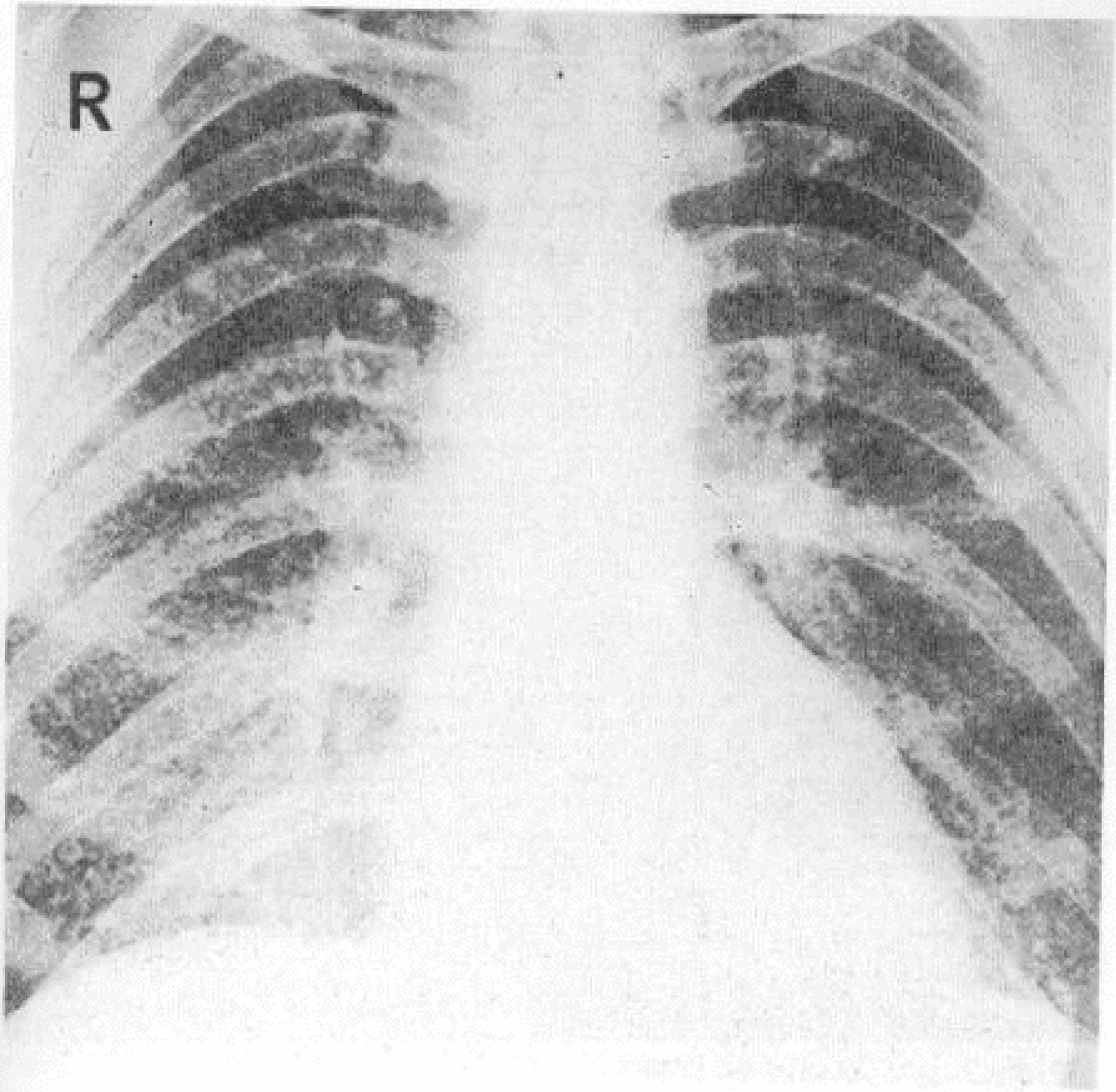

- Plain X ray chest and heart
- Postero-anterior view
- The patient is centralized
- Costophrenic angles are free on both sides

- There are multiple small lesions with well defined outline distributed on both lung fields
- Central mediastinum

<u>Miliary shadows for differential diagnosis</u>

2- Bronchopneumonia

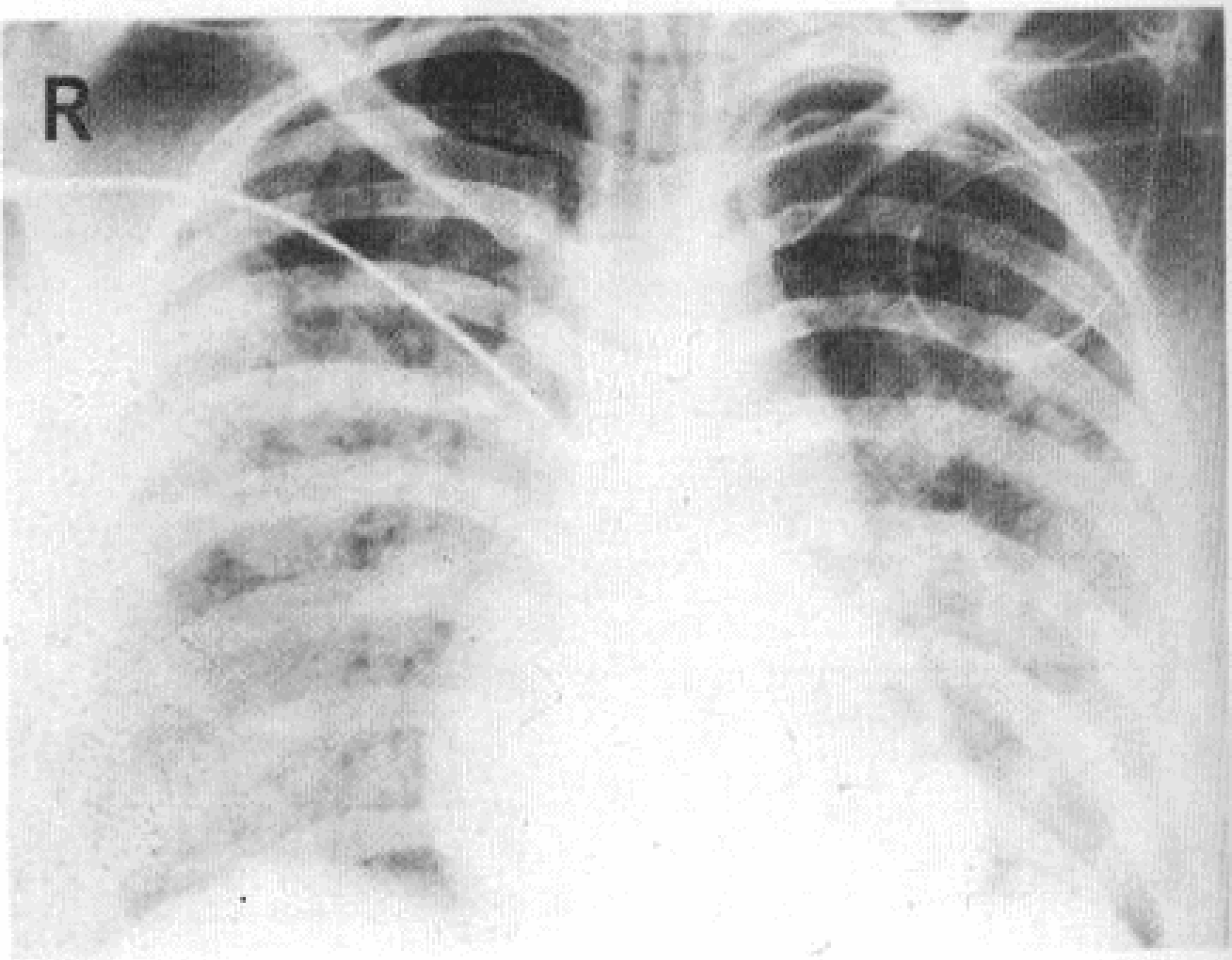

- Plain X ray chest and heart
- Postero-anterior view
- The patient is centralized
- Costophrenic angles are free on both sides
- There are multiple patches with ill-defined outline distributed on both lung fields
- Central mediastinum

Causes of bronchopneumonia

. Streptococci
. Klebsiella
. Hemophilus Influenza
. Staphylococci
. T.B

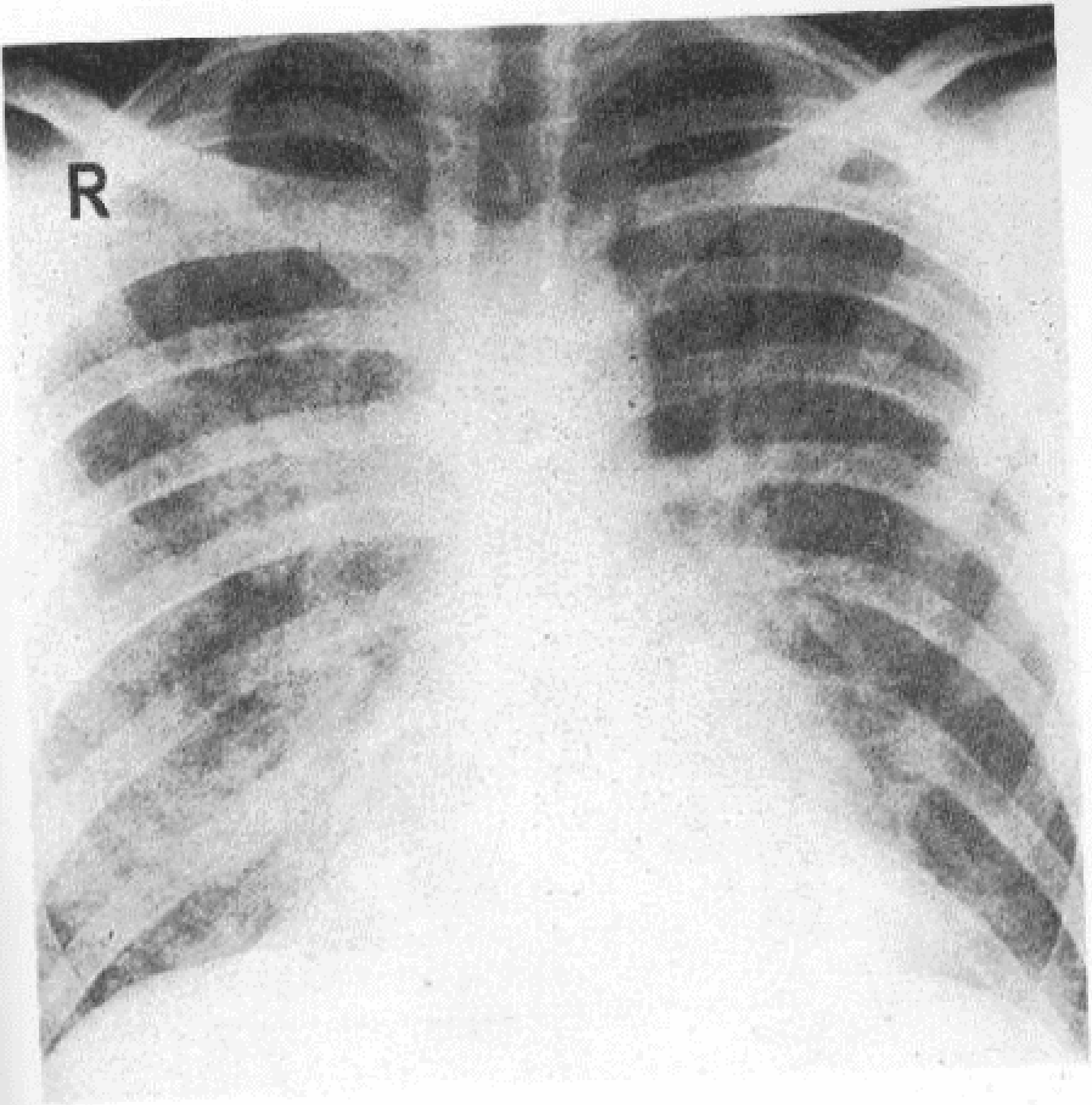

- Plain X ray chest and heart
- Postero-anterior view
- The patient is centralized
- Costophrenic angles are free on both sides
- There are multiple patches with ill-defined outline distributed on both lung fields (more marked on the right lung)
- Central mediastinum

<u>Bronchopneumonia</u>

3- Bronchiectasis

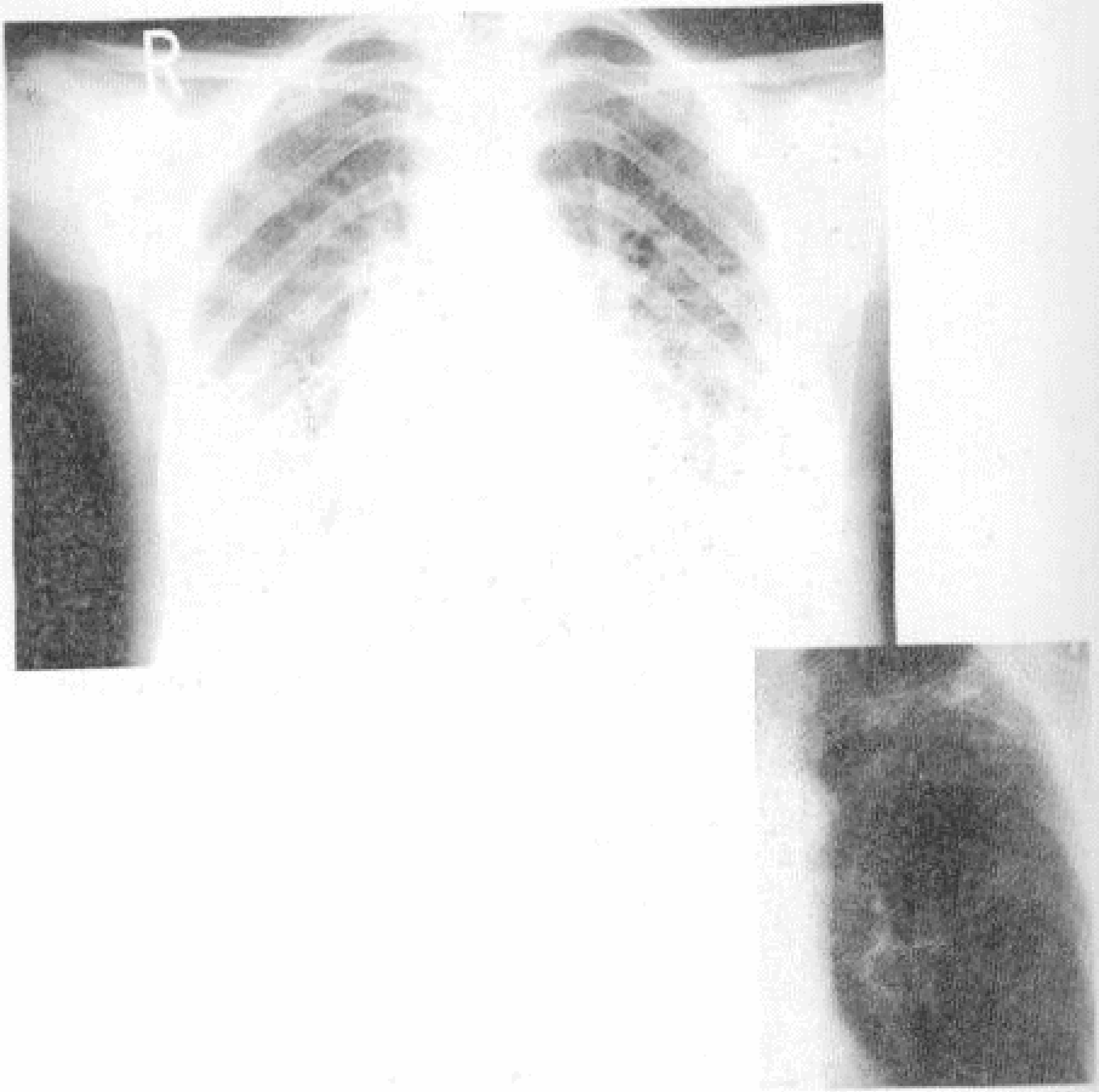

- Plain X ray chest and heart
- Postero-anterior view
- The patient is centralized
- Costophrenic angles are free on both sides
- The upper lung zone is free on both sides
- The middle and lower lung zone show bilateral lesions having honey comb appearance

1- Lung abscess

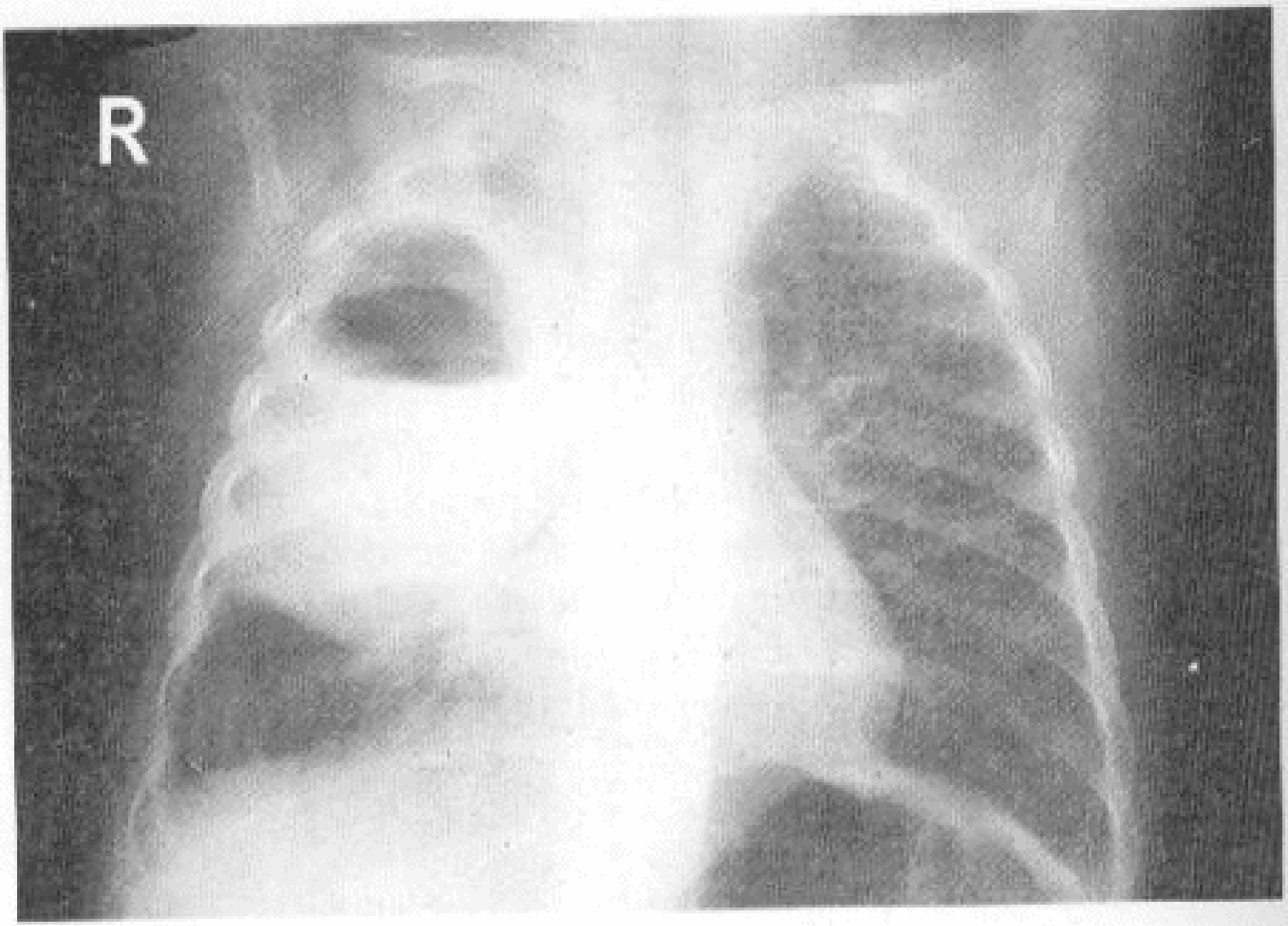

- Plain X ray chest and heart
- Postero-anterior view
- The patient is centralized
- Costophrenic angles are free on both sides
- The upper and middle zone of the right lung show a lesion with well-defined outline (abscess wall). The lower part of the lesion is homogenous with transverse upper border (fluid) while the upper part of the lesion is jet black (air).
- The mediastnum is central

Right side lung abscess

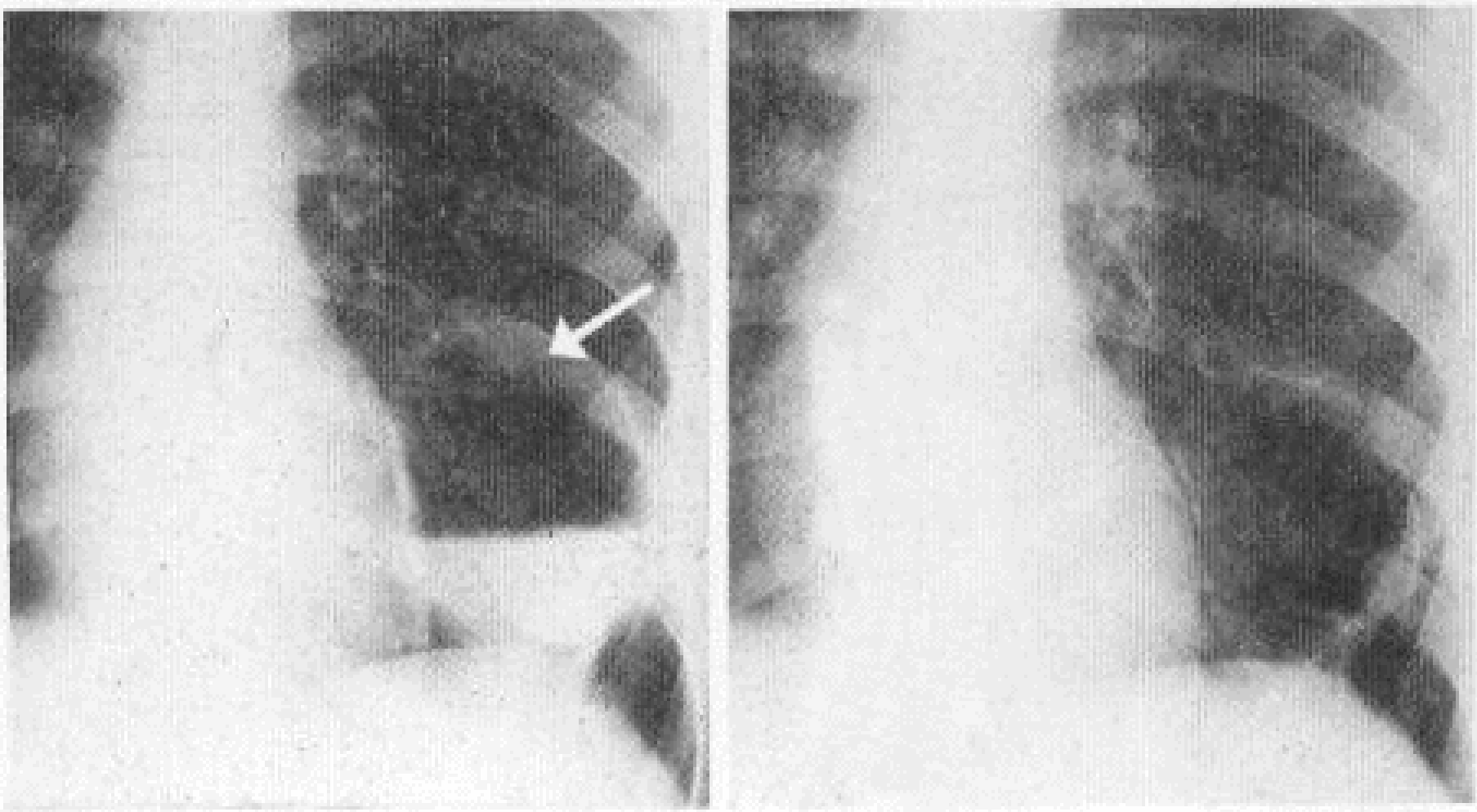

- Plain X ray chest and heart
- Postero-anterior view
- The patient is centralized
- Costophrenic angles are free on both sides
- The lower zone of the left lung shows a lesion with well-defined outline (abscess wall). The lower part of the lesion is homogenous with transverse upper border (fluid) while the upper part of the lesion is jet black (air).
- The mediastinum is central
- The other X- ray shows the effect of antibiotic treatment where the lung field starts to clear

<u>Left side lung abscess</u>

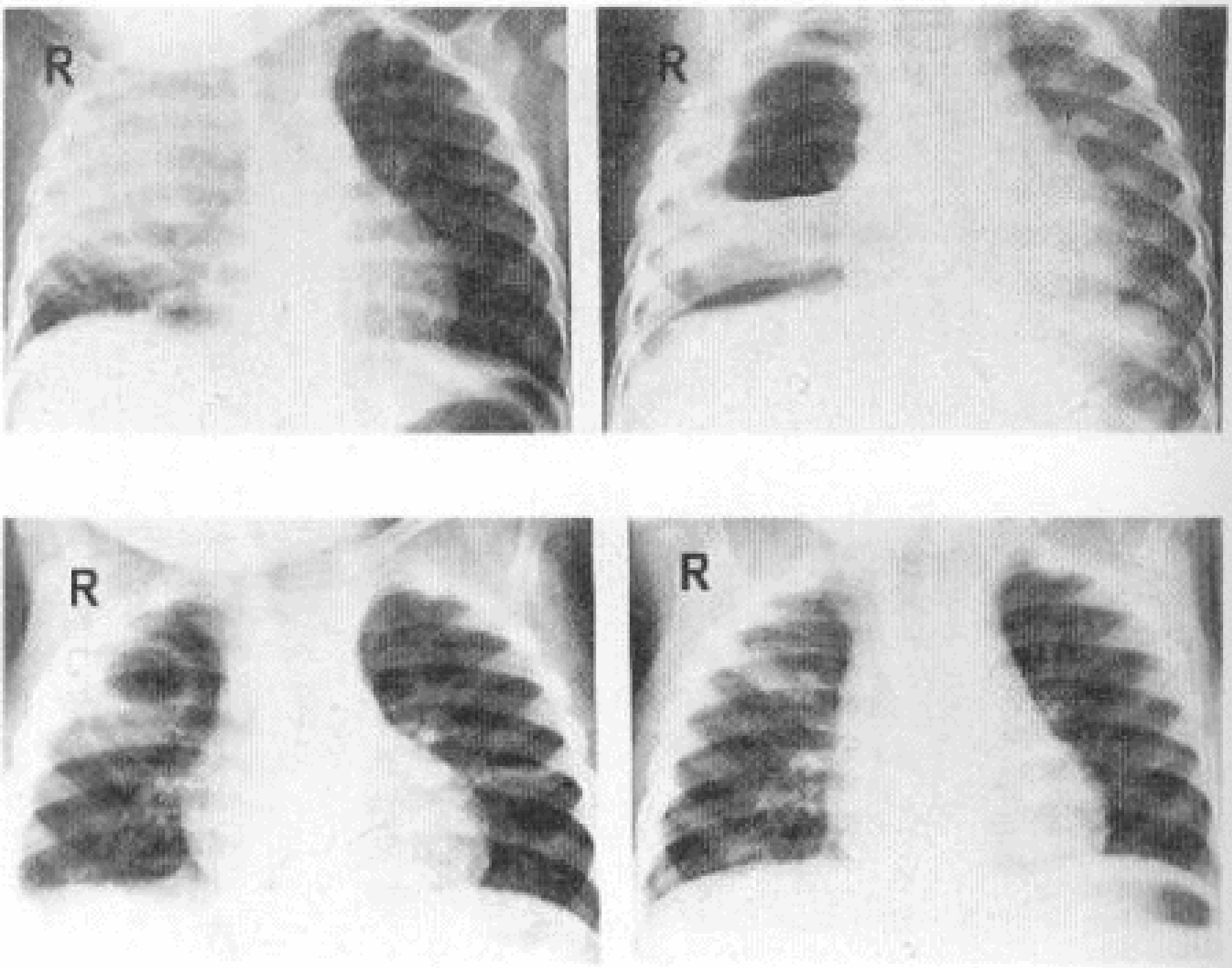

1- The right lung shows homogenous opacity occupying the upper and middle lung zones (pneumonia)
2- One week later ,there is breakdown within the consolidated area with abscess formation (air fluid level)
3- Two weeks after treatment where there is decrease on the size of the abscess
4- Another 2 weeks of treatment ,where the lung field became more or less clear

<u>Lung abscess most probably due to staphylococcal pneumonia</u>

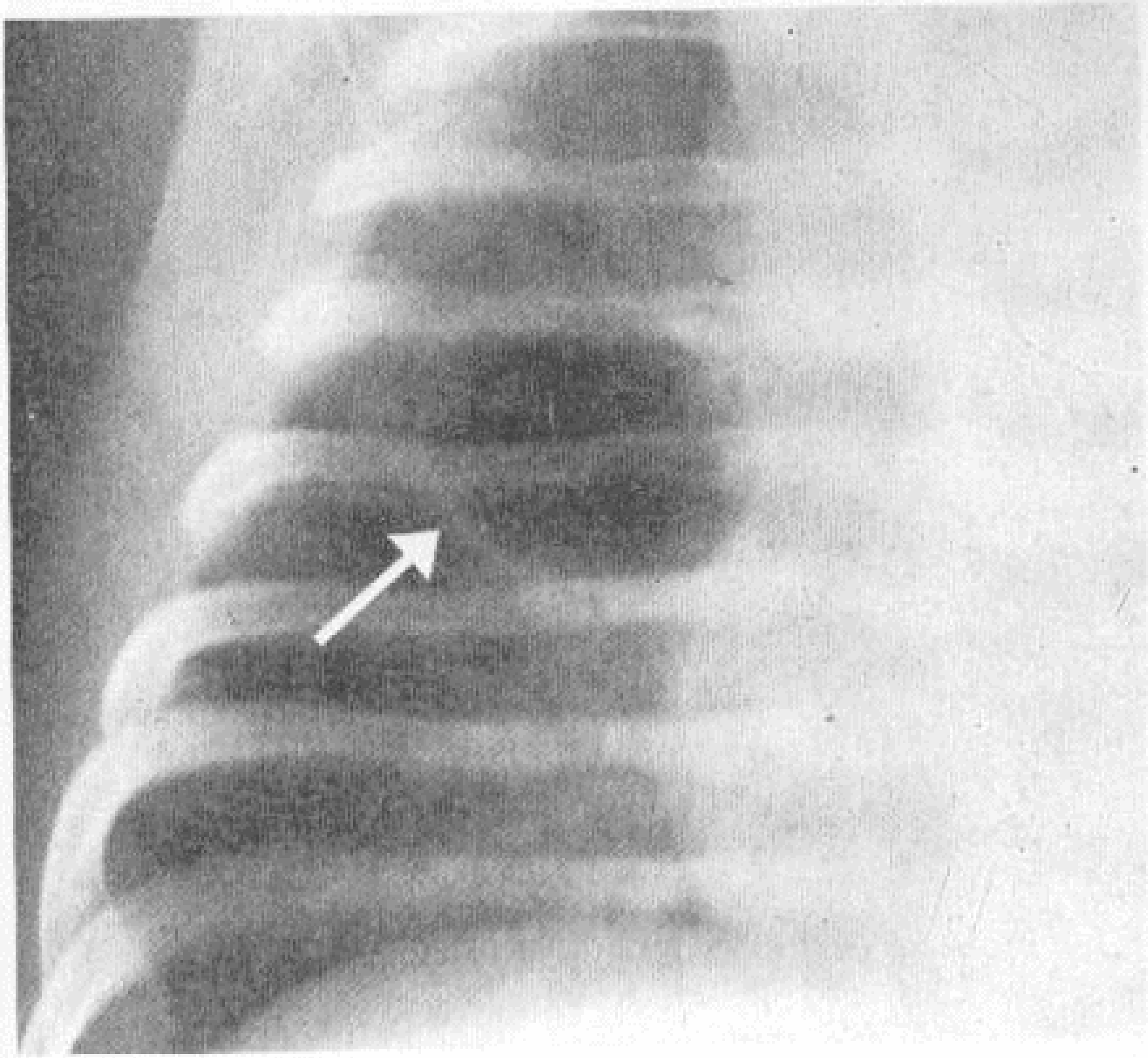

- Plain X ray chest and heart
- Postero-anterior view
- The patient is centralized
- Costophrenic angle on the left side is free
- The middle lung zone shows a pneumatocele (airspace surrounded by thin wall)

<u>The cause is most probably staphylococcal pneumonia</u>

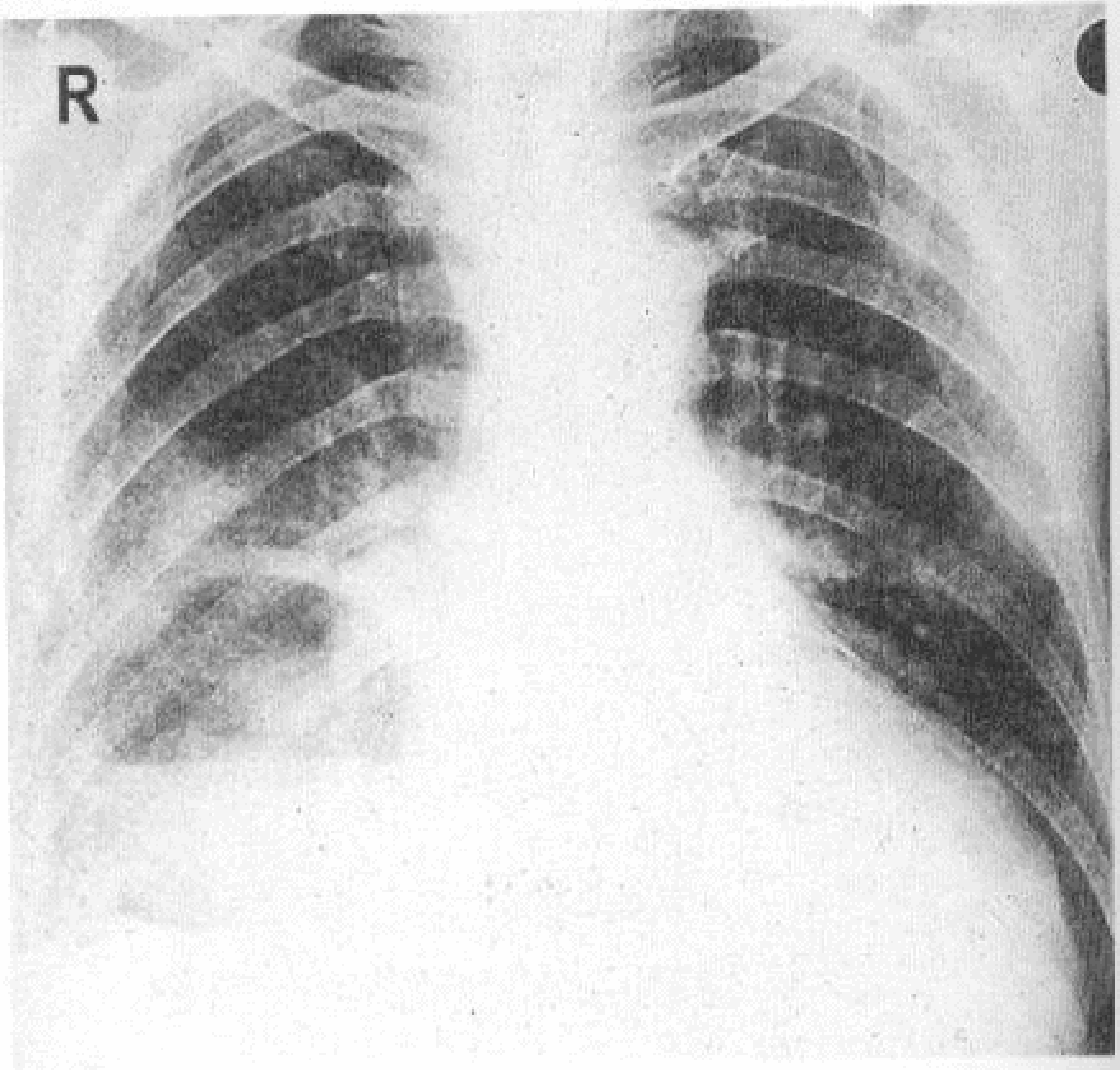

- Plain X ray chest and heart
- Postero-anterior view
- The patient is centralized
- Costophrenic angle on the right side is obliterated
- The lower zone of the right lung shows a lesion with well-defined outline (abscess wall). The lower part of the lesion is homogenous with transverse upper border (fluid) while the upper part of the lesion is jet black (air).
- The mediastinum is central

<u>Right side lung abscess</u>

2- Pyopneumothorax

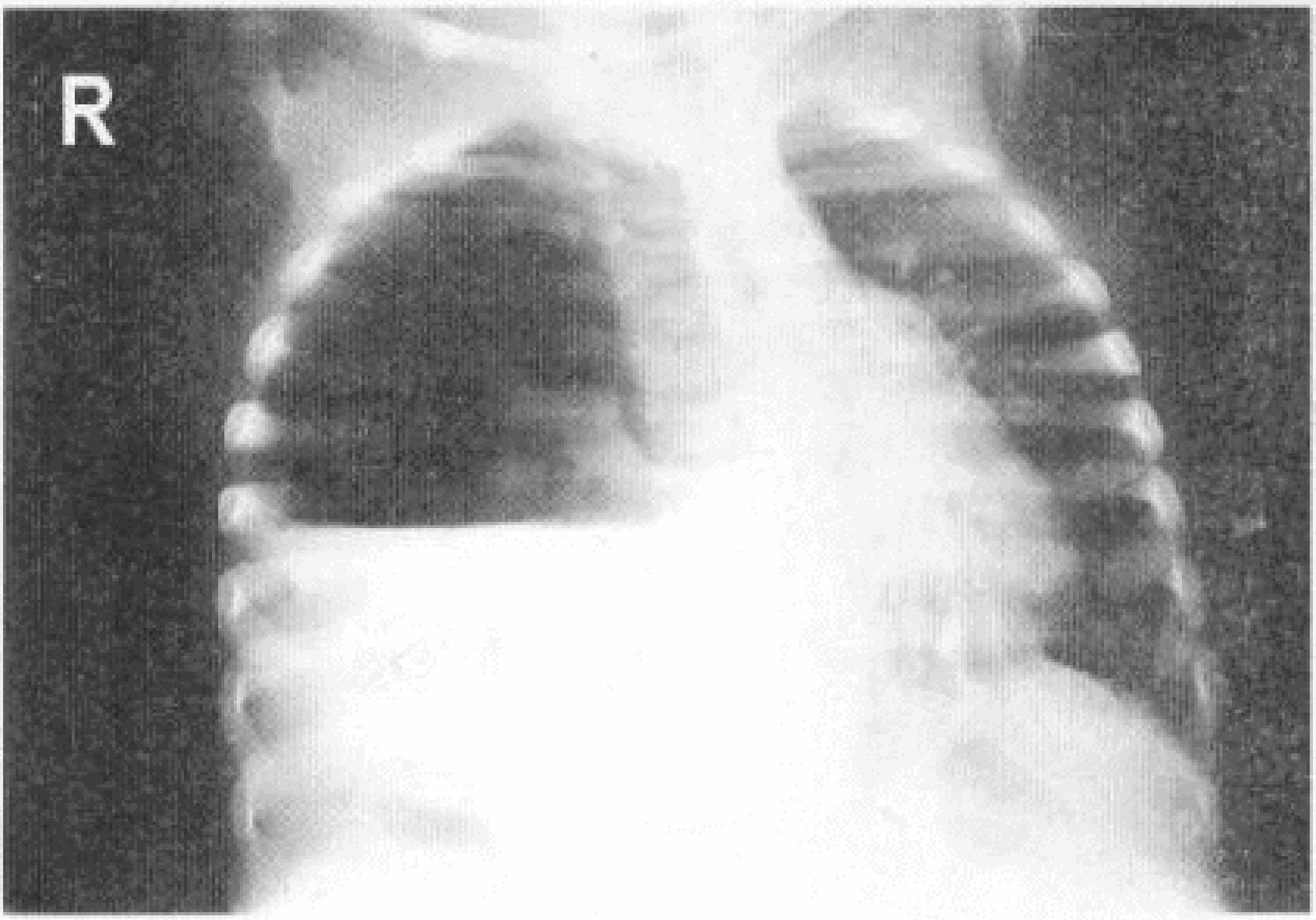

- Plain X ray chest and heart
- Postero-anterior view
- The patient is not centralized
- Costophrenic angle on the left side is free while on the right side is obliterated by homogenous opacity with transverse upper border (fluid). The remaining part of the right hemithorax is jet black (air)
- The mediastinum is shifted to the opposite side the lesion

Right side pyopneumothorx(or hydropneumothorax)

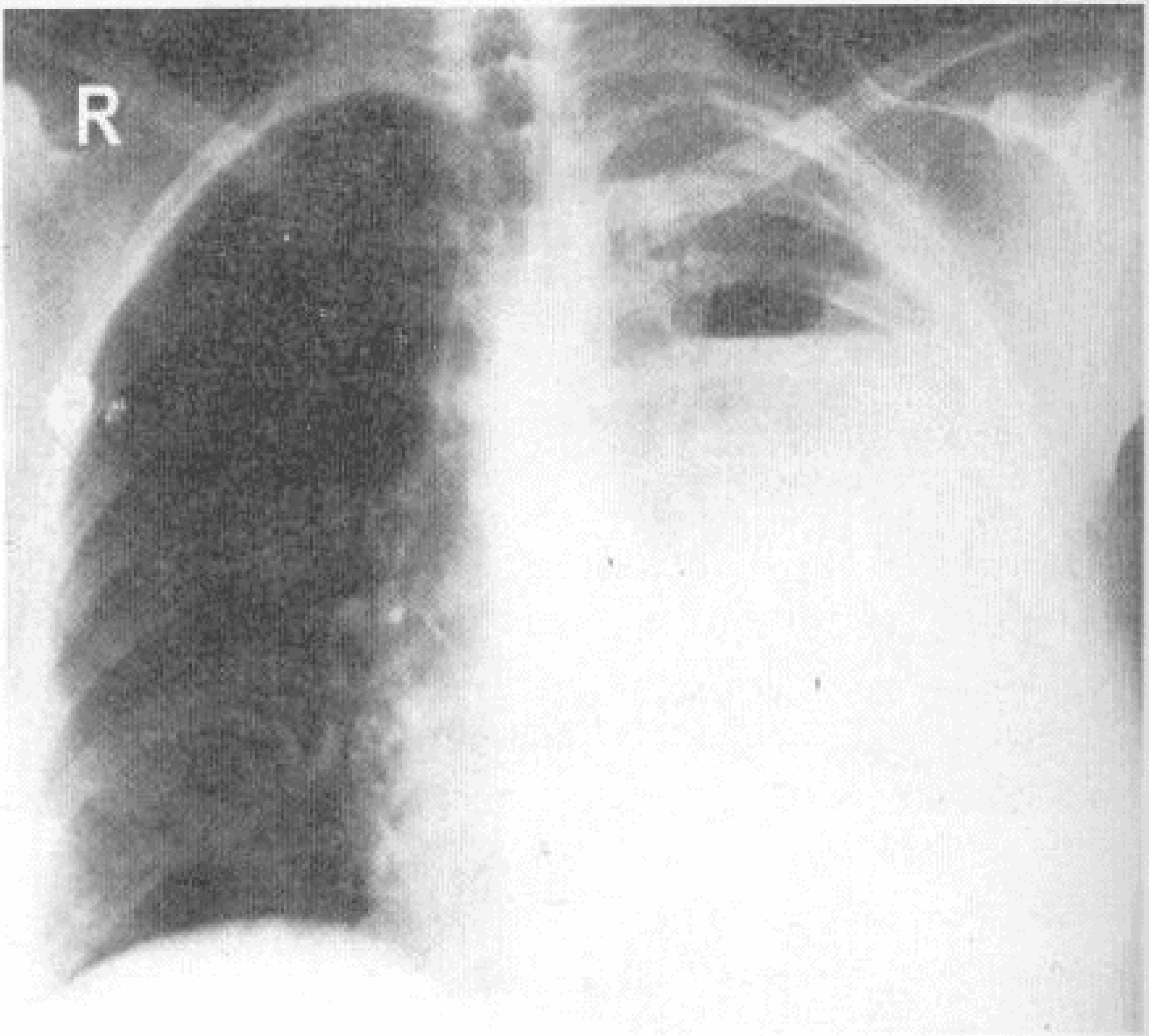

- Plain X ray chest and heart
- Postero-anterior view
- The patient is centralized
- Costophrenic angle on the right side is free while on the left side is obliterated by homogenous opacity with transverse upper border (fluid). The remaining part of the left hemithorax is jet black (air)
- The mediastinum is shifted to the opposite side the lesion

Left side pyopneumothorx (or hydropneumothorax)

1- Pneumothorax

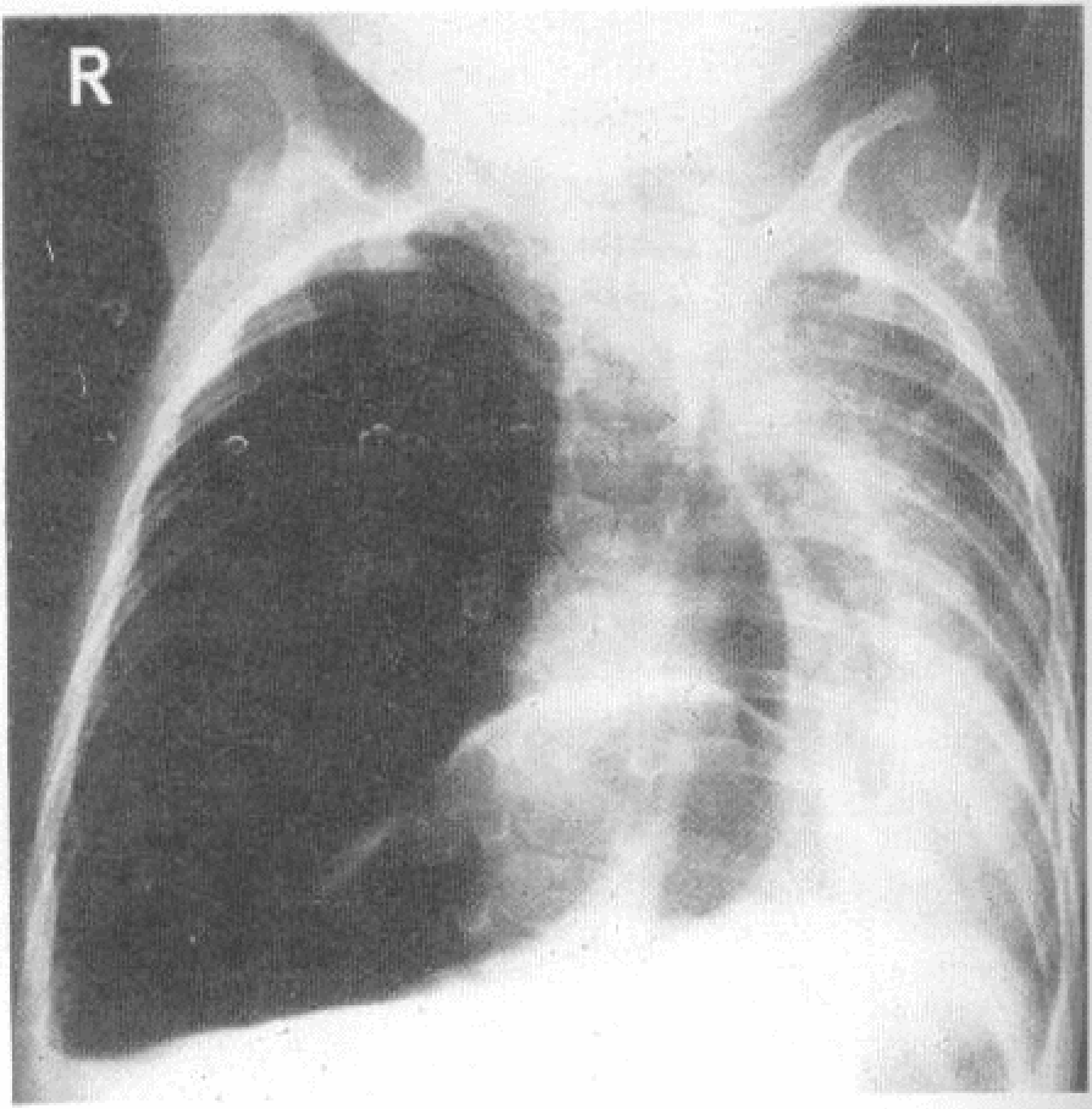

- Plain X ray chest and heart
- Postero-anterior view
- The patient is centralized
- Costophrenic angles are free on both sides
- The right hemithorax is hypertranslucent with absent bronchovascular markings (jet-black) .The right copula of the diaphragm is compressed downwards
- Marked shift of the mediastinum to the opposite side of the lesion

Right side pneumothorax

2- Emphysema

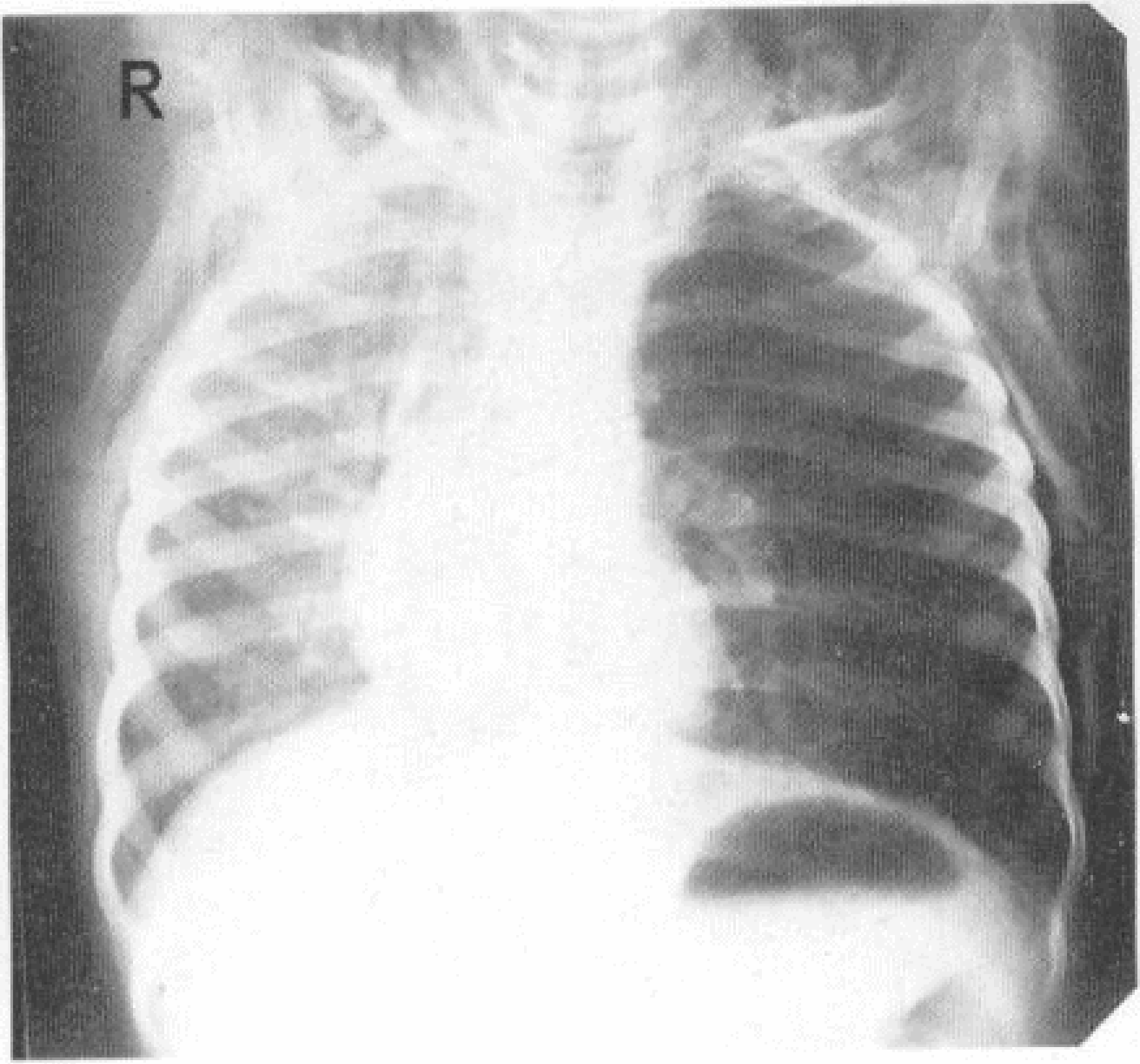

- Plain X ray chest and heart
- Postero-anterior view
- The patient is centralized
- Costophrenic angles are free on both sides
- The left lung is hypertranslucent with intact bronchovascular markings
- Shift of the mediastinum to the opposite side of the lesion

Left side obstructive emphysema

Hilar shadows

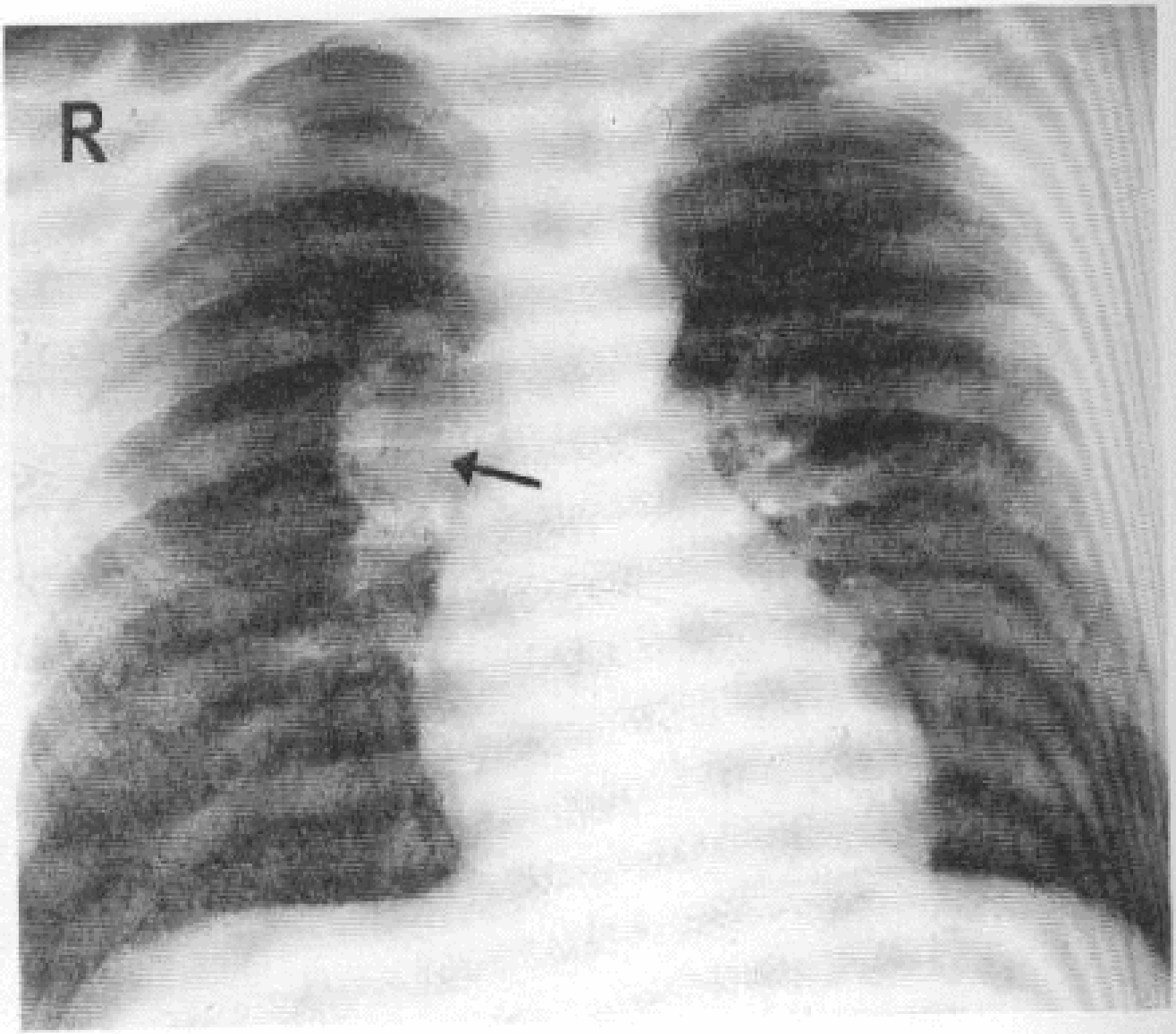

- Plain X ray chest and heart
- Postero-anterior view
- The patient is centralized
- Costophrenic angles are free on both sides
- Bilateral hilar shadow

Hilar lymphadenopathy for differential diagnosis

- TB is the (commonest)
- Lymphoma
- Leukemia

Radiology of long bones

Normal bone

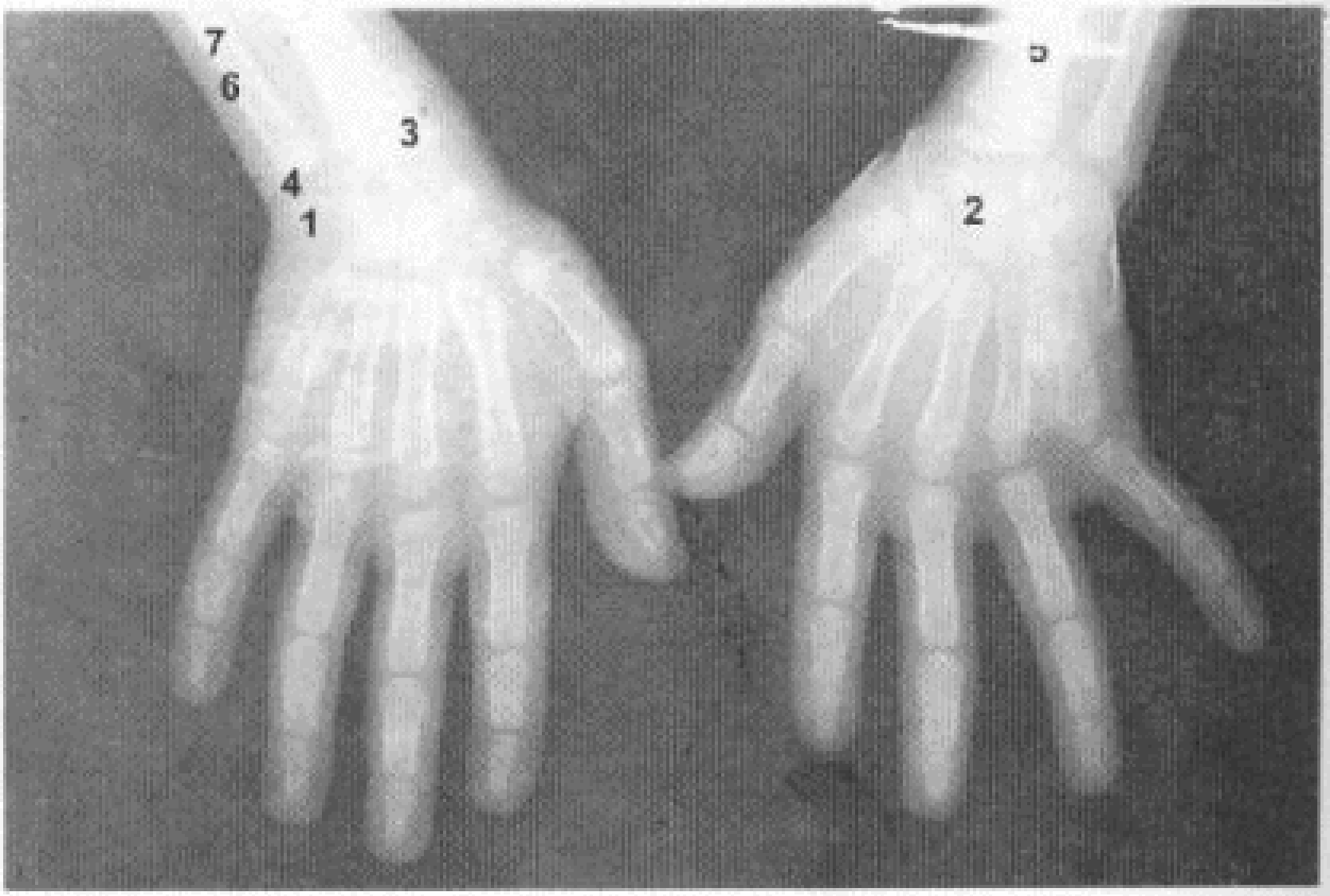

Plain X-ray wrist joints showing

1- Joint space
2- Ossific centers of carpal bones
   Bone age is determined roughly by calculating the number of carpal ossific centers minus one
3- Epiphyseal ossific center (radius)
4- Epiphyseal line(line of provisional calcification)
5- Diaphysis
6- Cortex
7- Medulla

1- C ronic hemolytic anemia

- Plain X ray wrist joint
- Metacarpal bones show: -
  . Loss of waist (rectangular)
  . Thin cortex
  . Wide medulla with mosaic appearance
- Decreased bone density

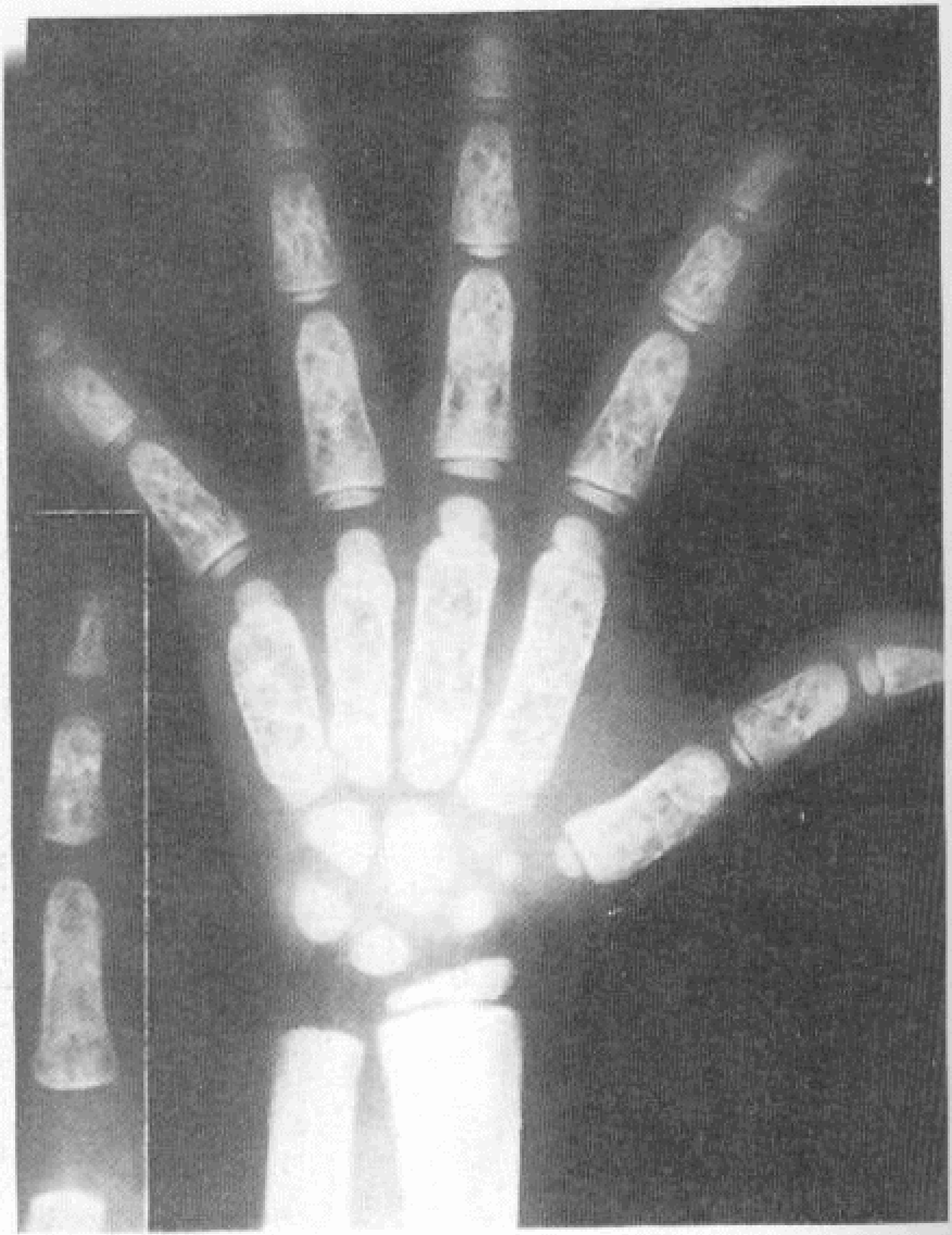

- Plain X ray wrist joint
- Metacarpal bones show: -
  . Loss of waist
  . Thin cortex
  . Wide medulla with mosaic appearance
- Decreased bone density

Chronic hemolytic anemia

2- Rickets

- Plain X ray wrist joint
- Wide joint space
- Cupping of the metaphyseal area with frayed epiphyseal line
- Decreased bone density
- Bone deformity

Active rickets

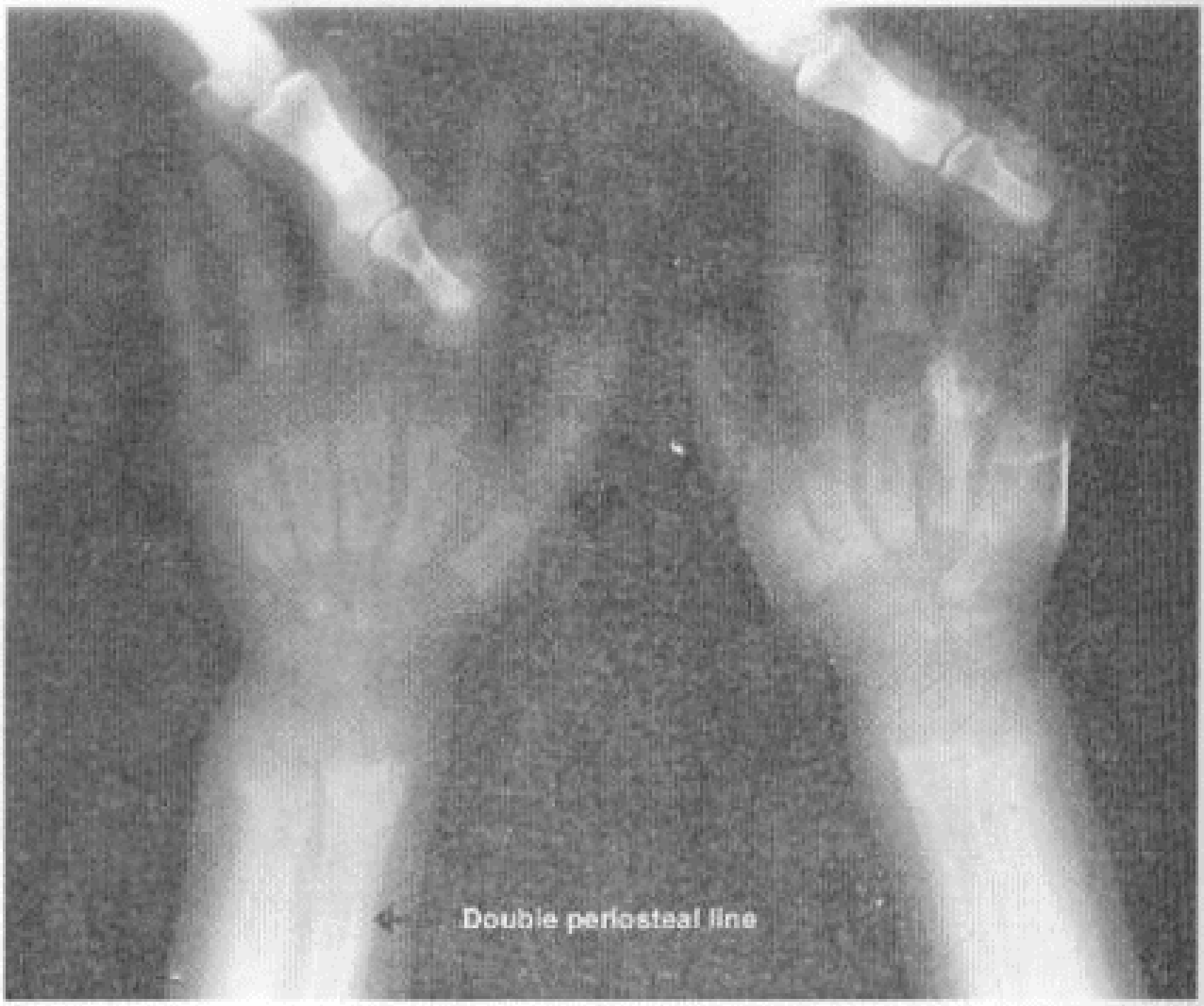

X-ray wrist joint showing: -

- Wide joint space
- Cupping of the metaphyseal area with frayed epiphyseal line
- Decreased bone density
- Double periosteal line

<u>Active rickets</u>

- Healing rickets

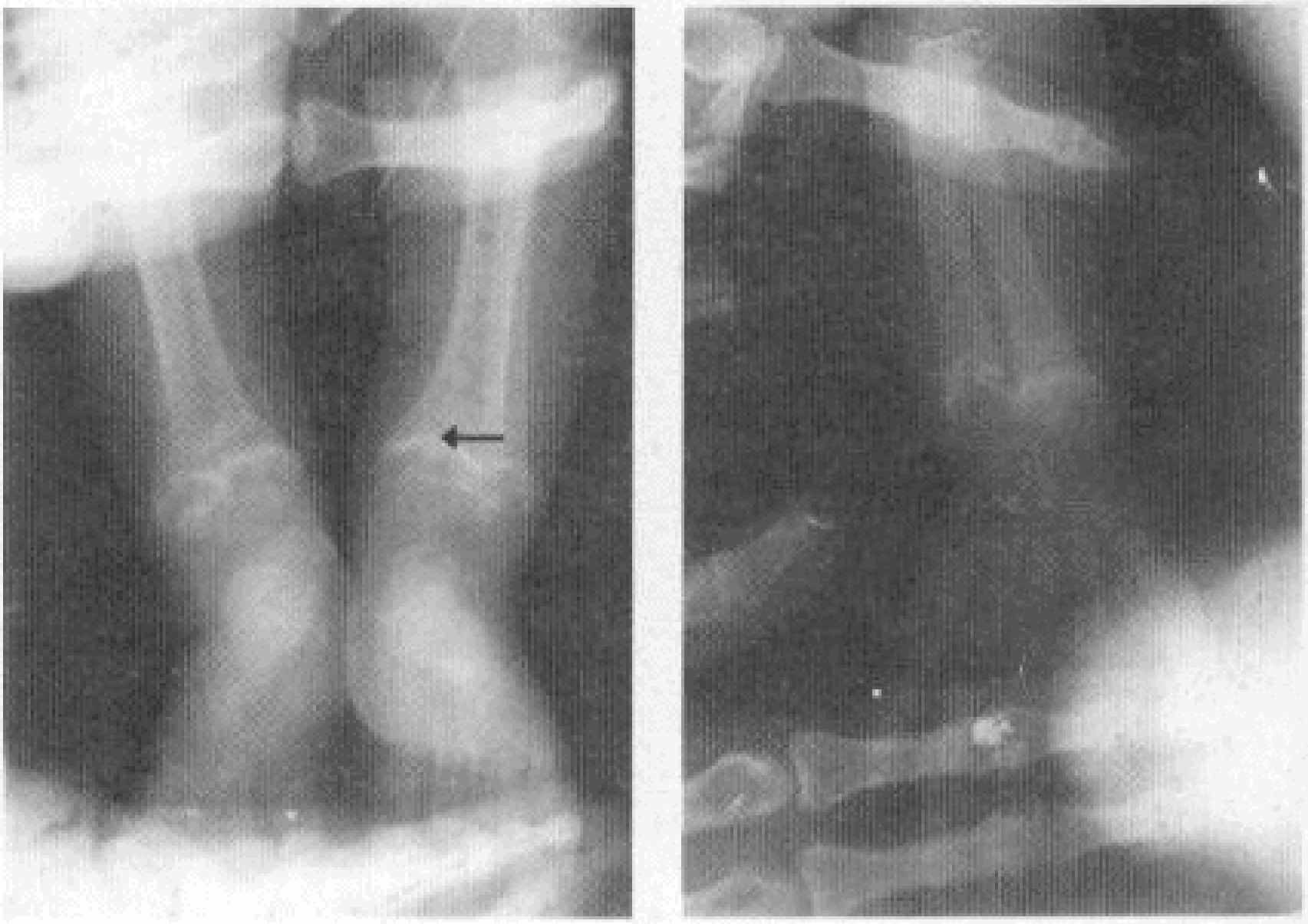

X ray wrist and ankle joints showing

- Wide joint space
- Cupping of the metaphyseal area
- White concave line at the lower ends of radius and ulna (line of provisional calcification)- similar changes are present of the bones of the lower limbs
- Decreased bone density

- **Active and healing rickets**

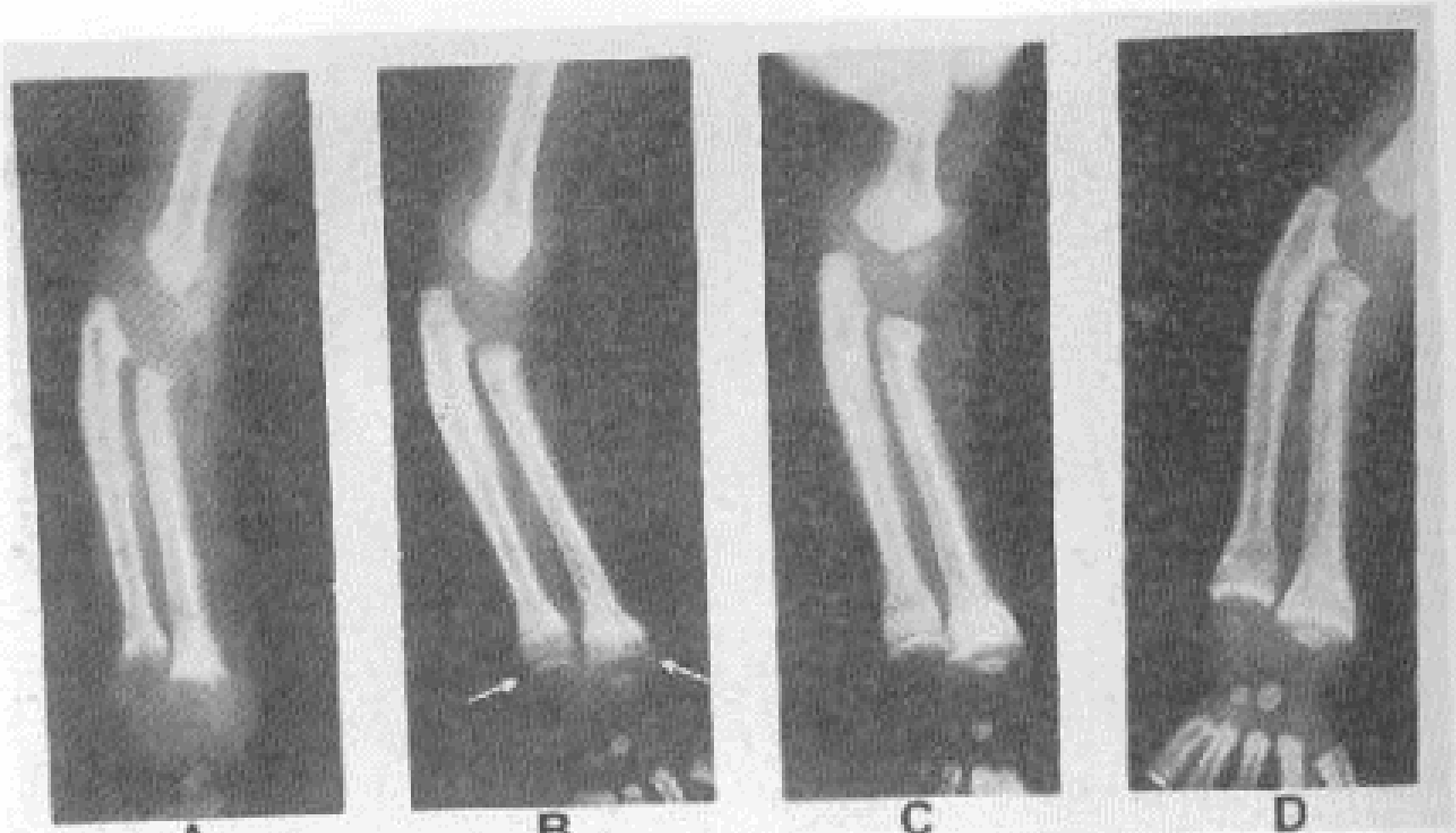

X-ray wrist joint showing: -

1- Active rickets
- Wide joint space
- Cupping of the metaphyseal area with frayed epiphyseal line
- Decreased bone density

2- Healing rickets
- Start of healing proc
appear as thin line separate from the shaft

3- Healing rickets
- Line of provisional calcification became more prominent

3- Healing rickets
- Line of provisional calcification is more dense and continuos with shaft

Healed rickets

X-ray wrist joint showing: -

- Normal joint space
- Metaphyseal are is normal (no cupping)- but the epiphyseal line is more dense than the rest of the bone
- More or less normal bone density

3- Osteogenesis imperfecta

Skeletal survey showing: -

- Marked decrease in the one density
- Loss of differentiation between medulla and cortex
- Multiple fractures with malunion
- Marked bone deformities

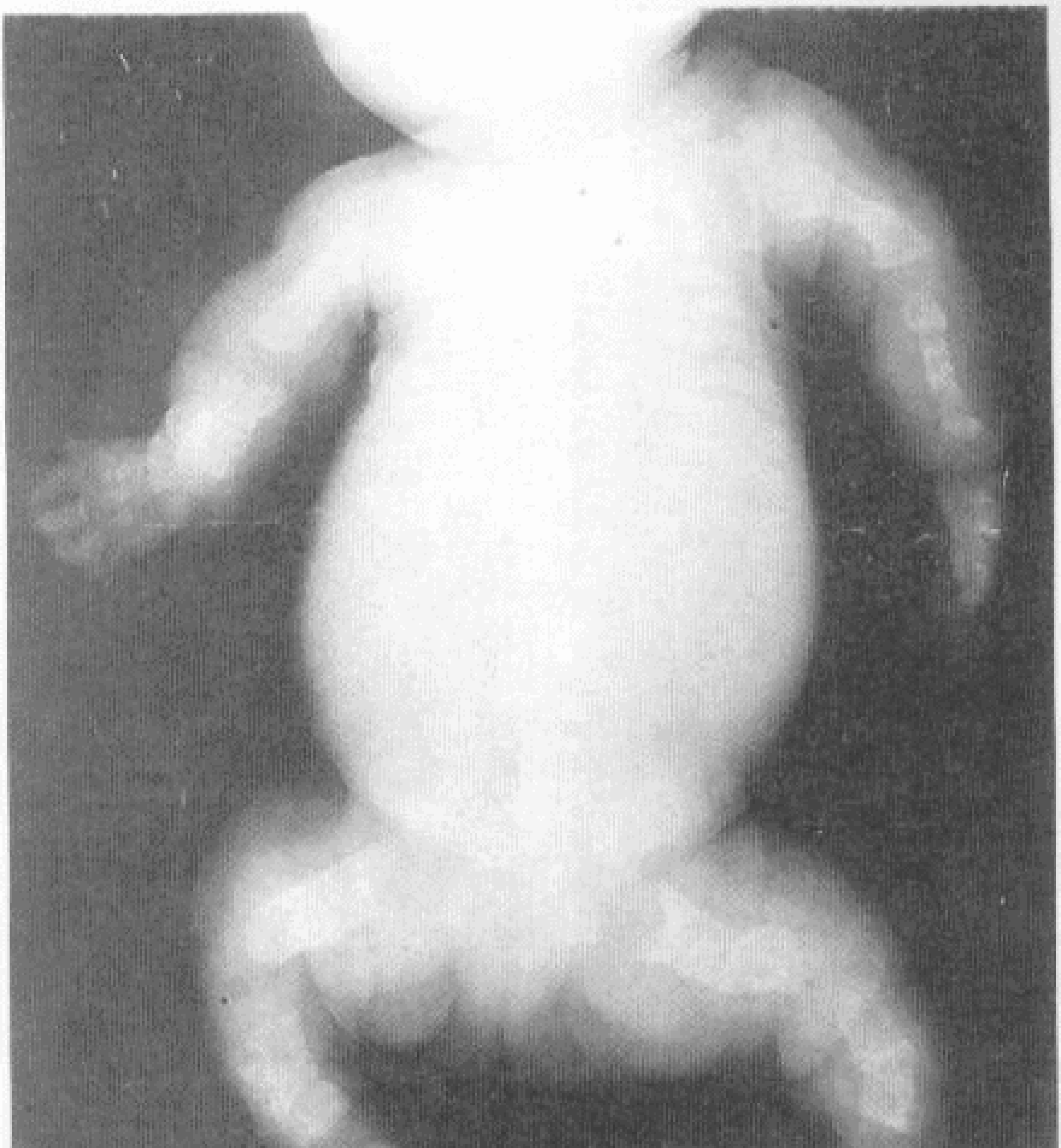

Skeletal survey showing: -

- Marked decrease in the one density
- Loss of differentiation between medulla and cortex
- Multiple fractures with malunion
- Marked bone deformities

Osteogenesis imperfecta

4- Osteopetrosis (marble bone disease)

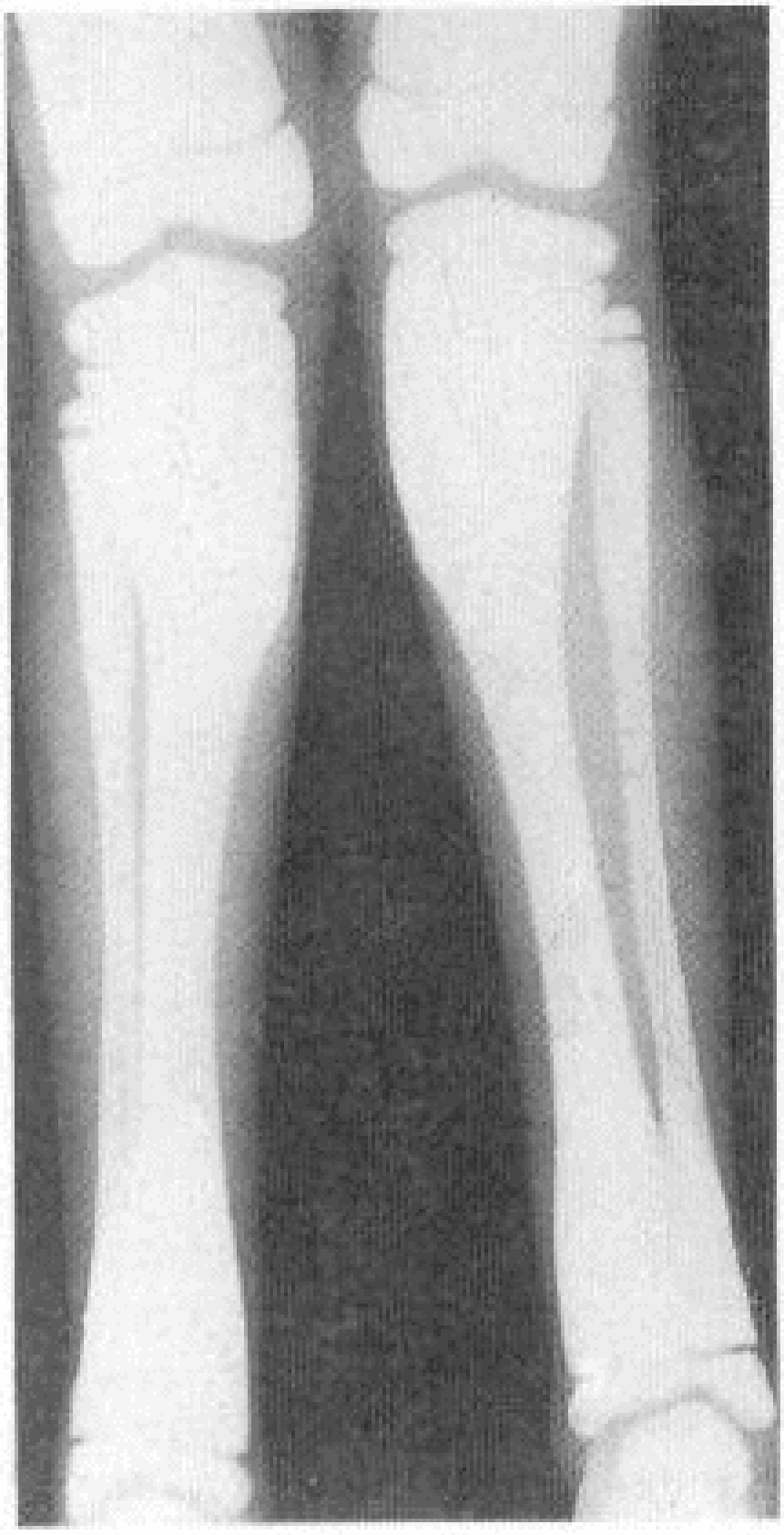

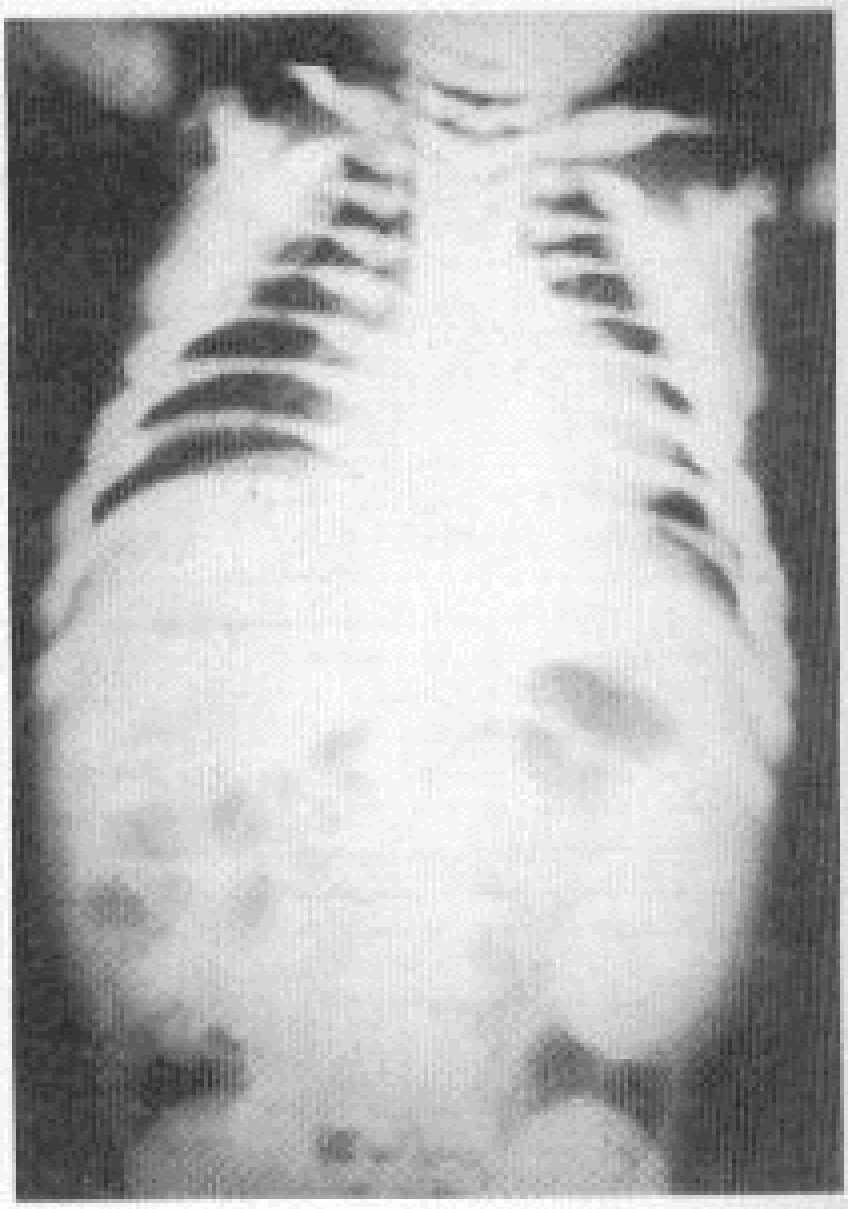

Skeletal survey showing: -

- Marked increase in bone density (marble like bone)
- Loss of differentiation between medulla and cortex

Normal skull

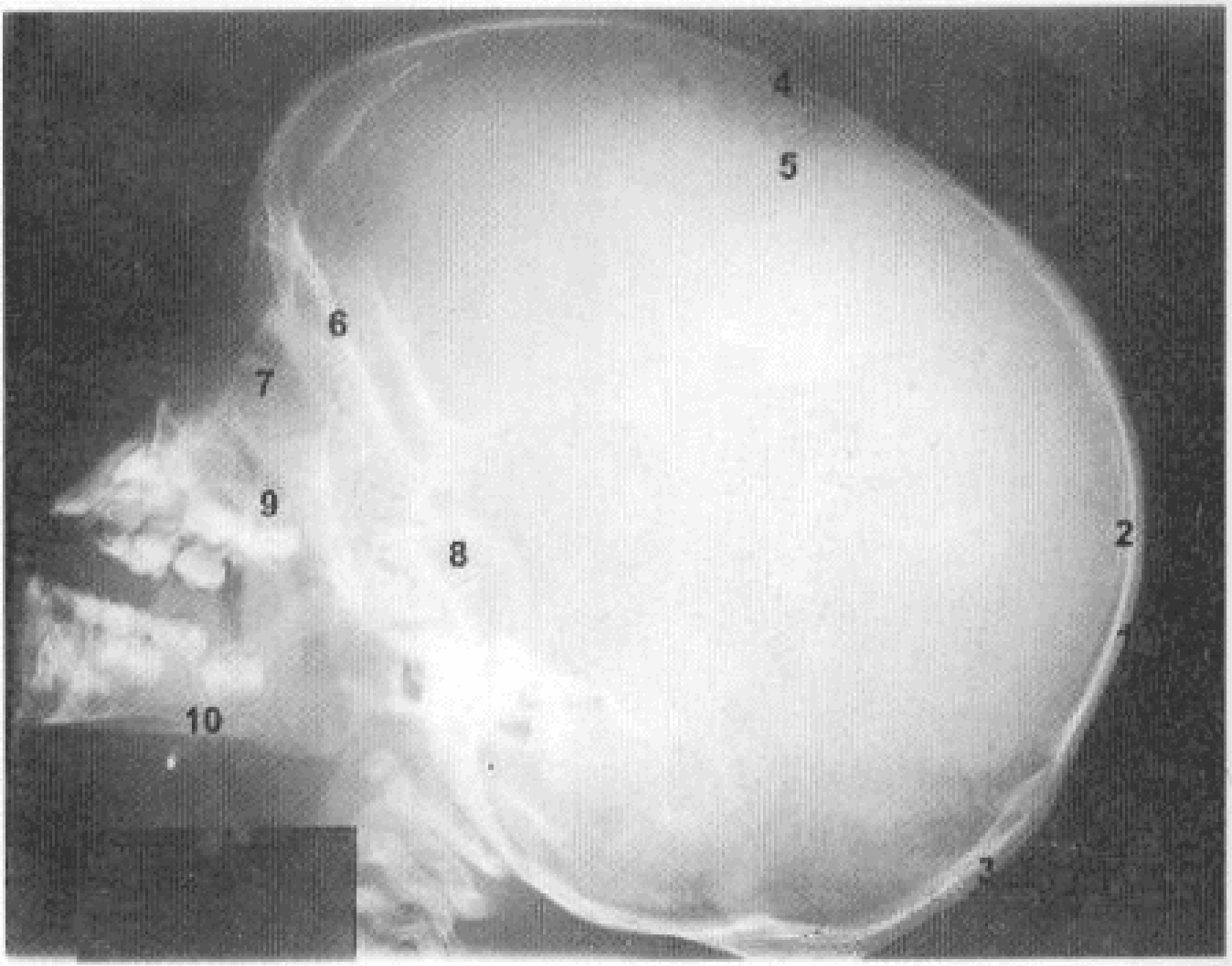

1- Outer table
2- Inner table
3- Diploic space
4- Anterior fontanelle
5- Coronal suture
6- Roof of the orbit
7- Orbit
8- Sella turcica
9- Maxilla
10-Mandibule

1- Microcephaly

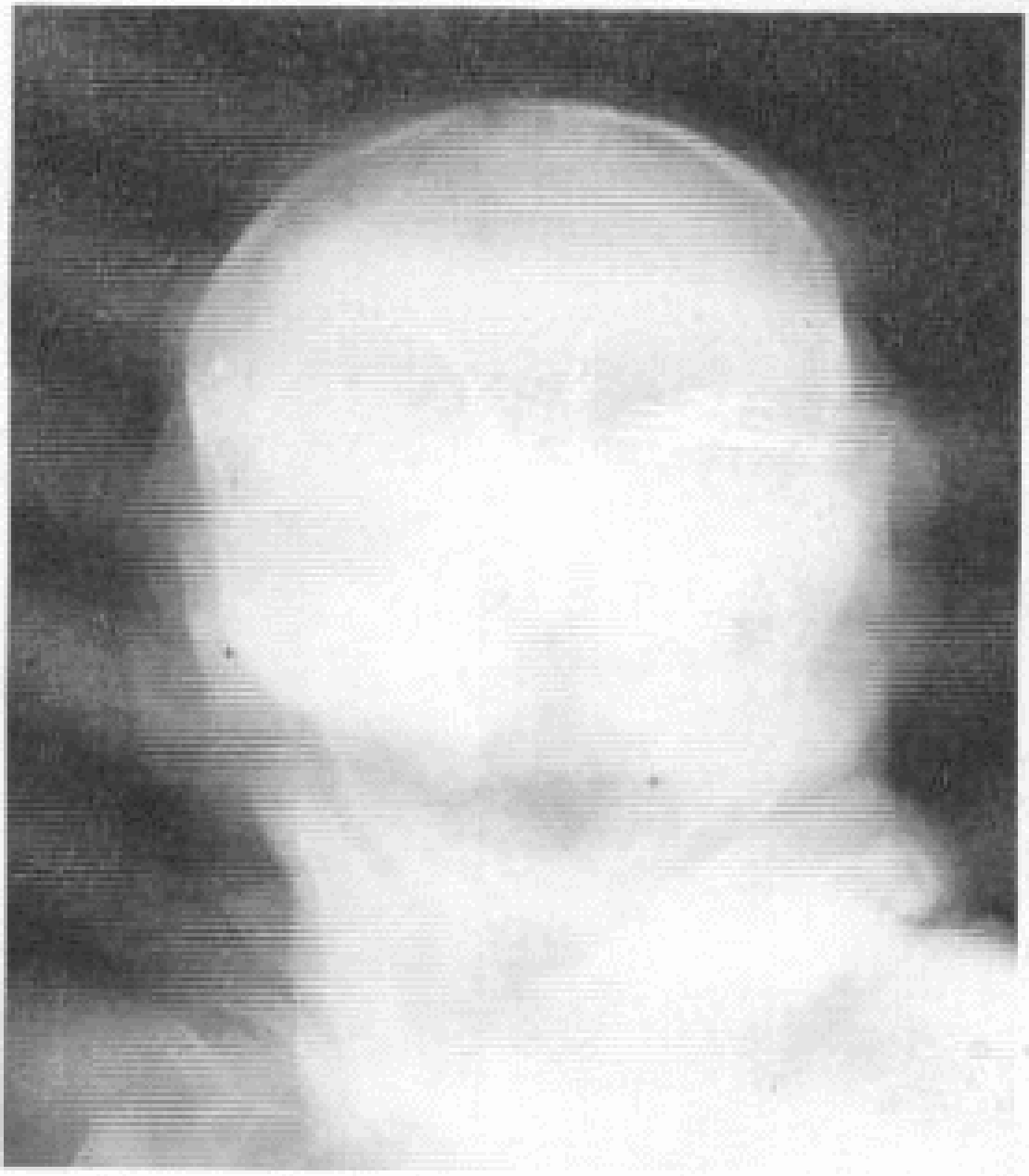

- Skull X ray postero-anterior view
- Marked decrease in the size of the cranial bone

Causes

I- Primary (genetic)
- 1-Familial (autosomal recessive)
- 2-Autosomal dominant
- 3-Syndromes (Down - Edward- Cri du chat)

II- Secondary (non genetic)
- 1-Prenatal causes
  - -Intrauterine infections (cytomeglovirus- Rubella)
  - -Irradiation
  - -Toxins e.g. → fetal alcohol syndrome or fetal hydantoin syndrome
- 2-Natal causes
  - -Hypoxic ischemic injury
  - -Intracranial hemorrhage
- 3-Post- natal causes
  - -Kernicterus
  - -CNS infections
  - -Intracranial hemorrhage

2- Increased intracranial tension before closure of sutures

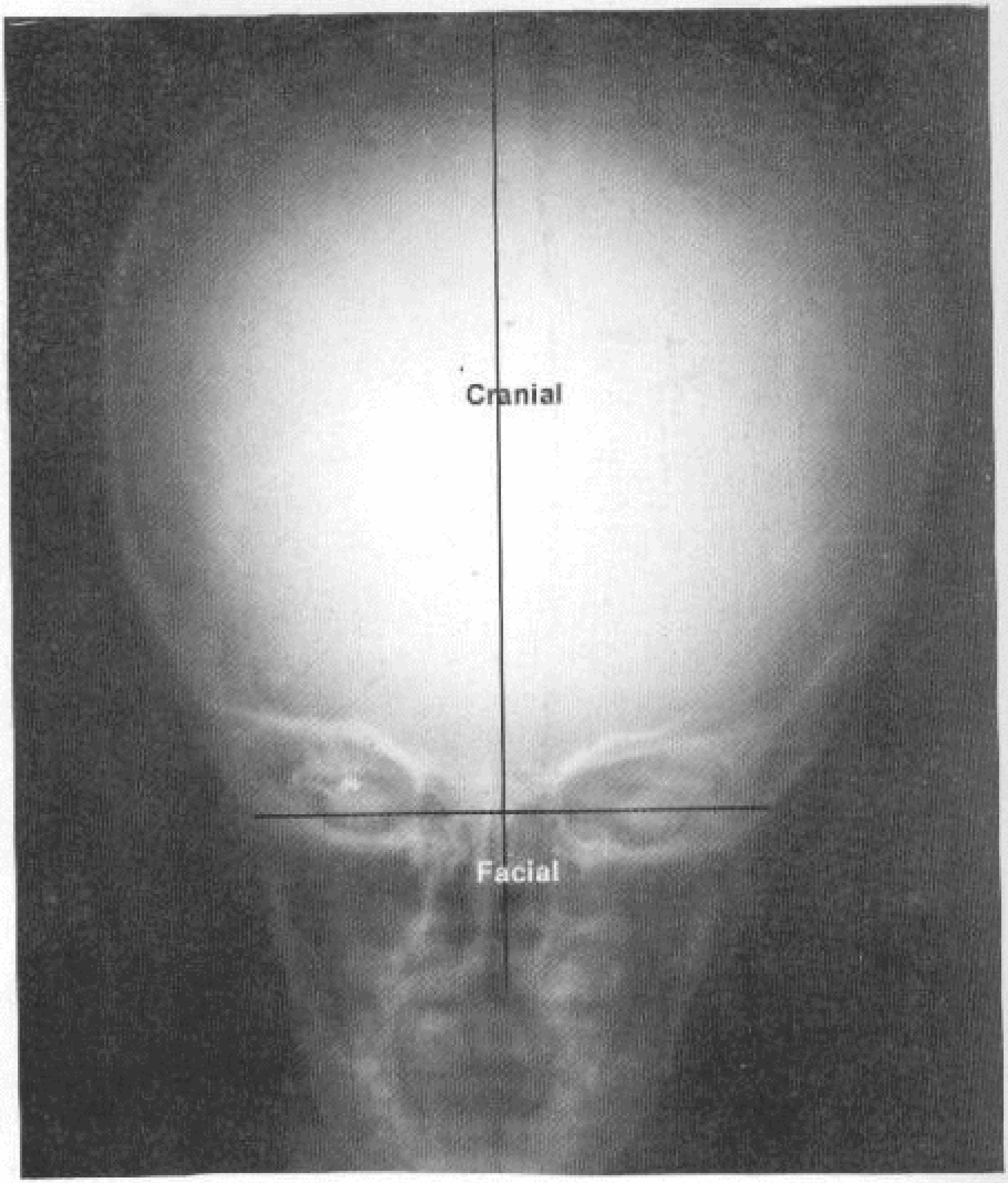

Skull X ray postero-anterior view

- Marked cranio-facial disproportion with marked increase in the size of the cranial bone with ratio: 5 (cranial bone) to 1 (facial bone) normal ratio is 3 to 1
- Separated sutures

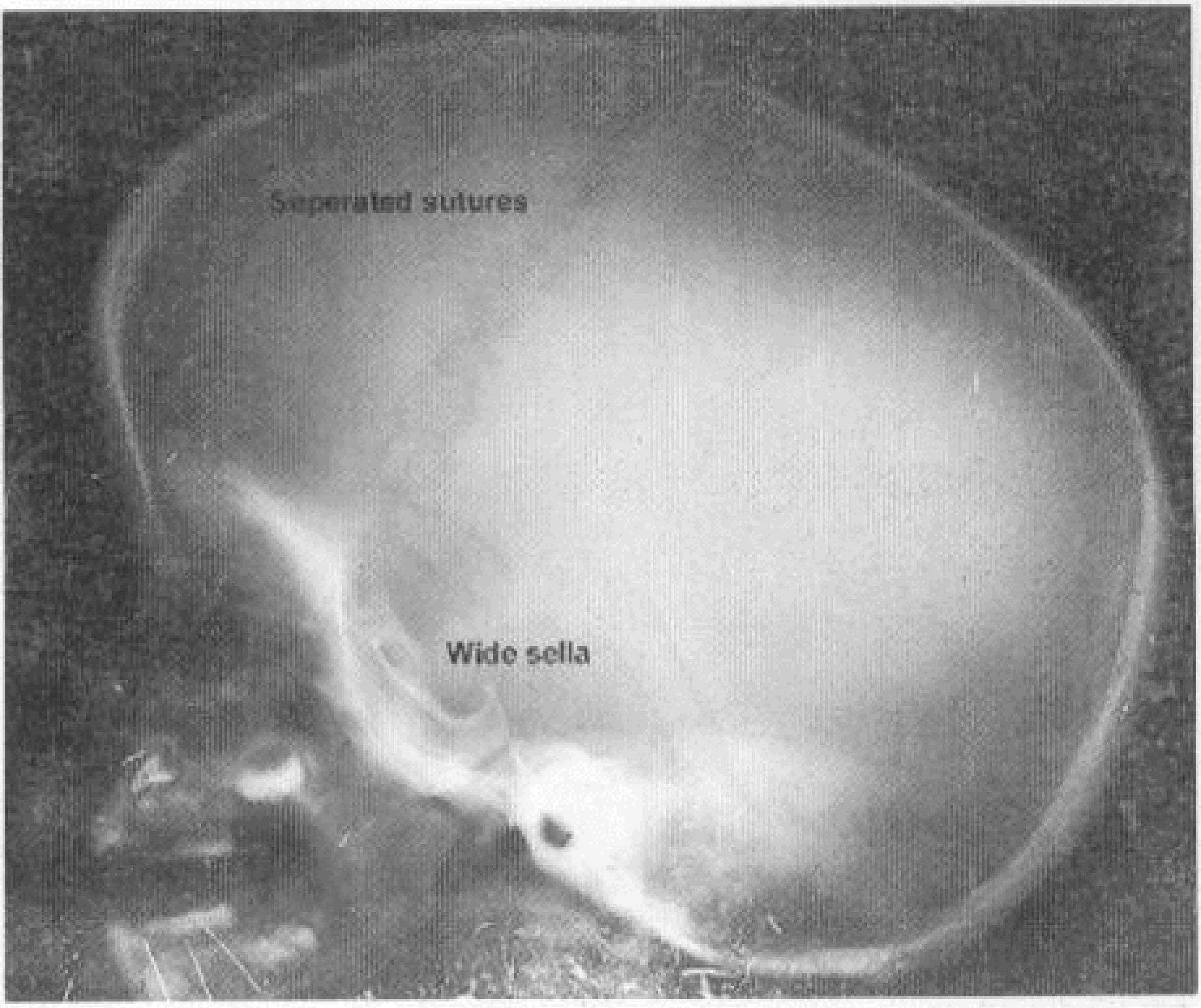

X ray skull lateral view

- Increase in the size of cranial bone
- Separated sutures
- Wide sella

Increased intracranial tension for differential diagnosis

Causes of increased intracranial tension

Increase tension without a mass lesion:

- Hydrocephalus.
- Subdural hematoma.
- Subdural effusion.

Increase tension with a mass lesion:

- Brain tumors.
- Tuberculoma.
- Chronic abscess

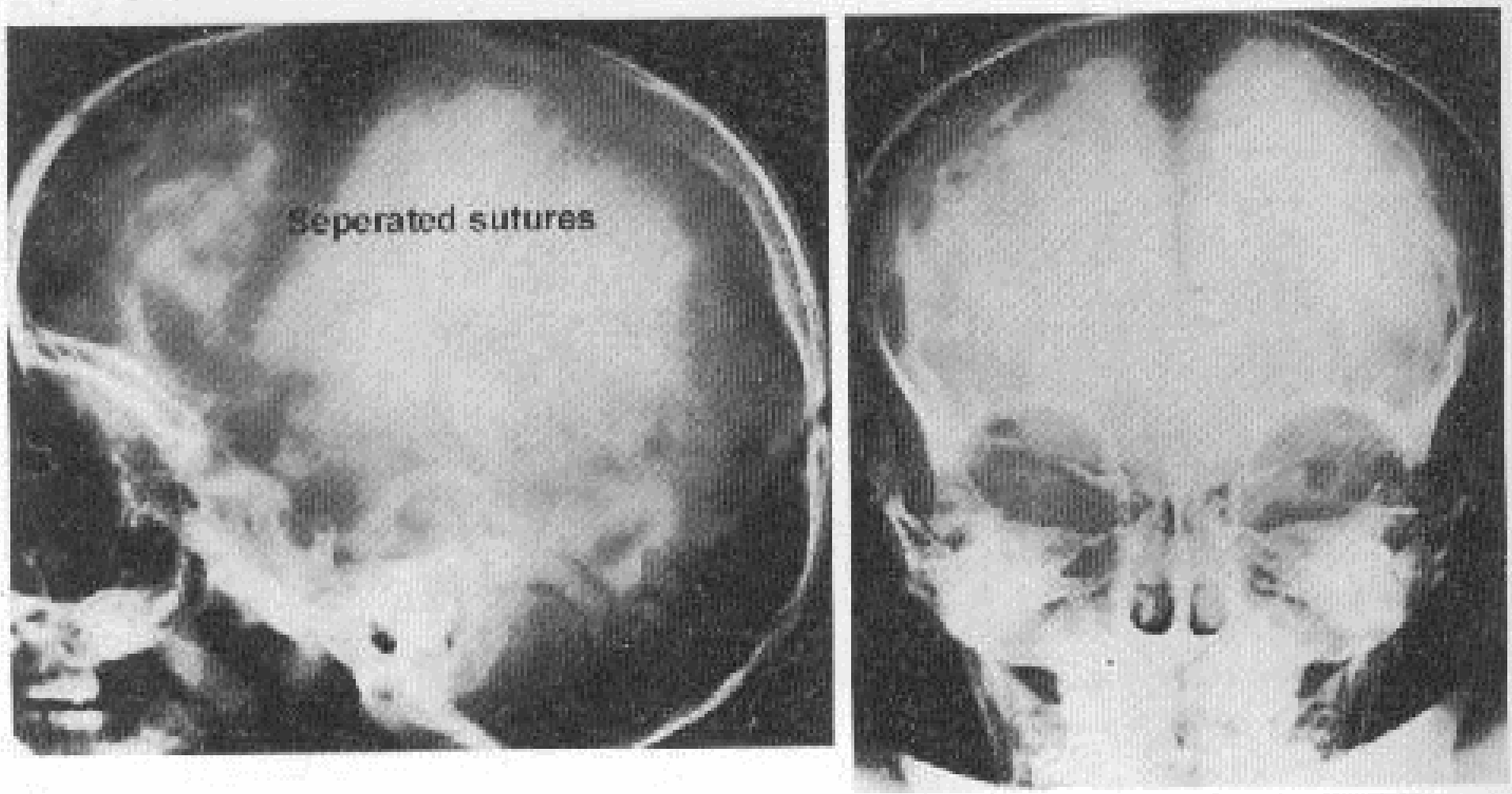

X ray skull postero-anterior and lateral view

- Cranio-facial disproportion (increased size of cranial bone)
- Separated sutures (cronal suture)

Increased intracranial tension

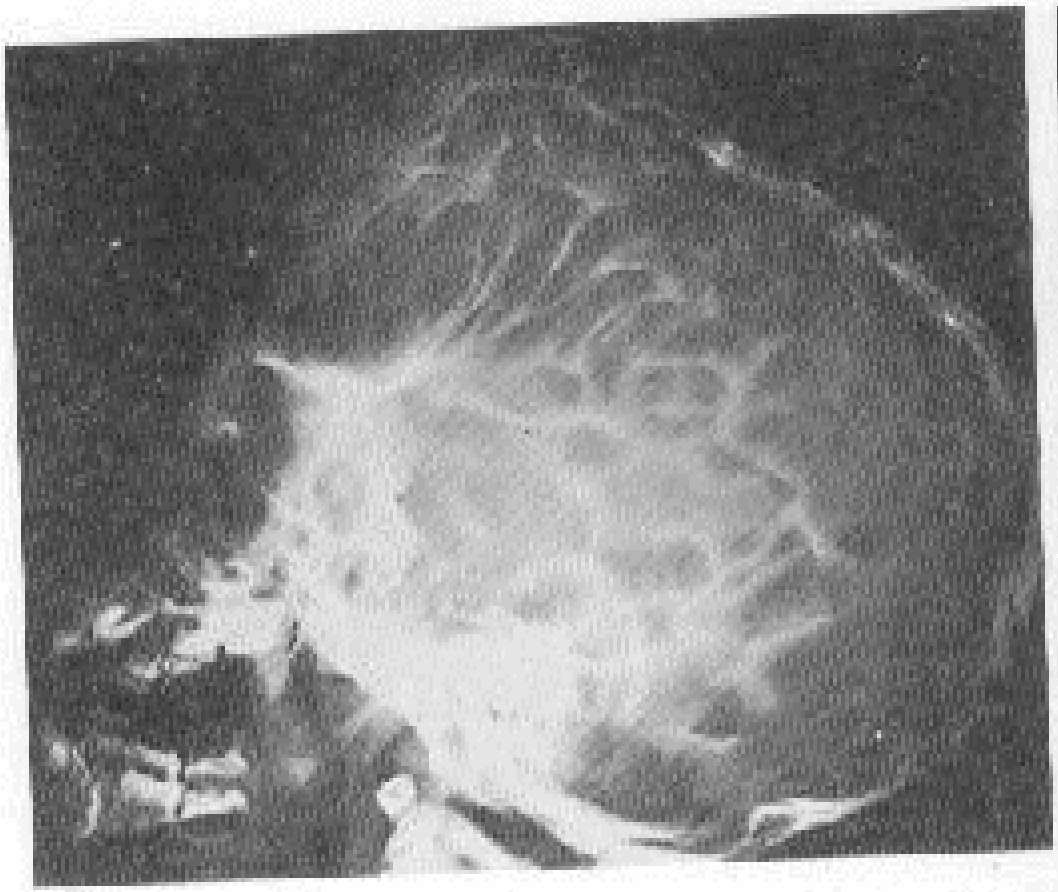 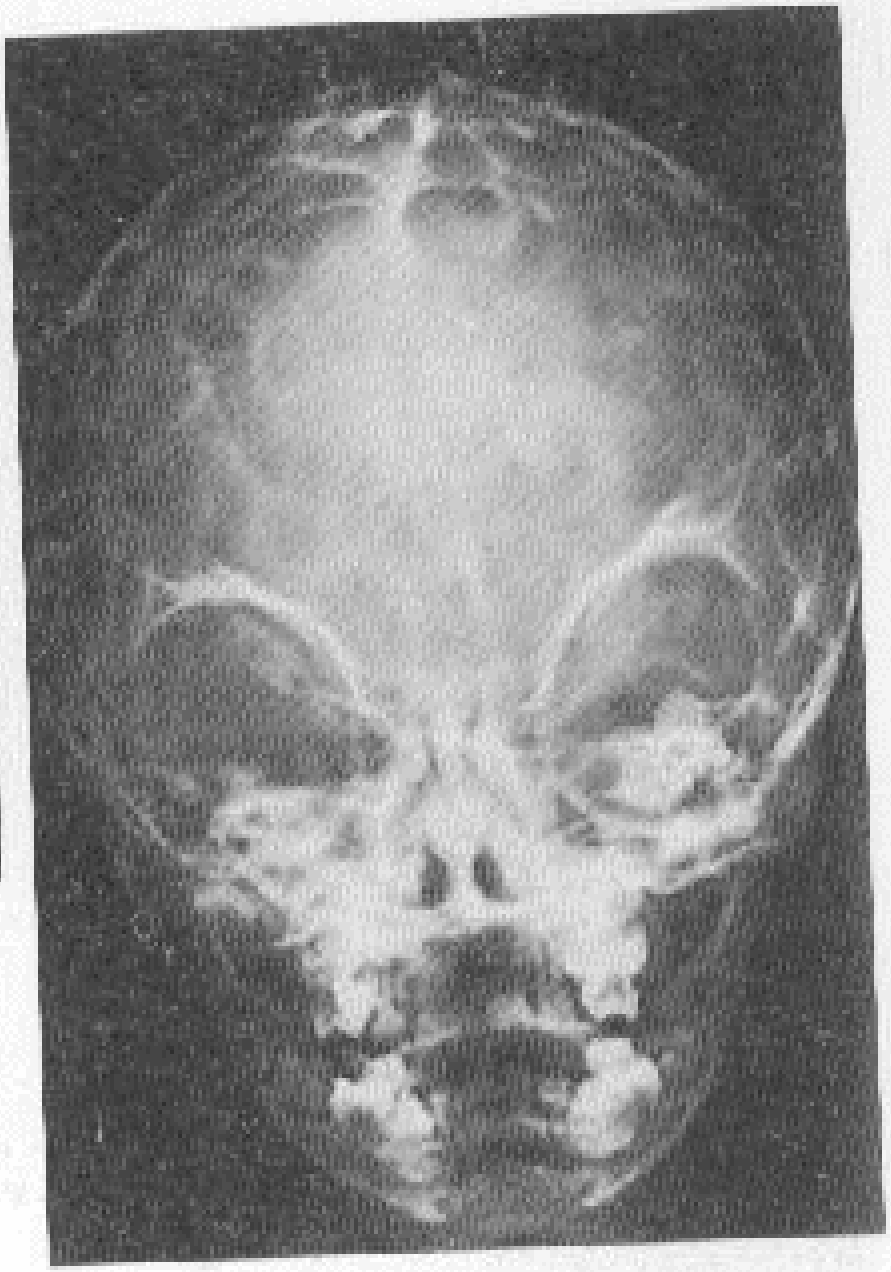

X ray skull postero-anterior and lateral view

- Increase in the skull convolutional markings with beaten silver appearance (finger prints) of the skull bone
- The skull appears also deformed

Craniostenosis

Causes of craniostenosis

- Isolated congenital deformity
- As a component of certain inherited syndromes
- Metabolic disorders e.g. idiopathic hypercalcaemia, hypophosphatasia
- After excessive thyroxin therapy

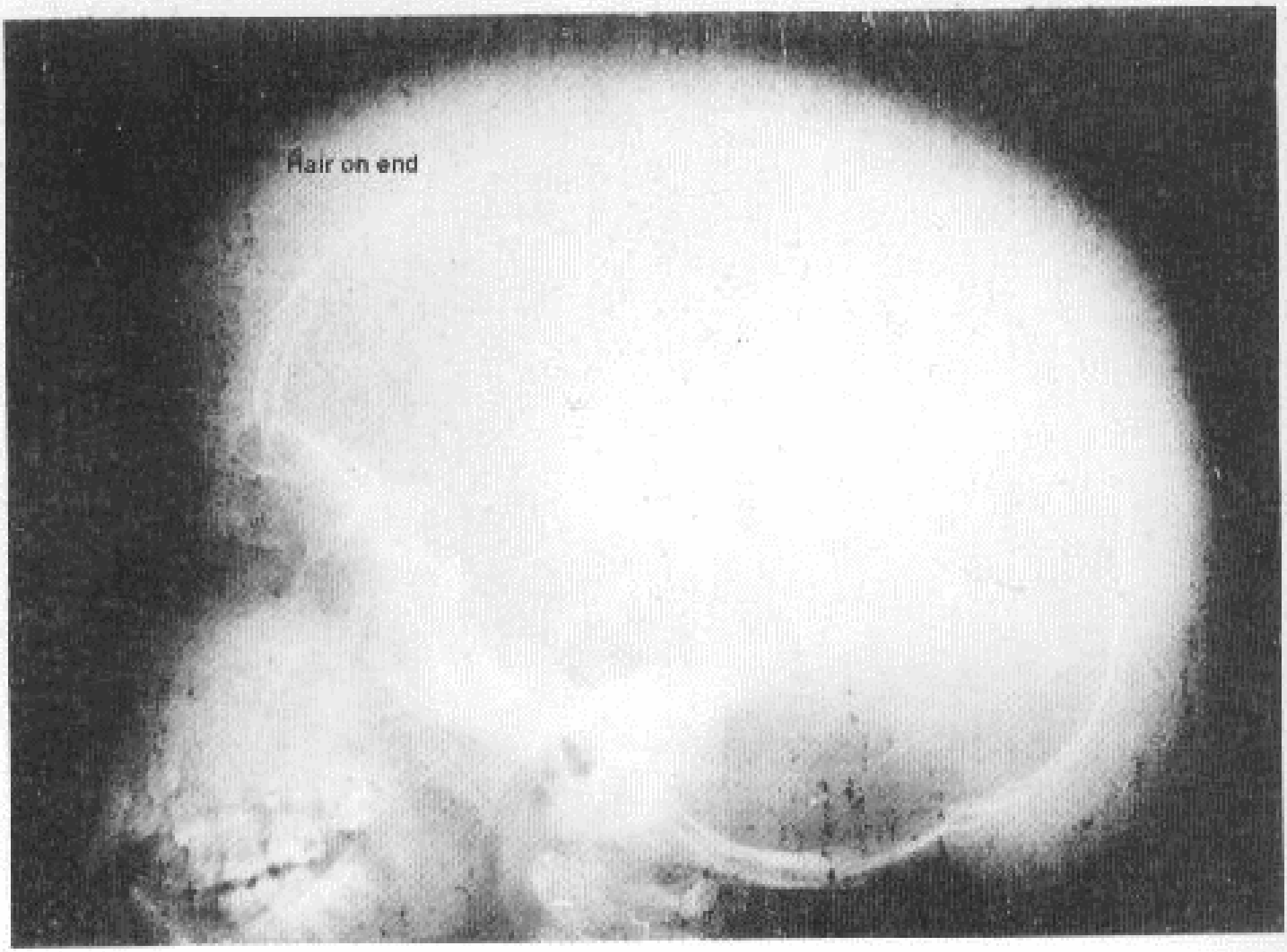

X ray skull lateral view

- Wide diploic space
- Characteristic hair on end appearance

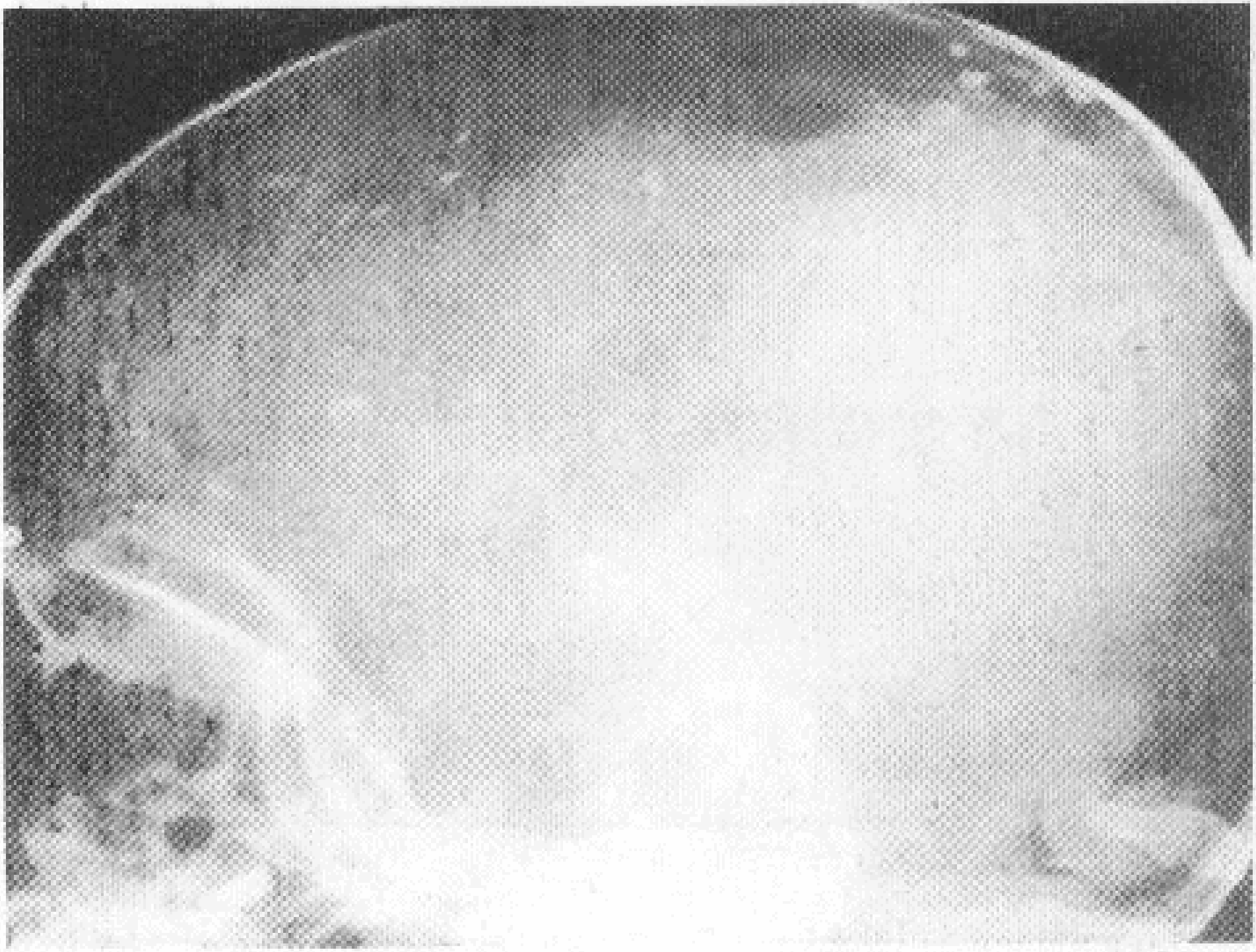

X ray skull lateral view

- Scattered calcification that appear as white dots

Causes of intracranial calcification

. Congenital infections (toxoplasmosis)

. Other infections

  - Meningitis- TB

. Intracranial hemorrhage- subdural hematoma

. Hyperparathyroidism

. Craniopharngioma

- Congenital hypertrophic pyloric stenosis

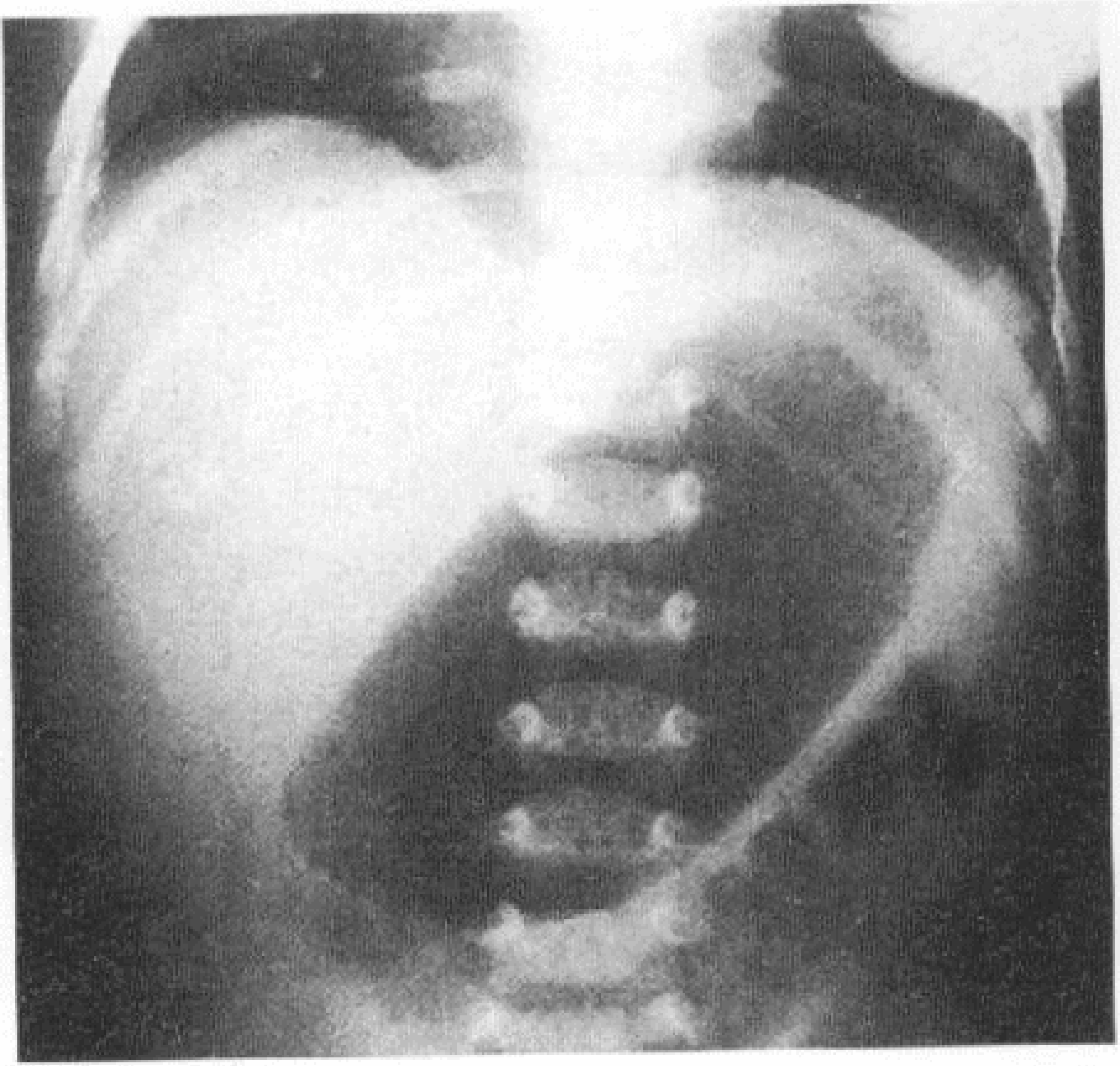

- Plain X ray of the abdomen upright position
- Large gastric air bubble due to pyloric stenosis
- Dilated stomach

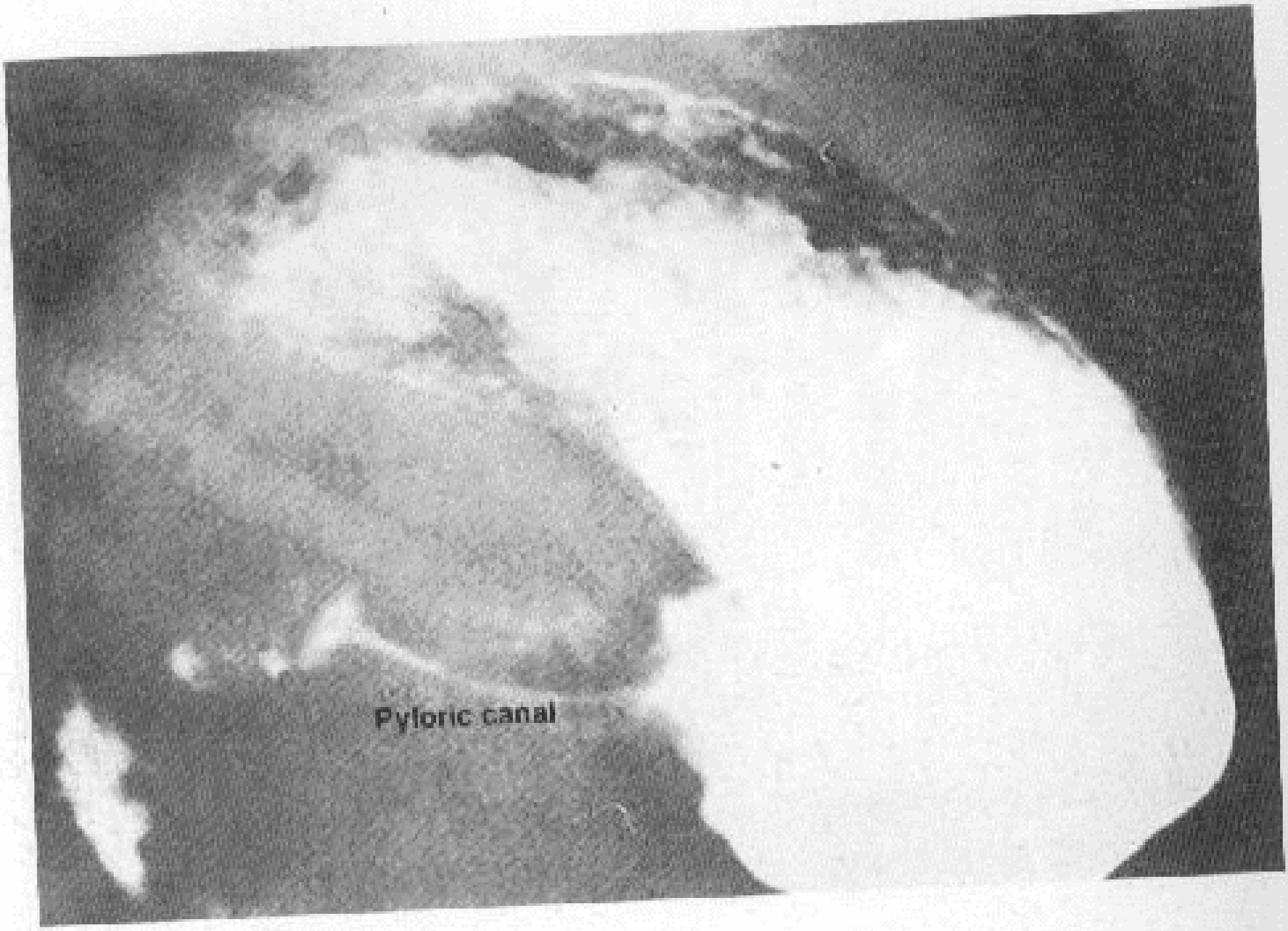

- Barium meal study of the stomach
- Markedly dilated stomach, which is distended by barium
- The pyloric canal is very thin, prolonged (string sign)
- The duodenal cap is umbrella - shaped
- Usually there is delayed gastric emptying

<u>Congenital hypertrophic pyloric stenosis</u>

- Duodenal atresia (high obstruction)

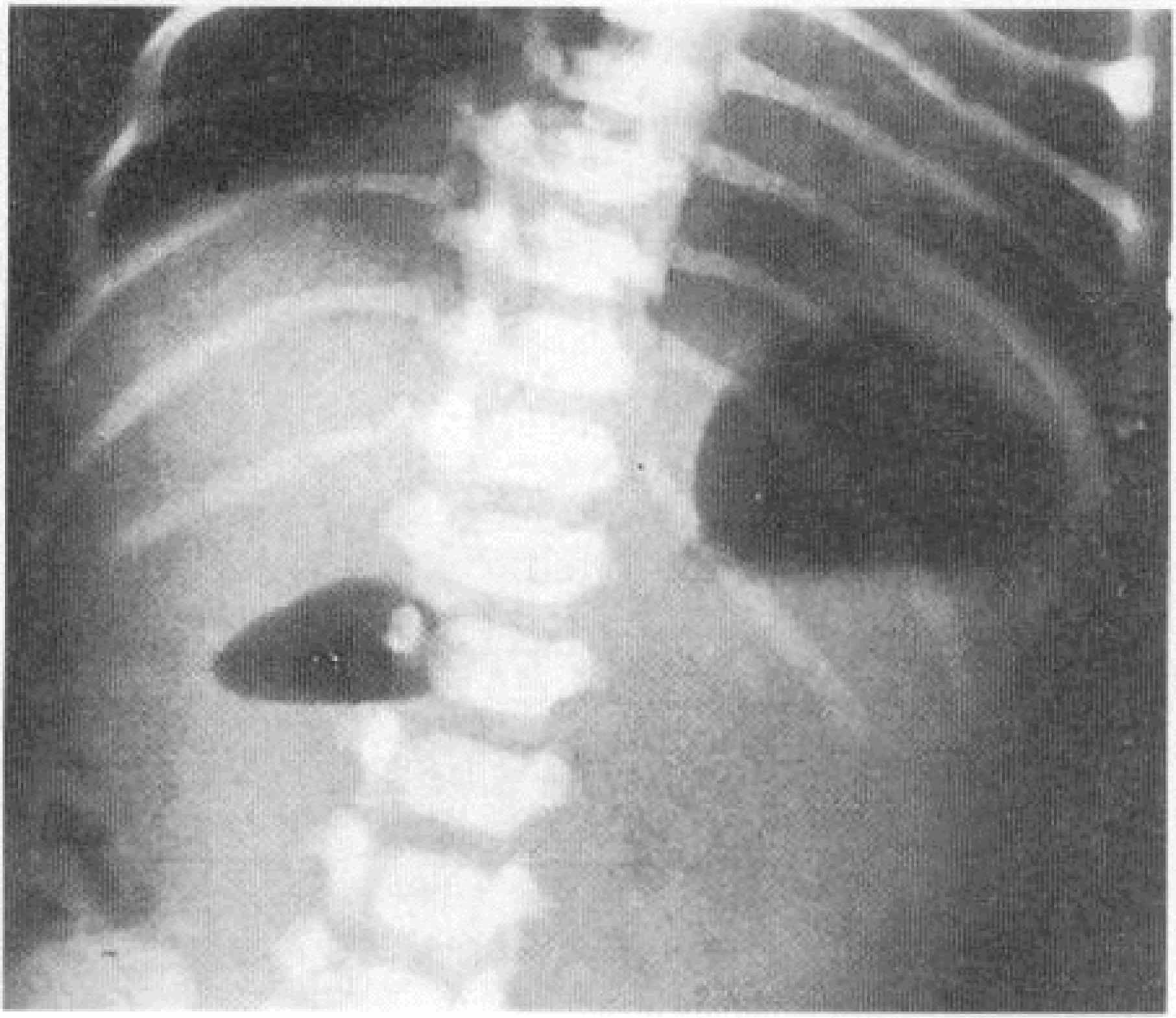

- Plain X ray of the abdomen upright position
- The abdomen is distended by two air and fluid levels (double bubble sign)
- No other gases are seen on the abdomen

- **Intestinal obstruction (low obstruction)**

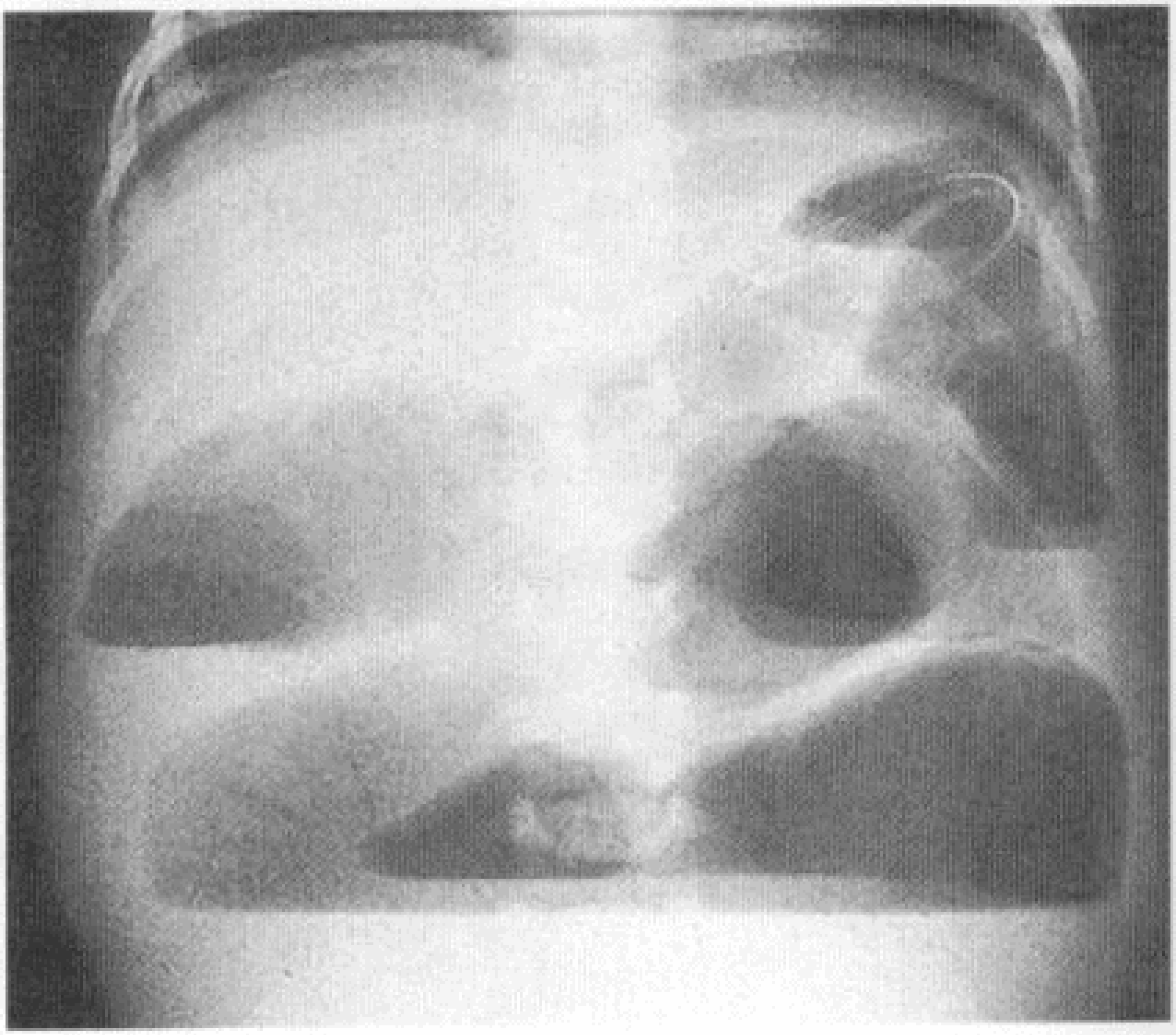

- Plain X ray of the abdomen upright position
- Multiple gas and fluid levels
- Distended intestinal loops

Causes of intestinal obstruction
- Imperforate anus
- Hirschsprung disease

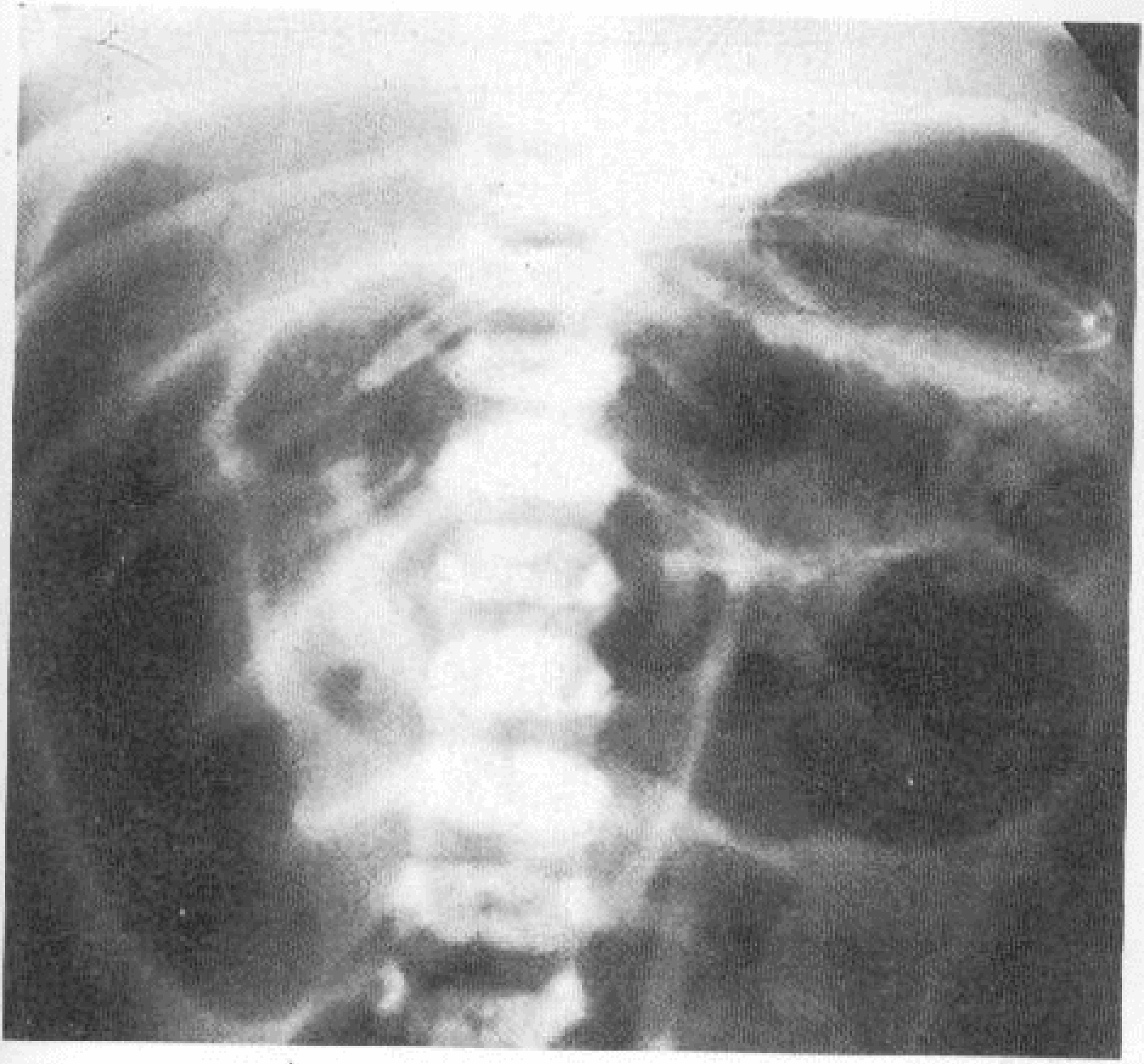

- Plain X ray of the abdomen upright position
- Multiple gas and fluid levels
- Distended intestinal loops

Intestinal obstruction (low obstruction)

Bone

Radiology of long bones 67
Normal bone 68
Closed fracture healing 67
Bone tumors 69
Healing fractures 71
Benign tumors 73
Osteogenesis imperfecta 76
Osteoporosis 78

Skull

Normal skull X-ray 79
Microcephaly 80
Increased intracranial pressure 80
Craniostenosis 81
Closed head injury 84
Metastases and fractures 85

Abdomen

Congenital hypertrophic pyloric stenosis 87
Duodenal atresia 89
Intestinal obstruction 90

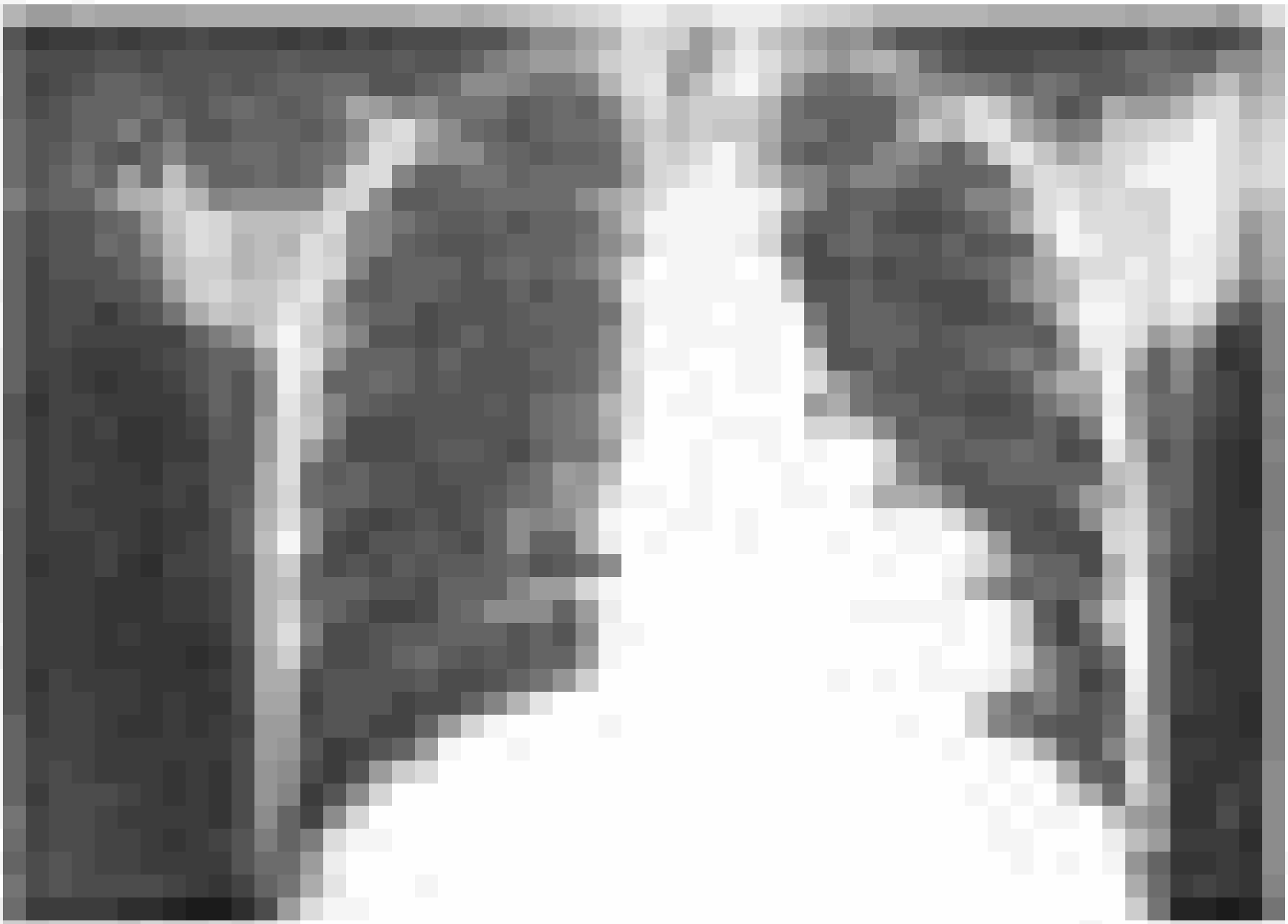

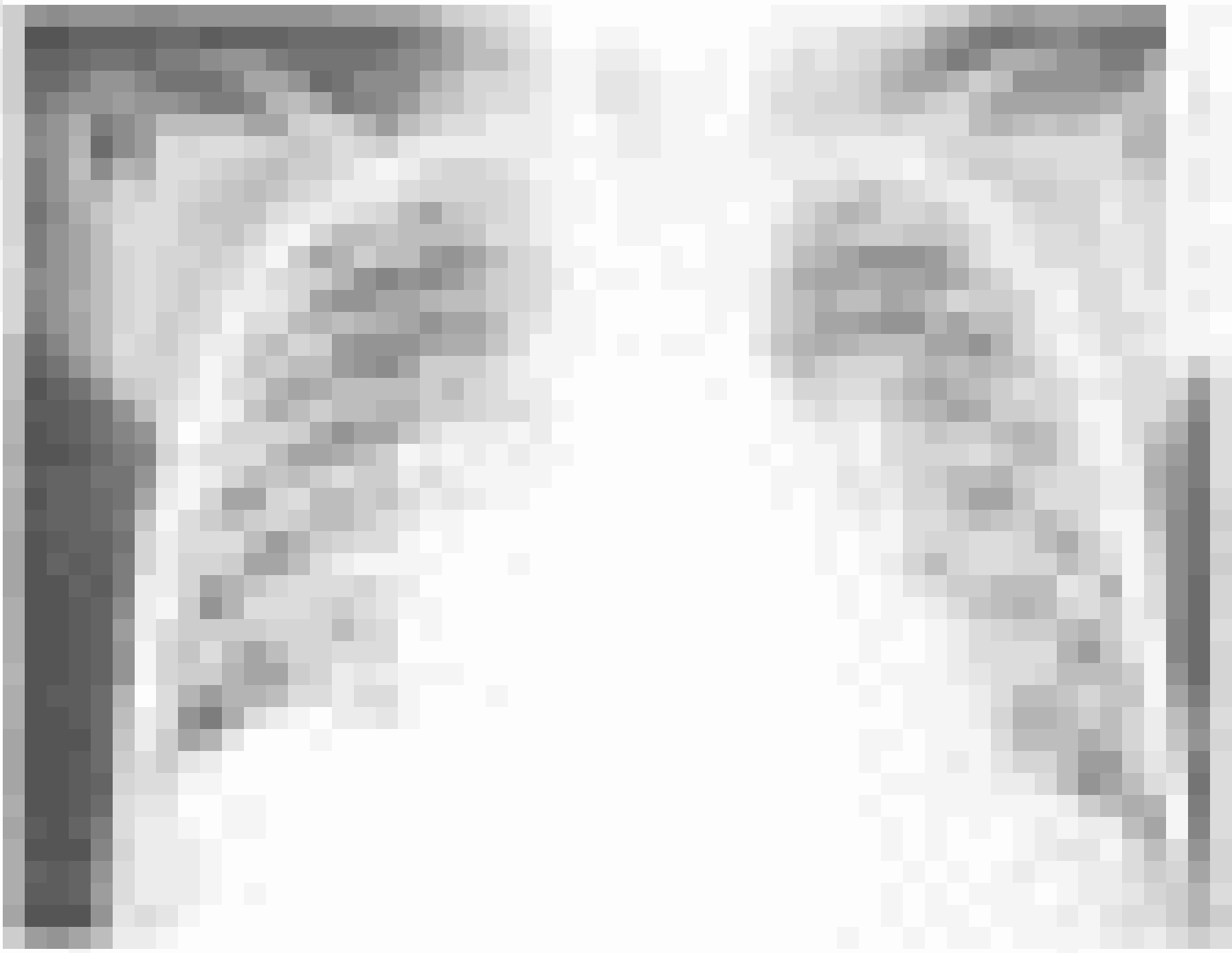

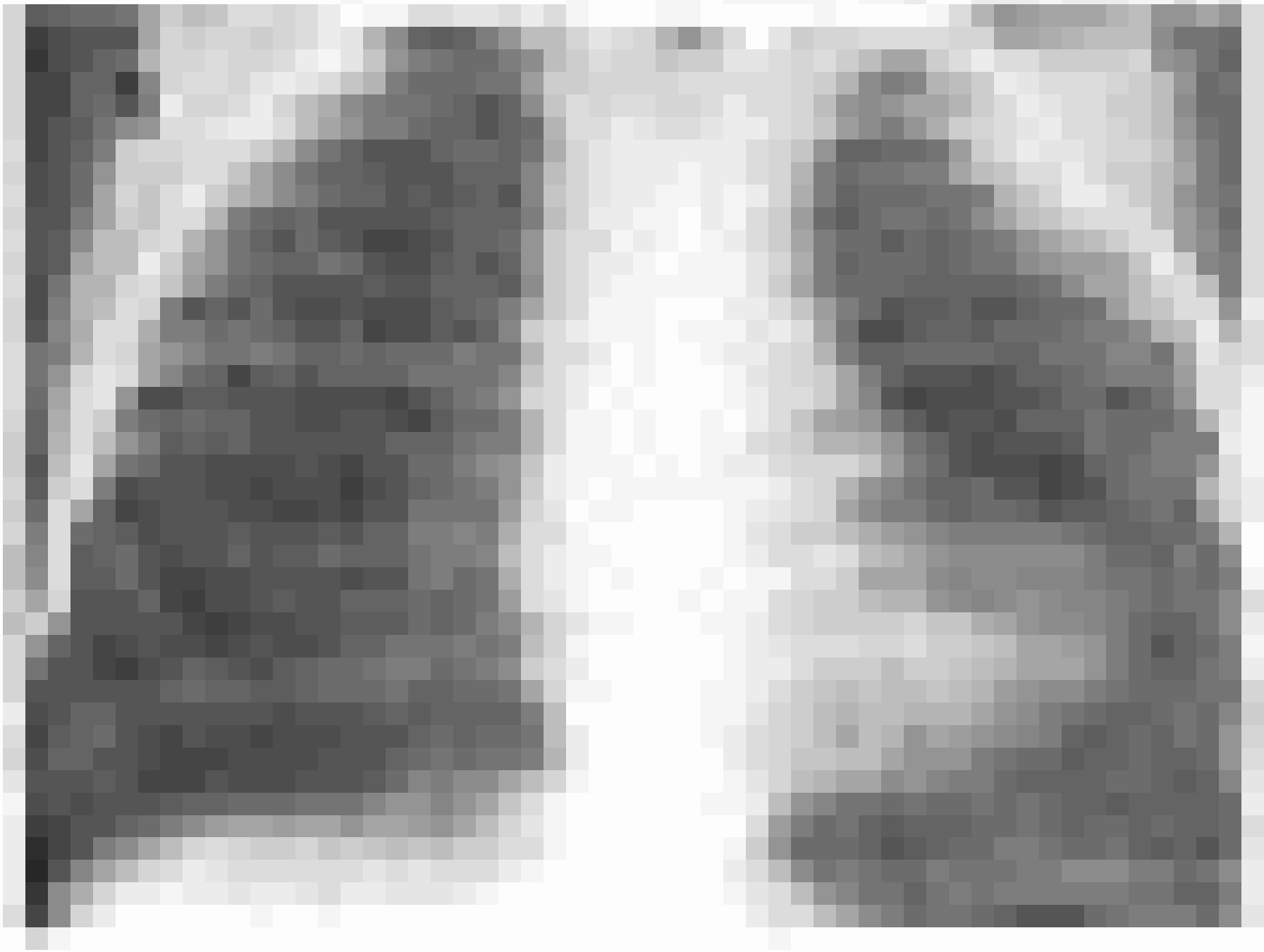

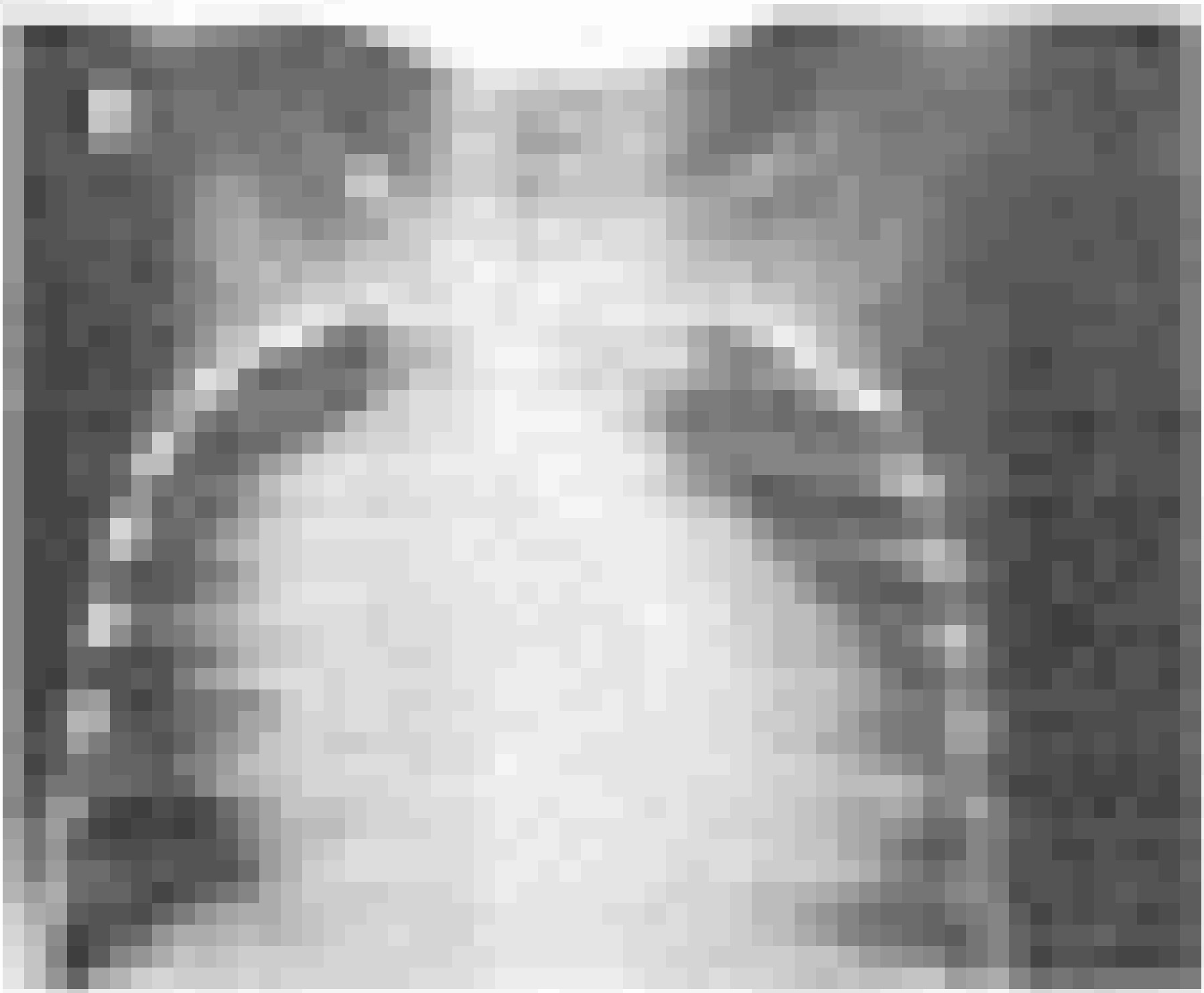









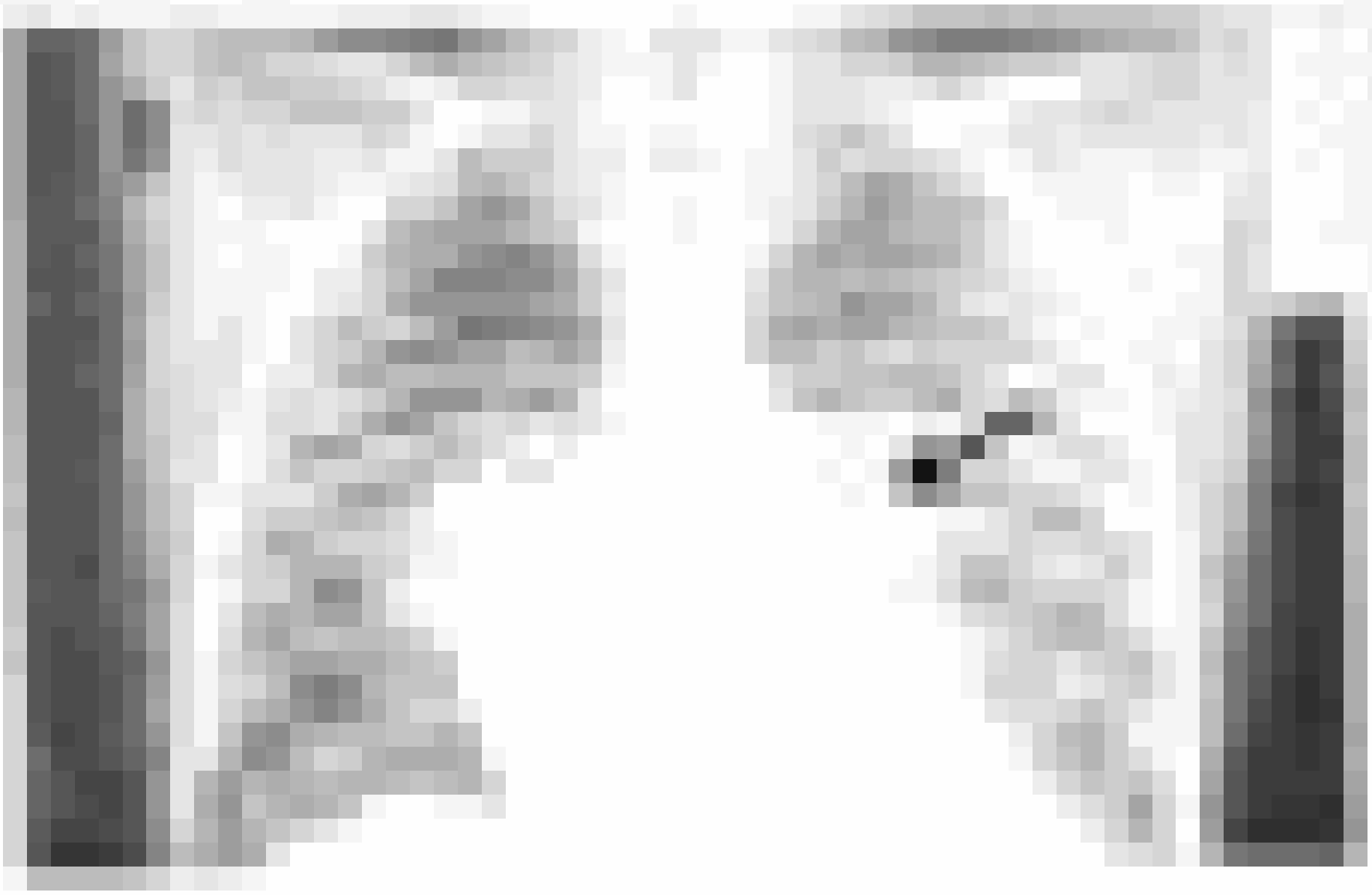

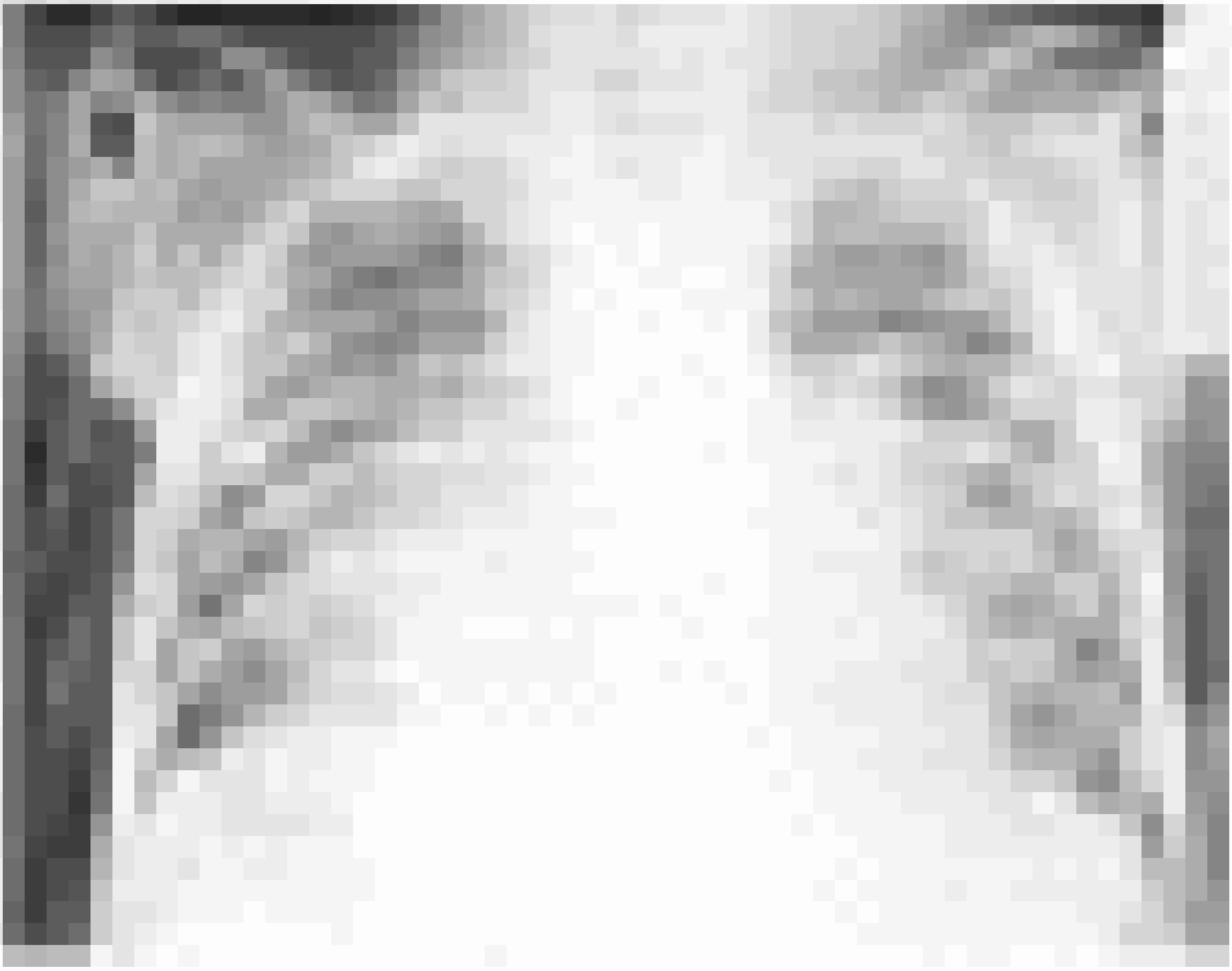

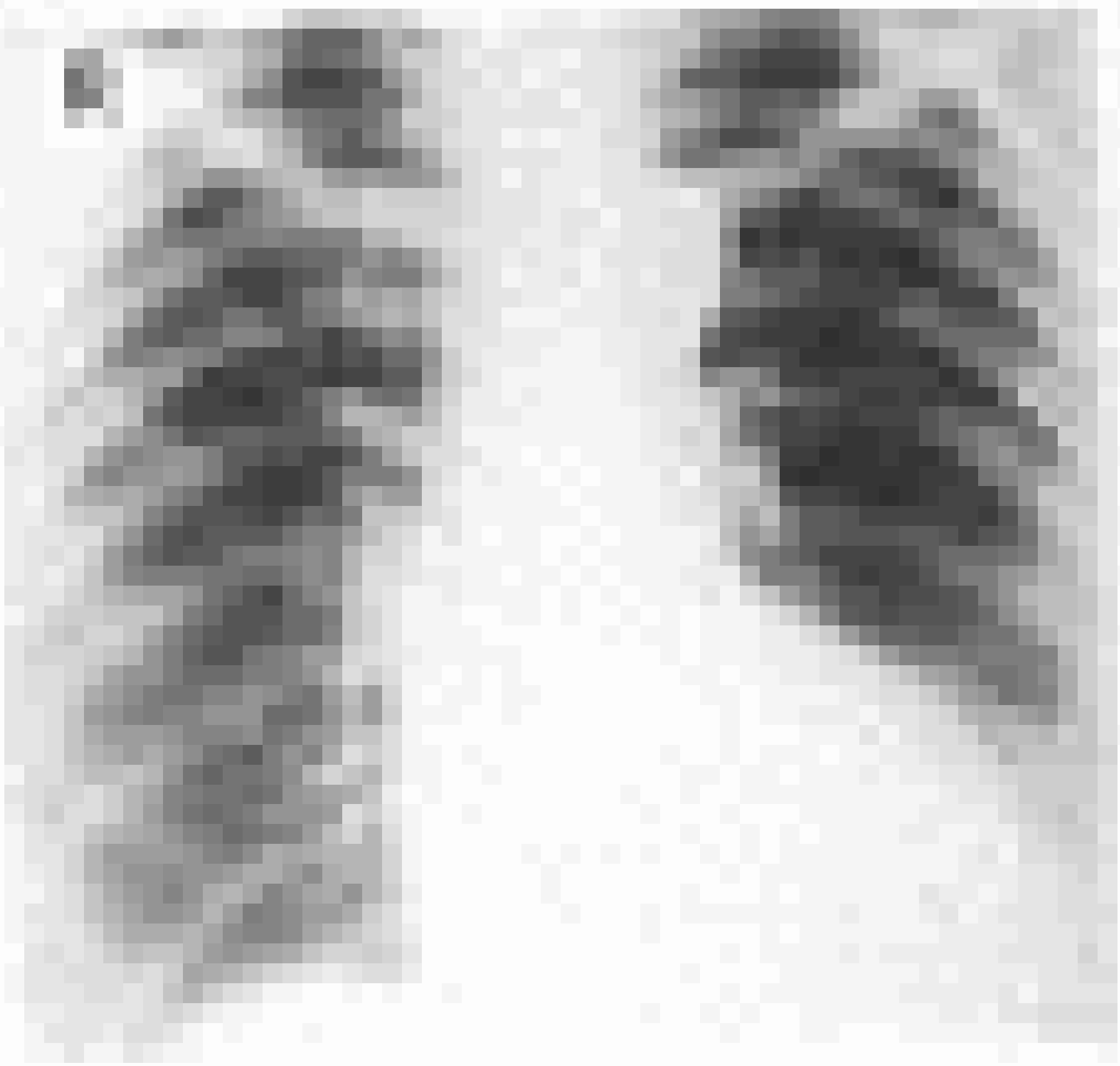

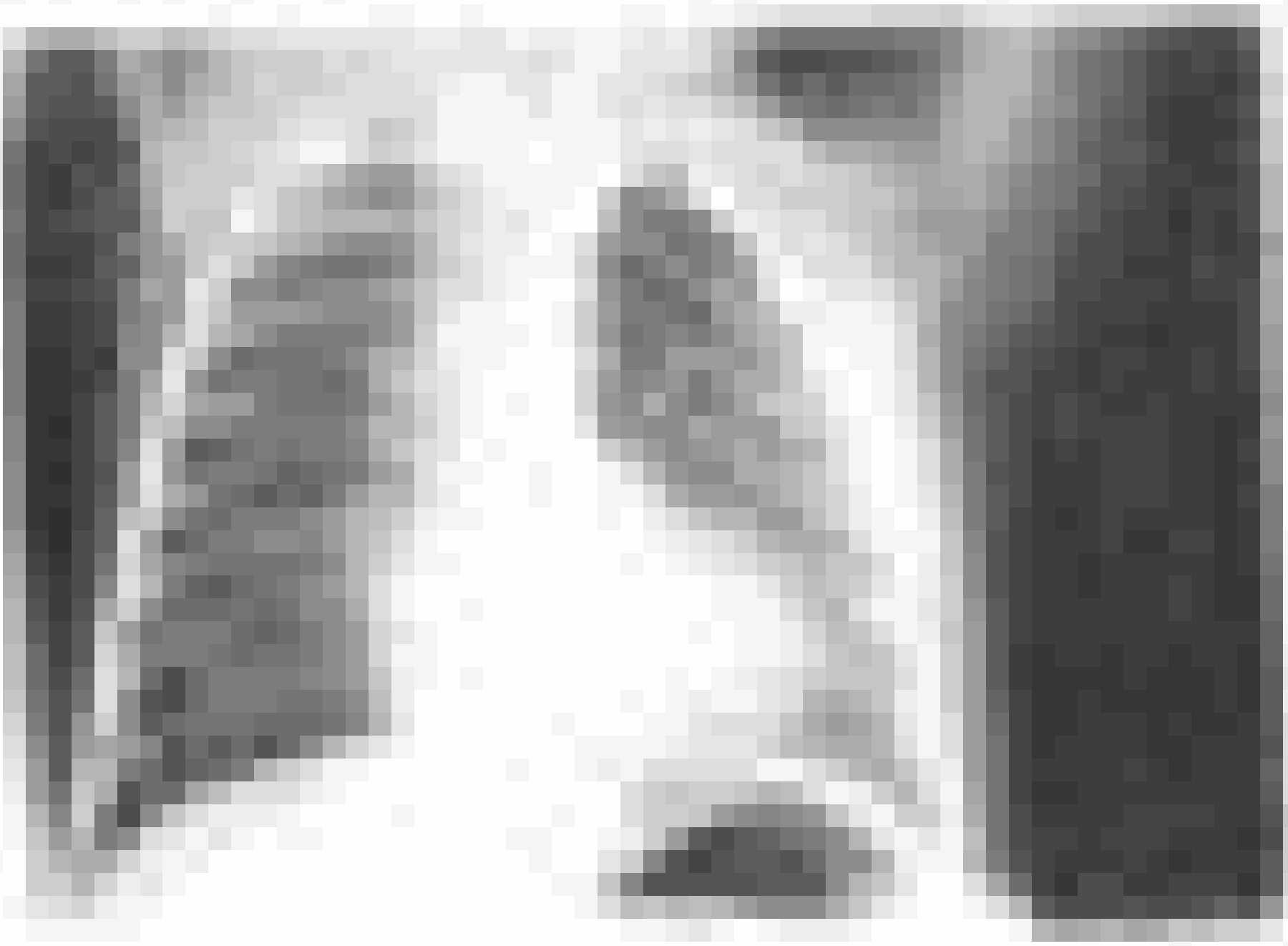

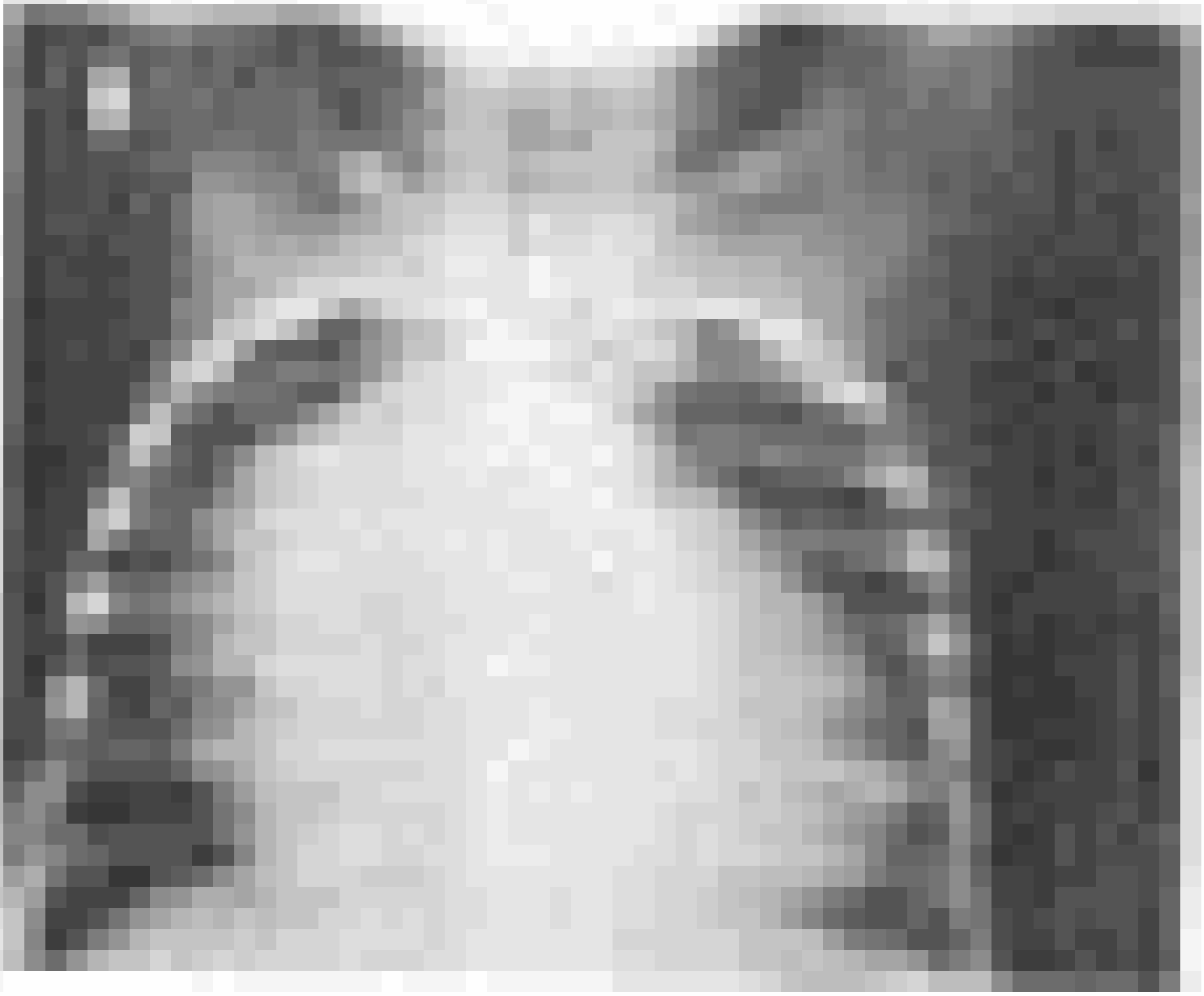

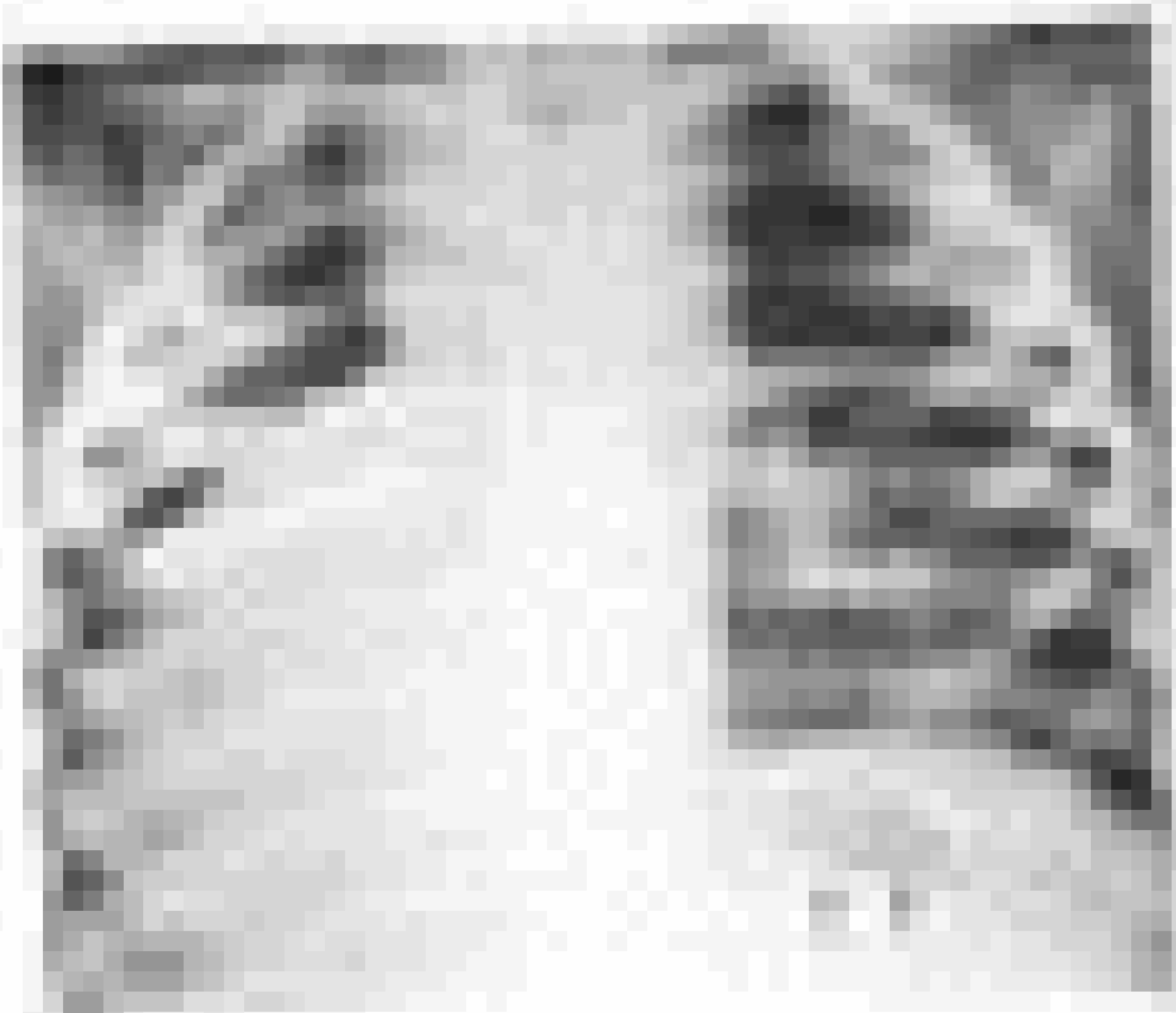

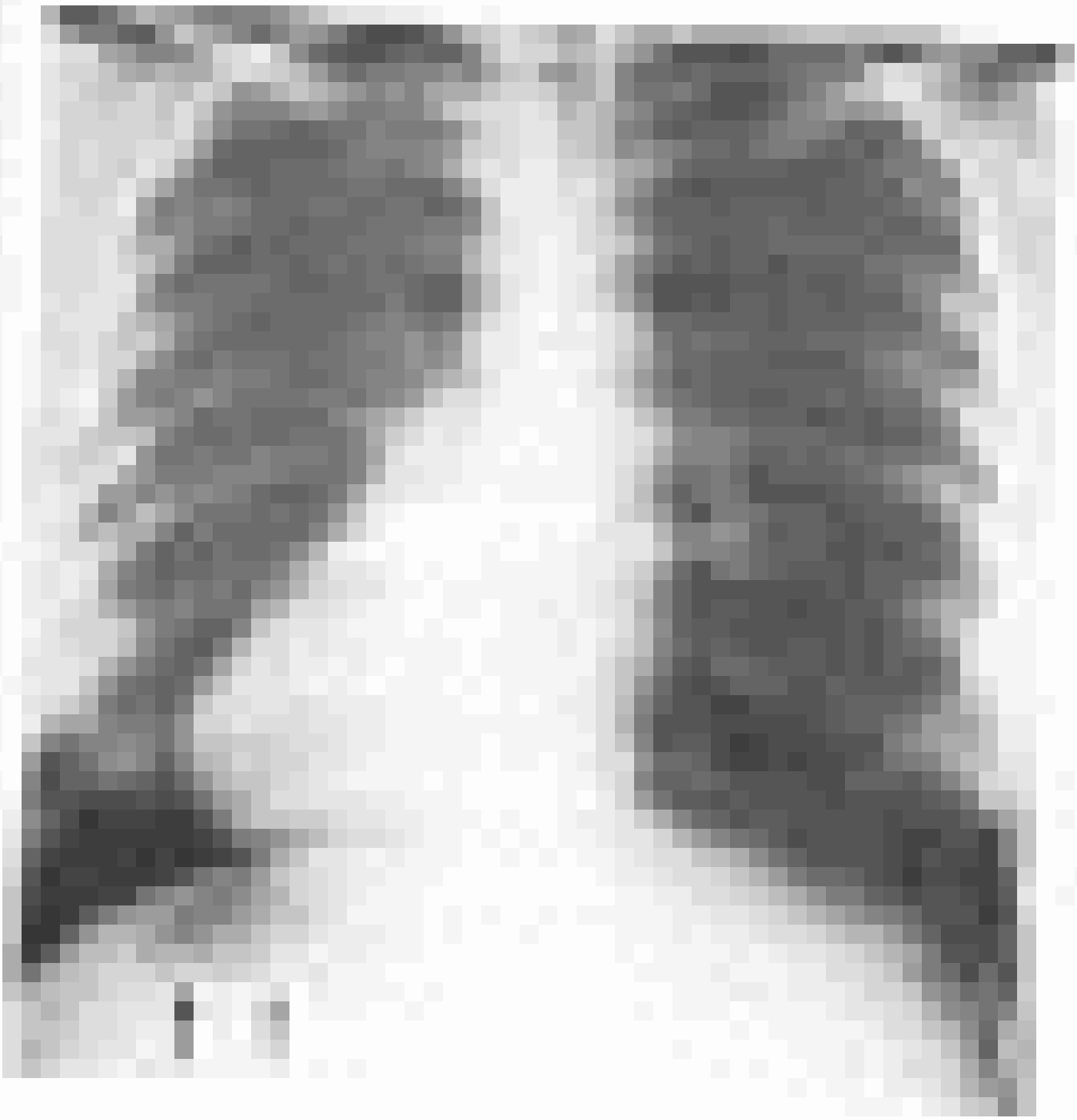

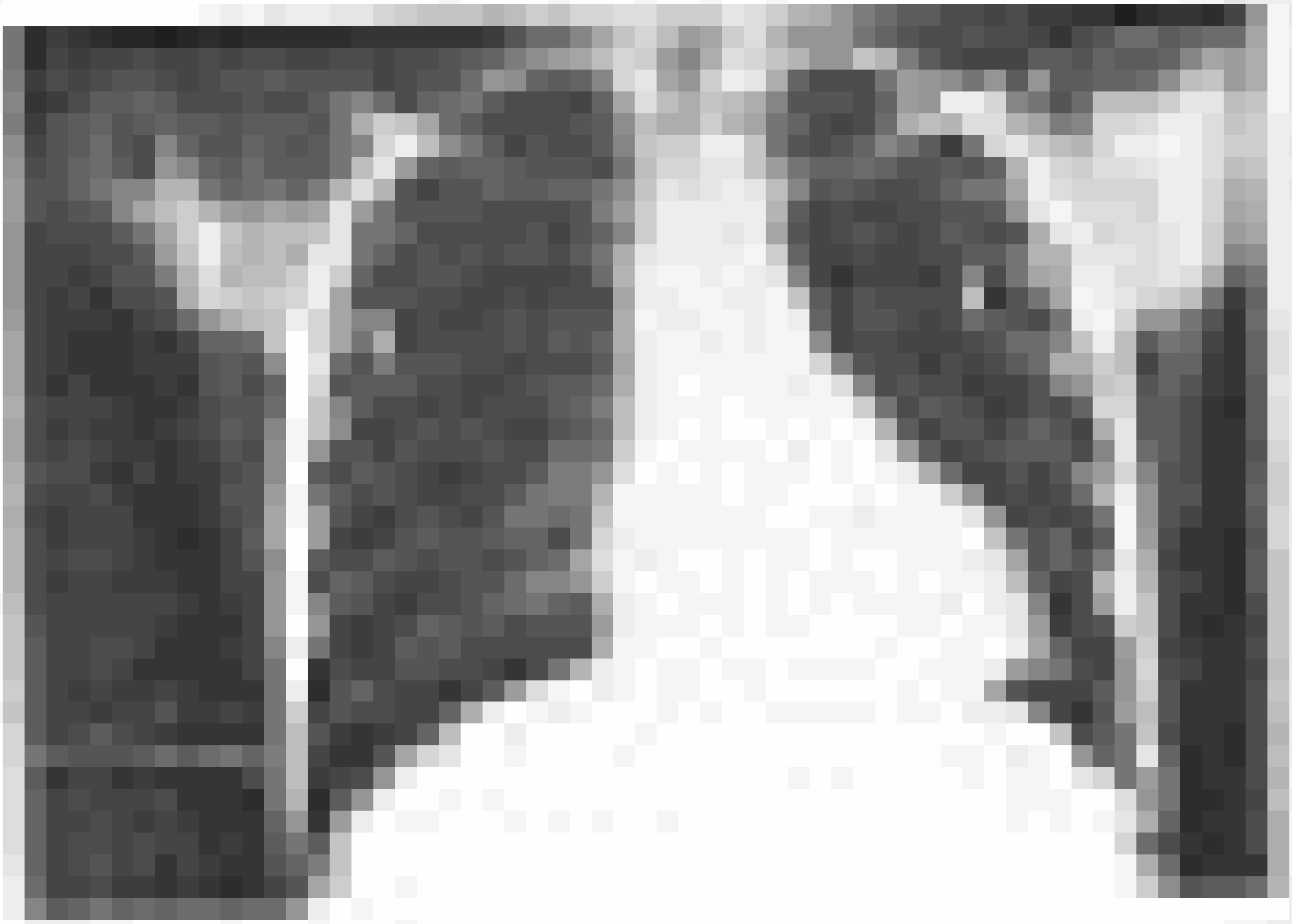

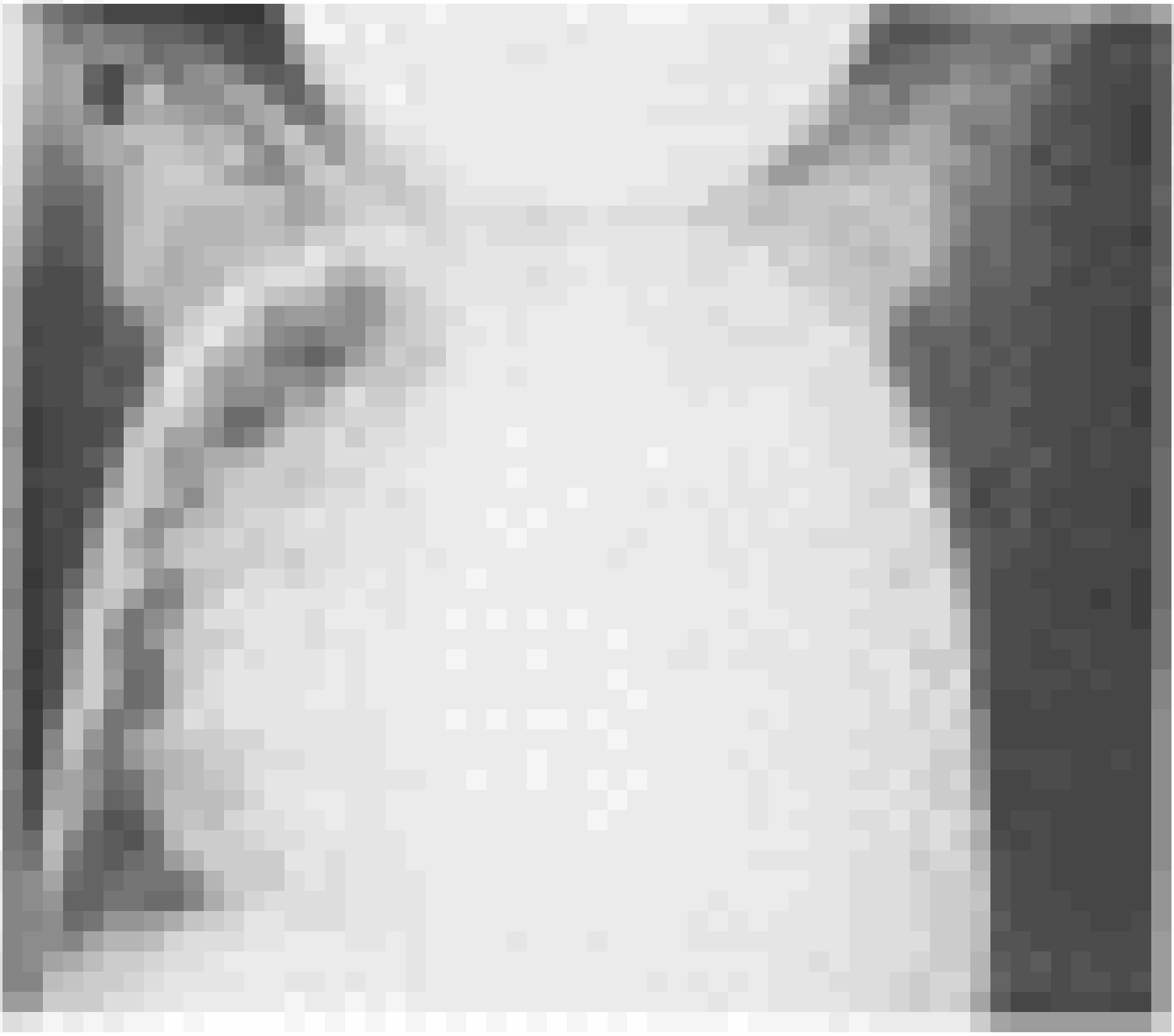





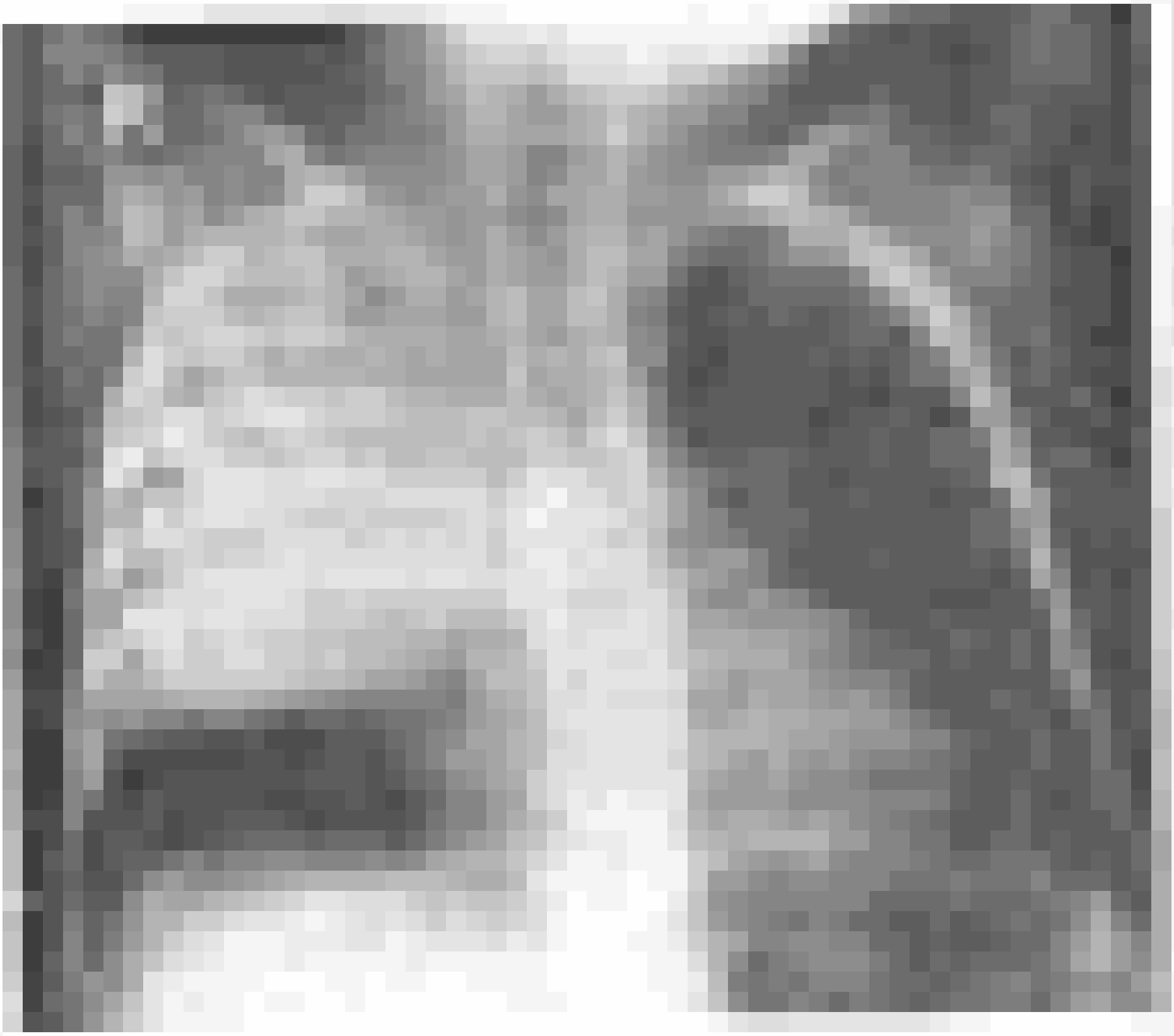

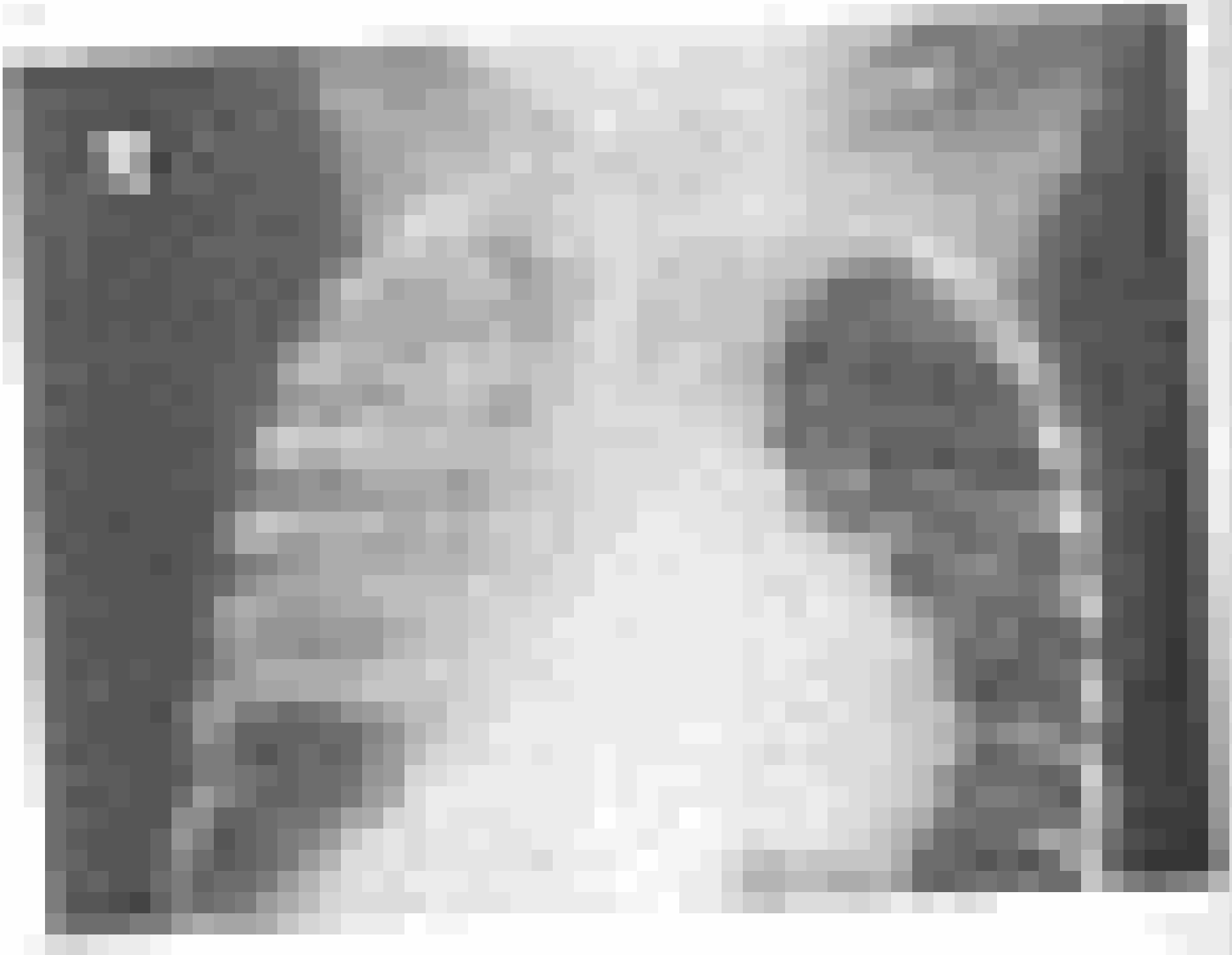



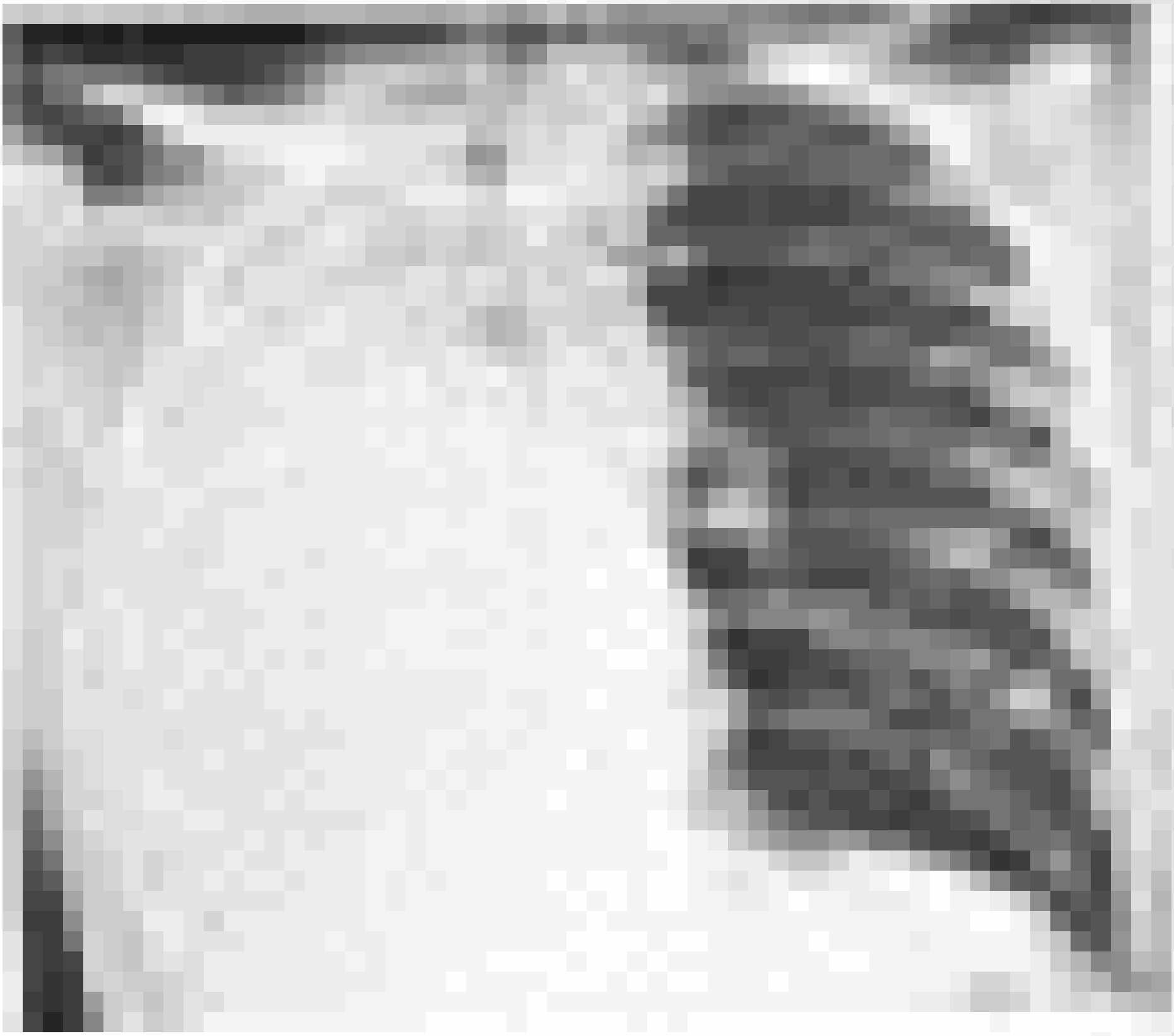

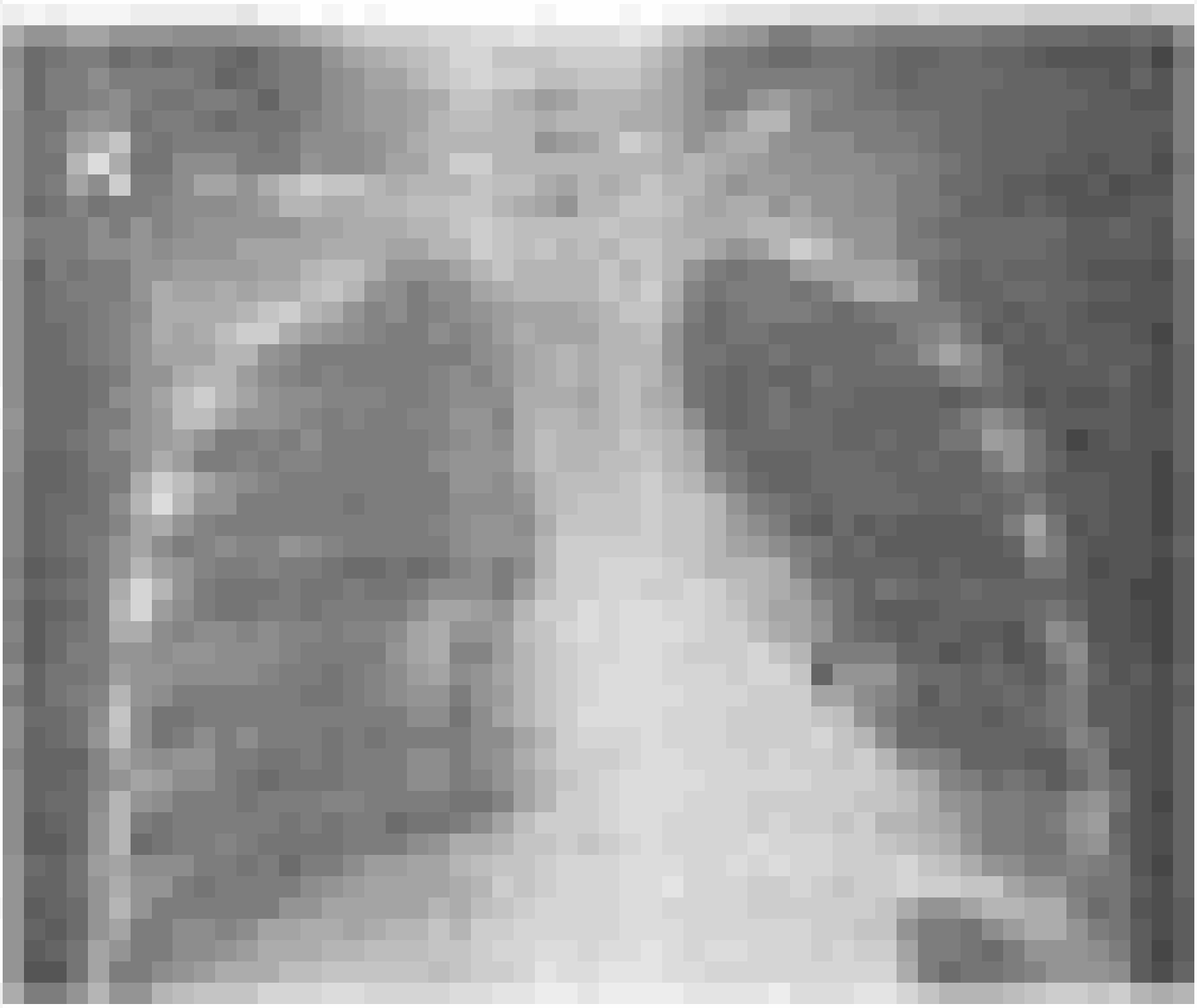

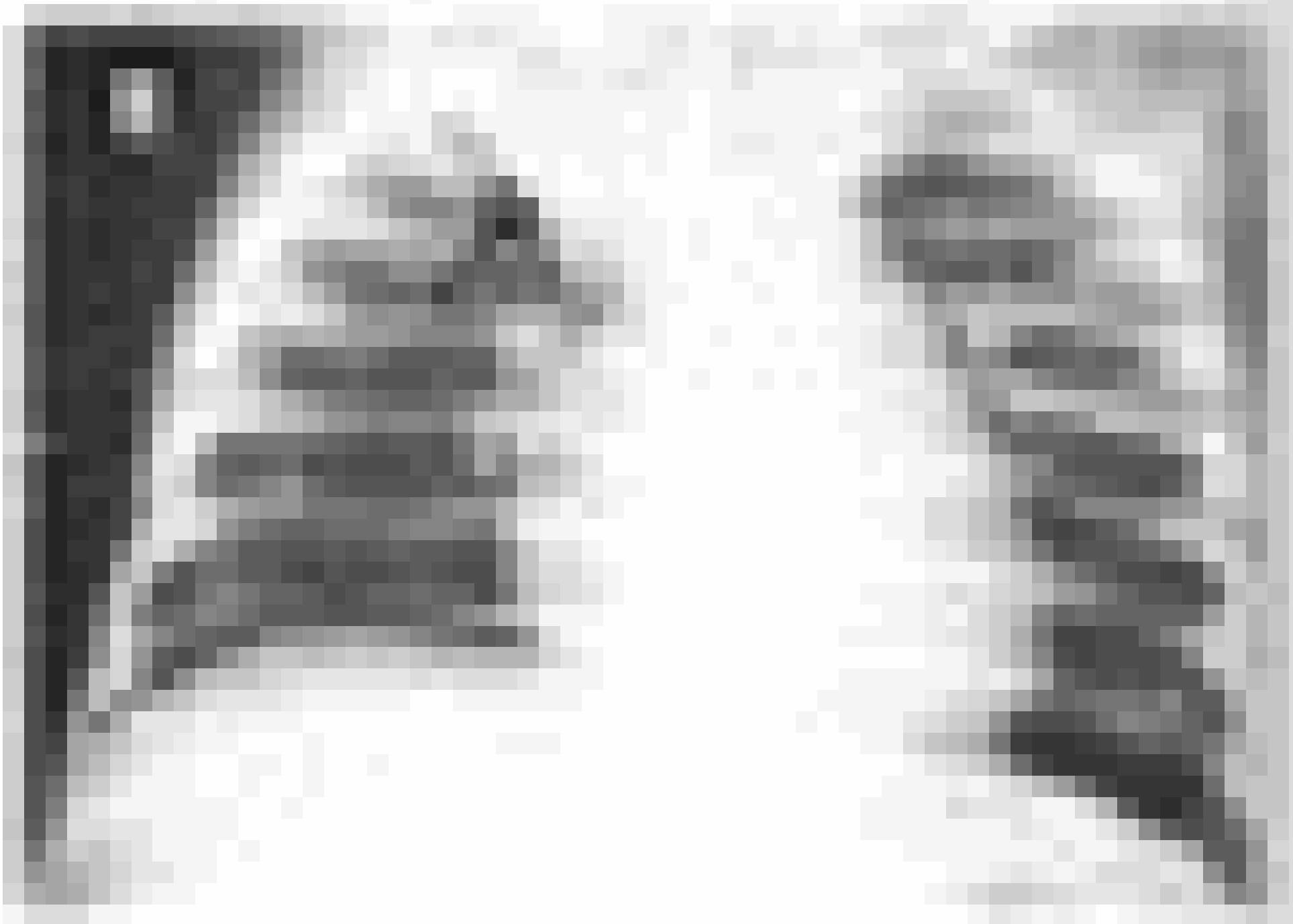

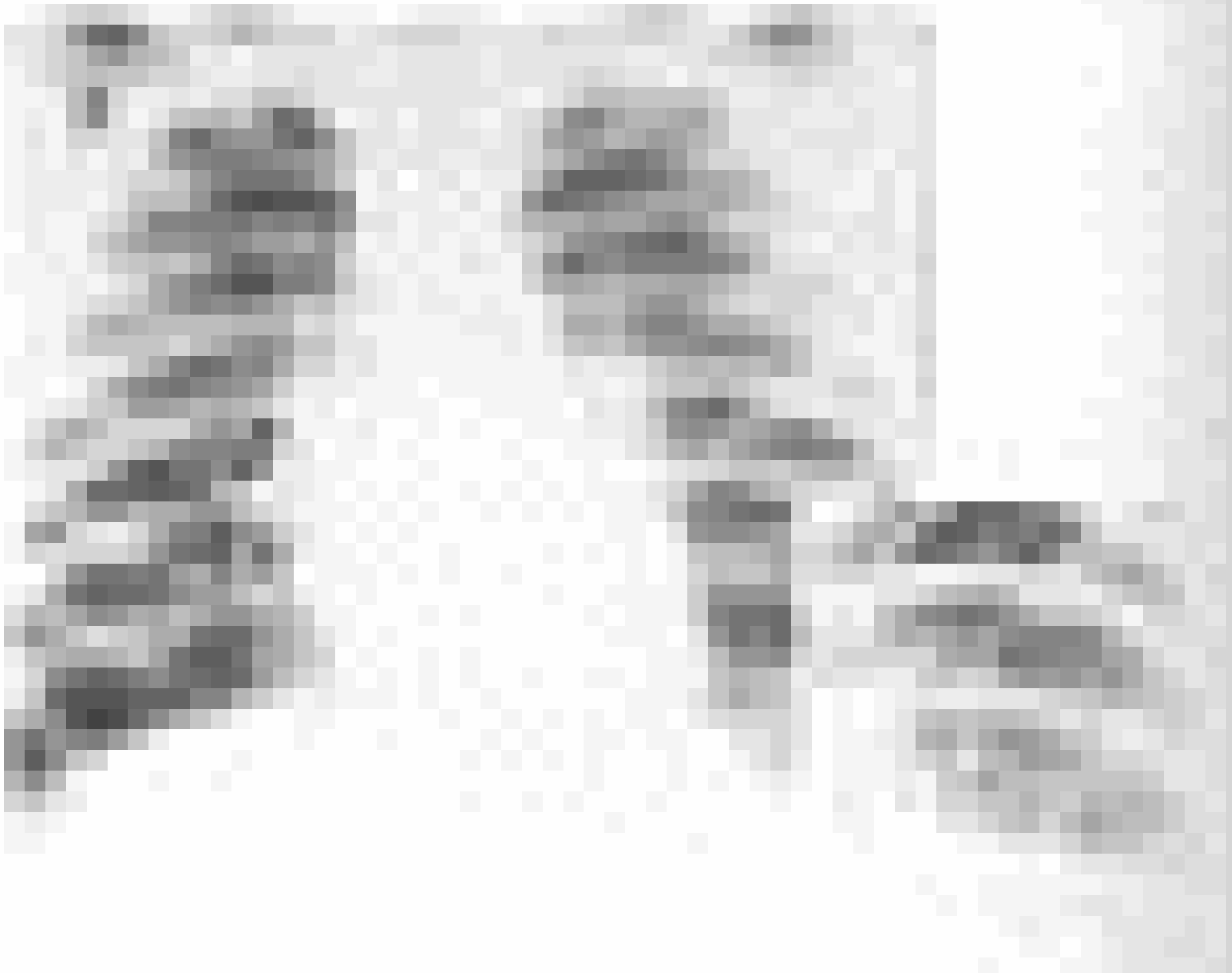

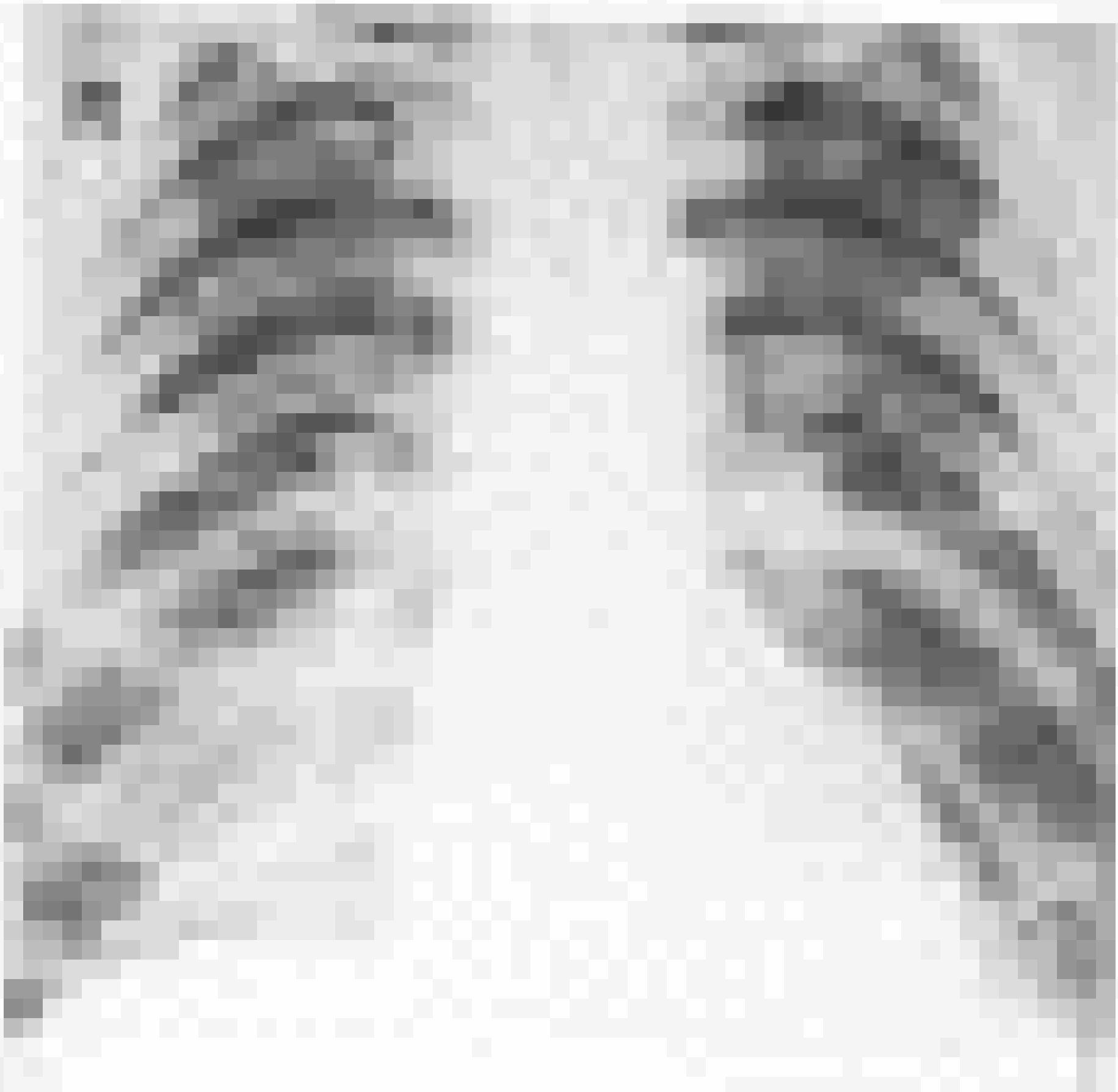

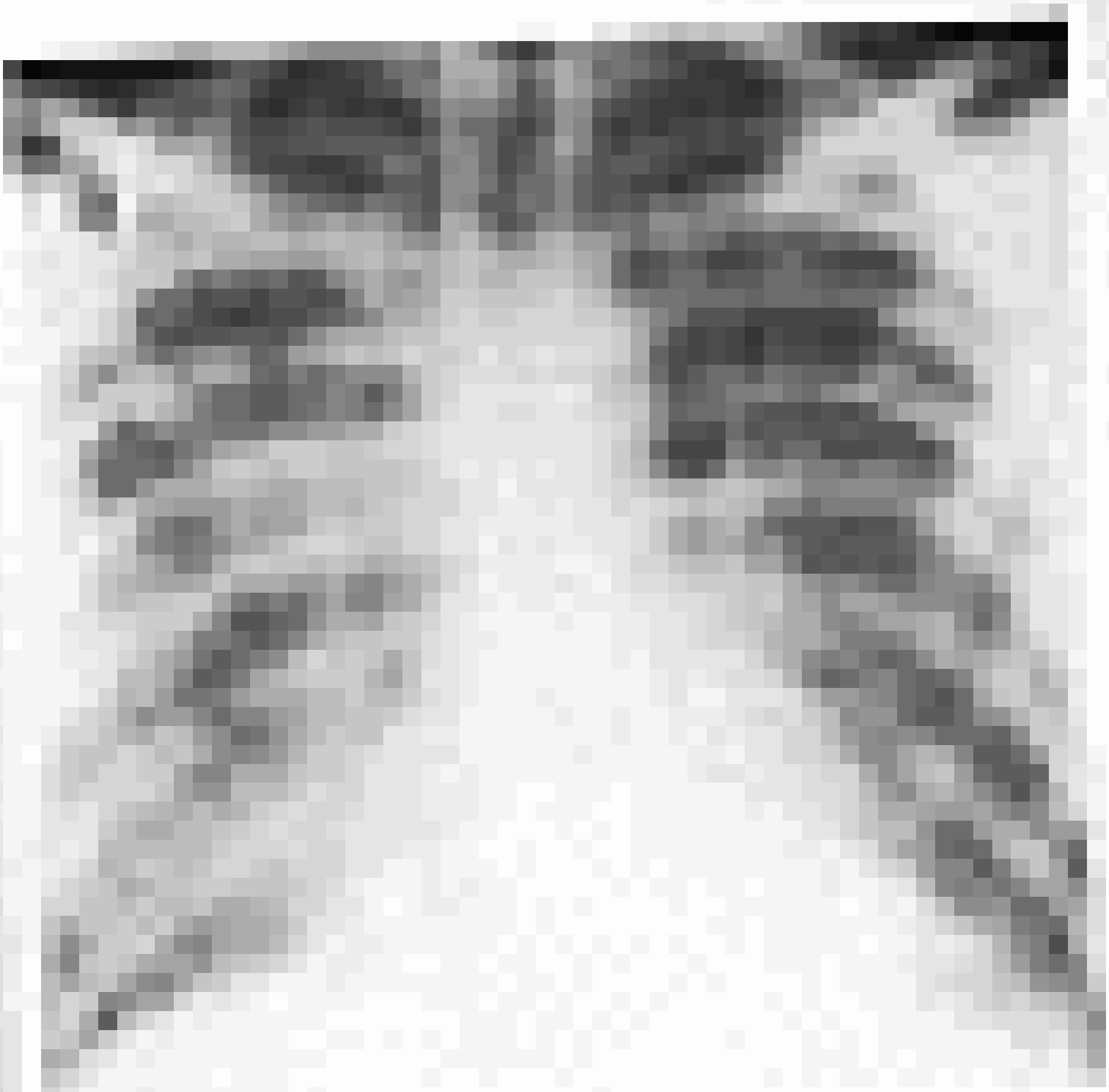

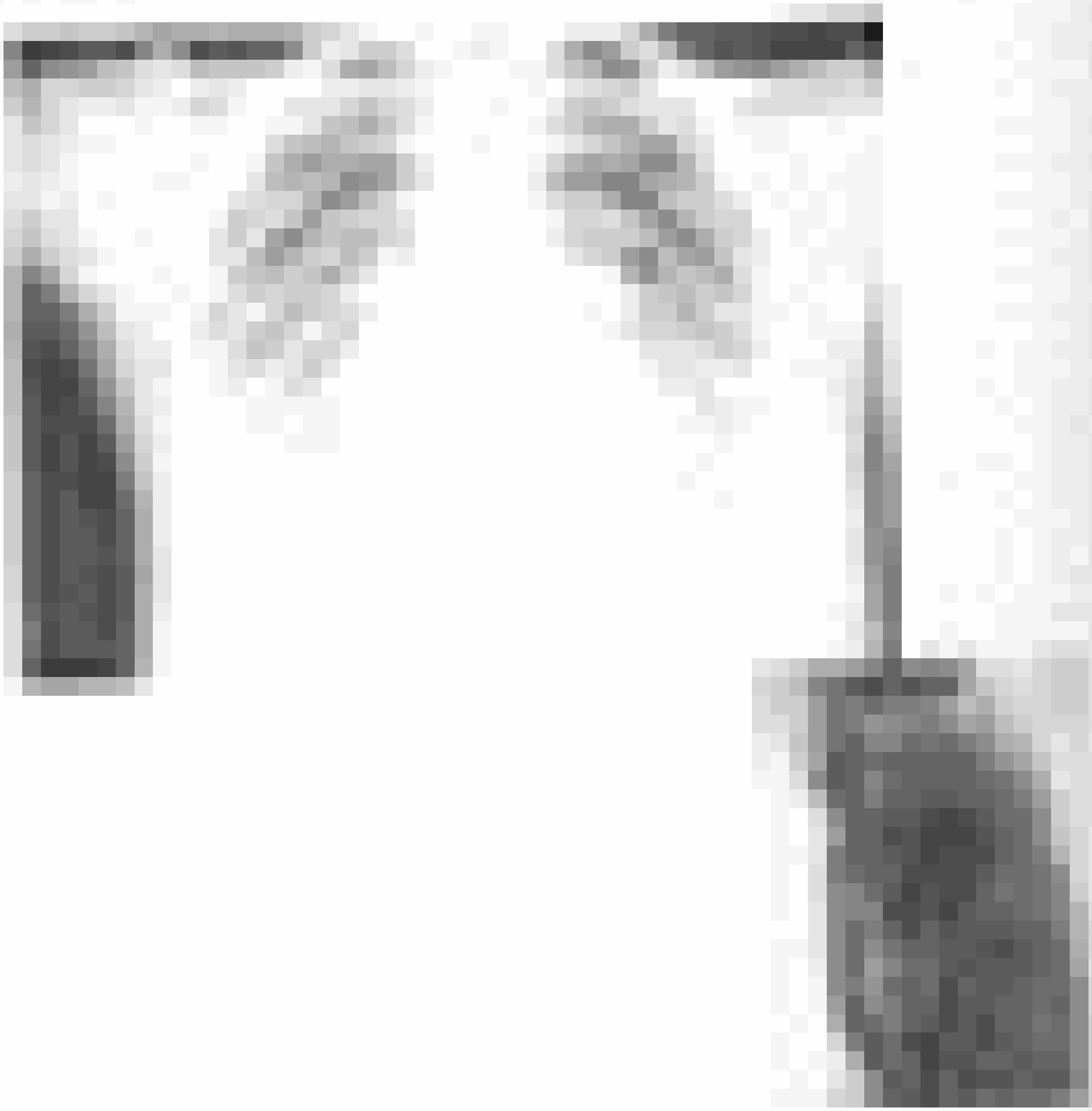





[illegible]

[illegible]

[illegible]

[illegible]
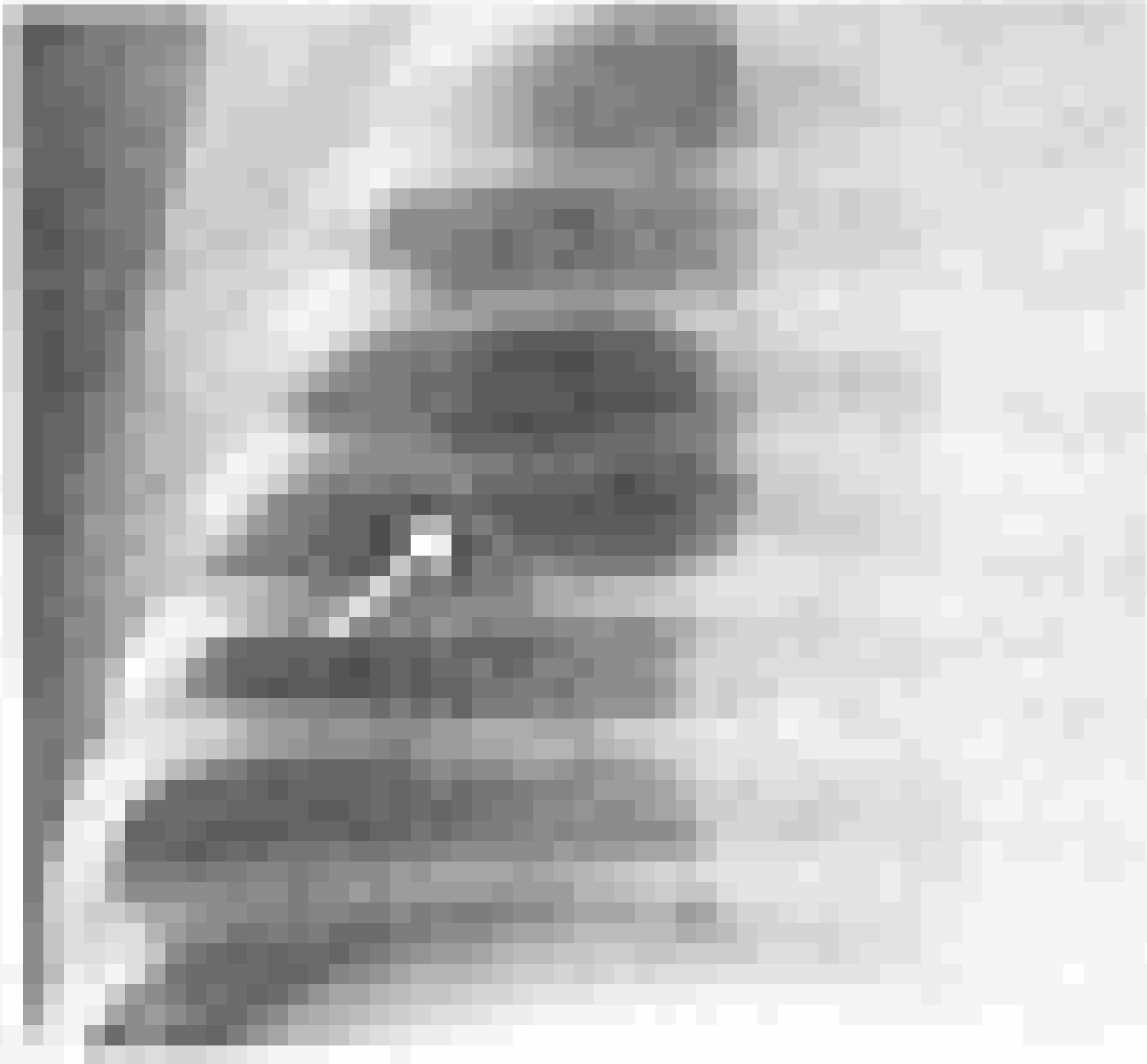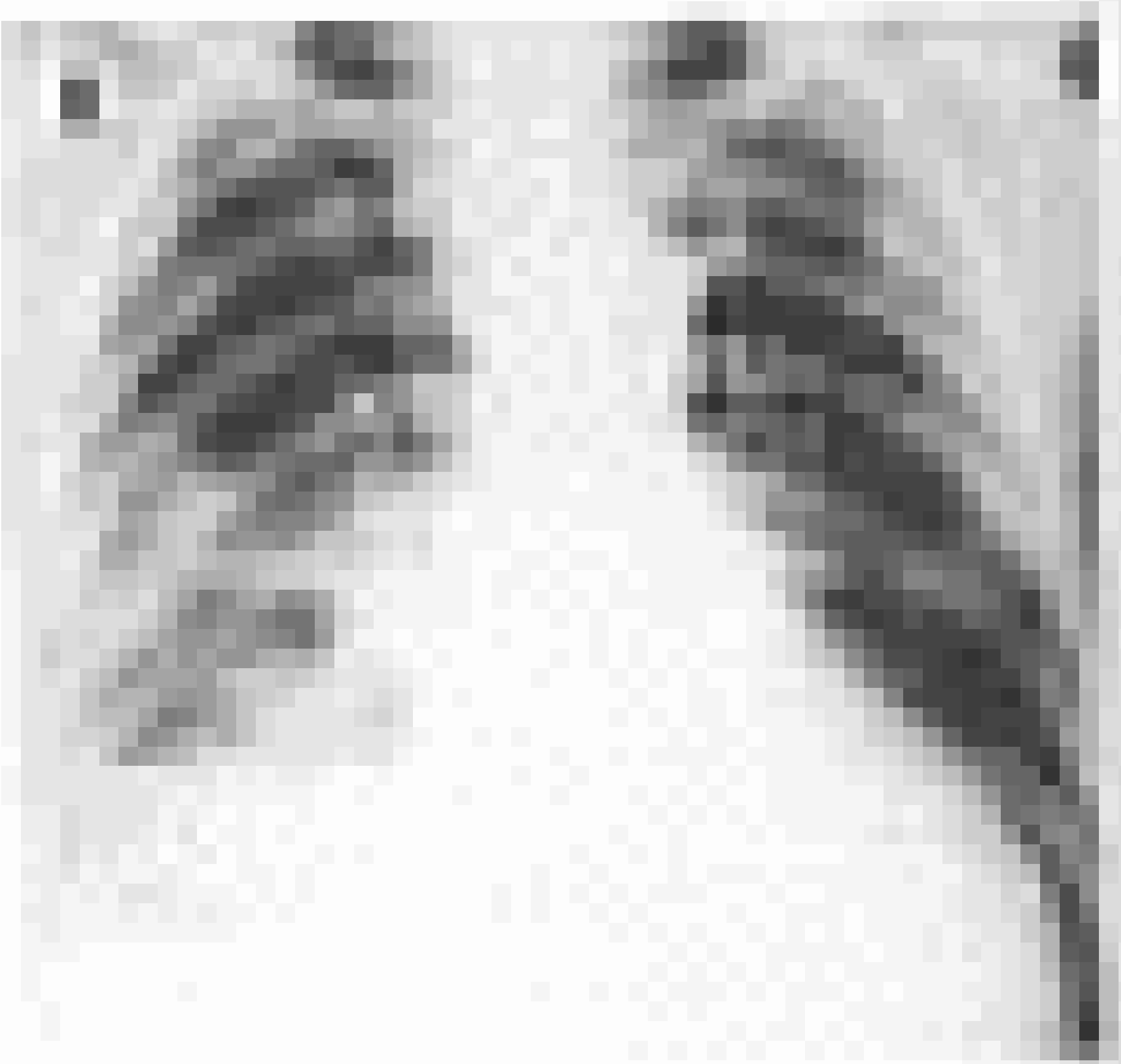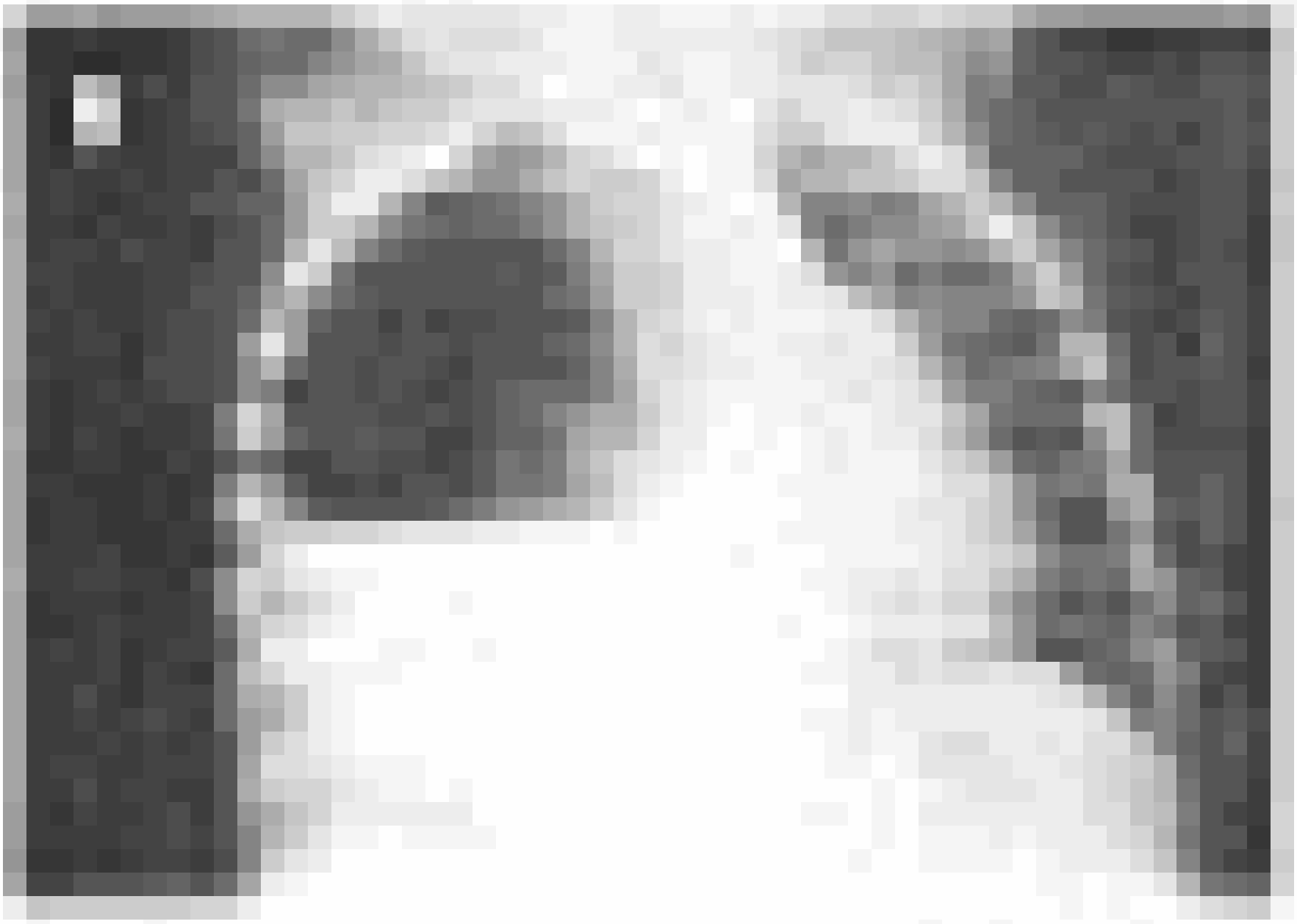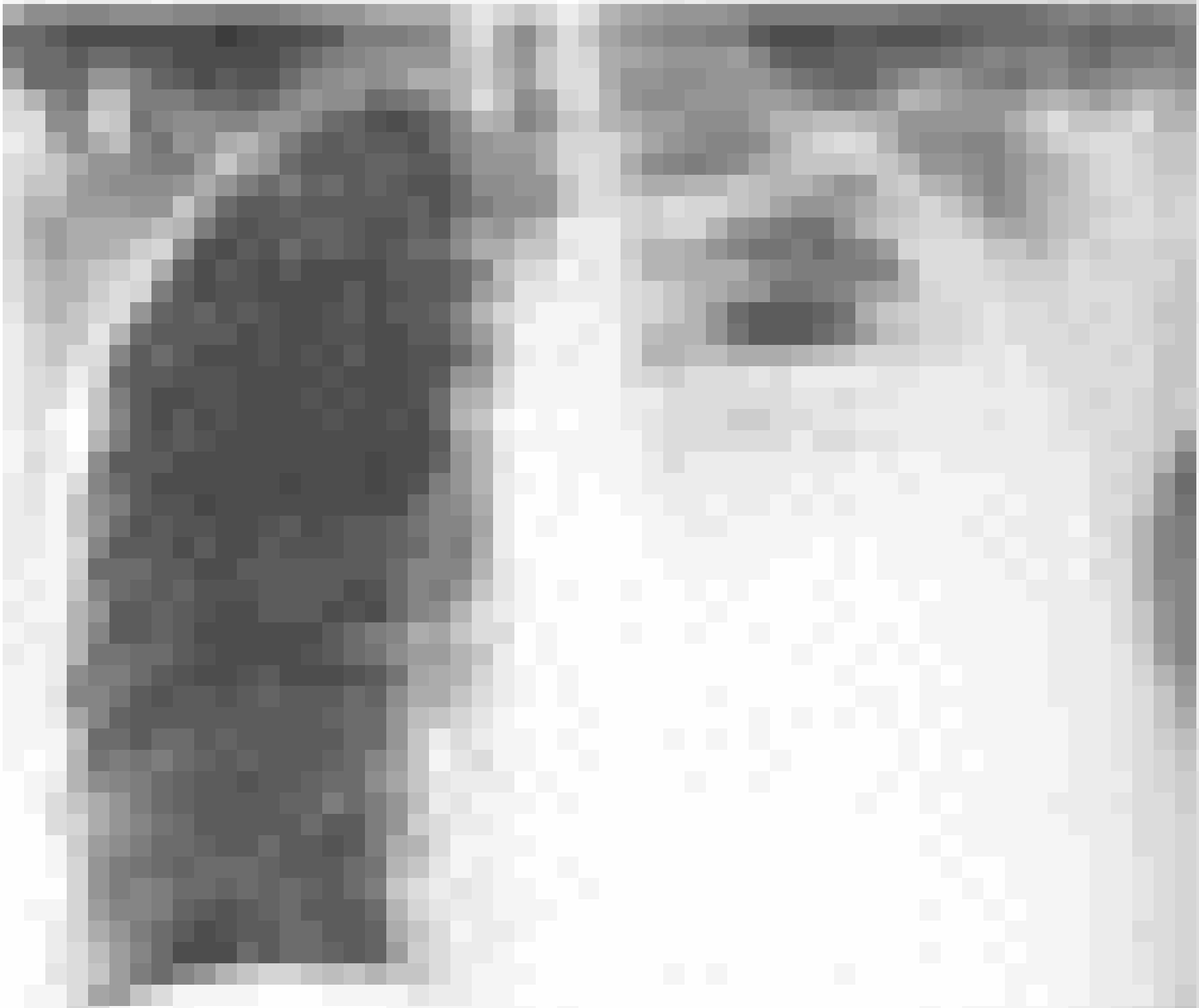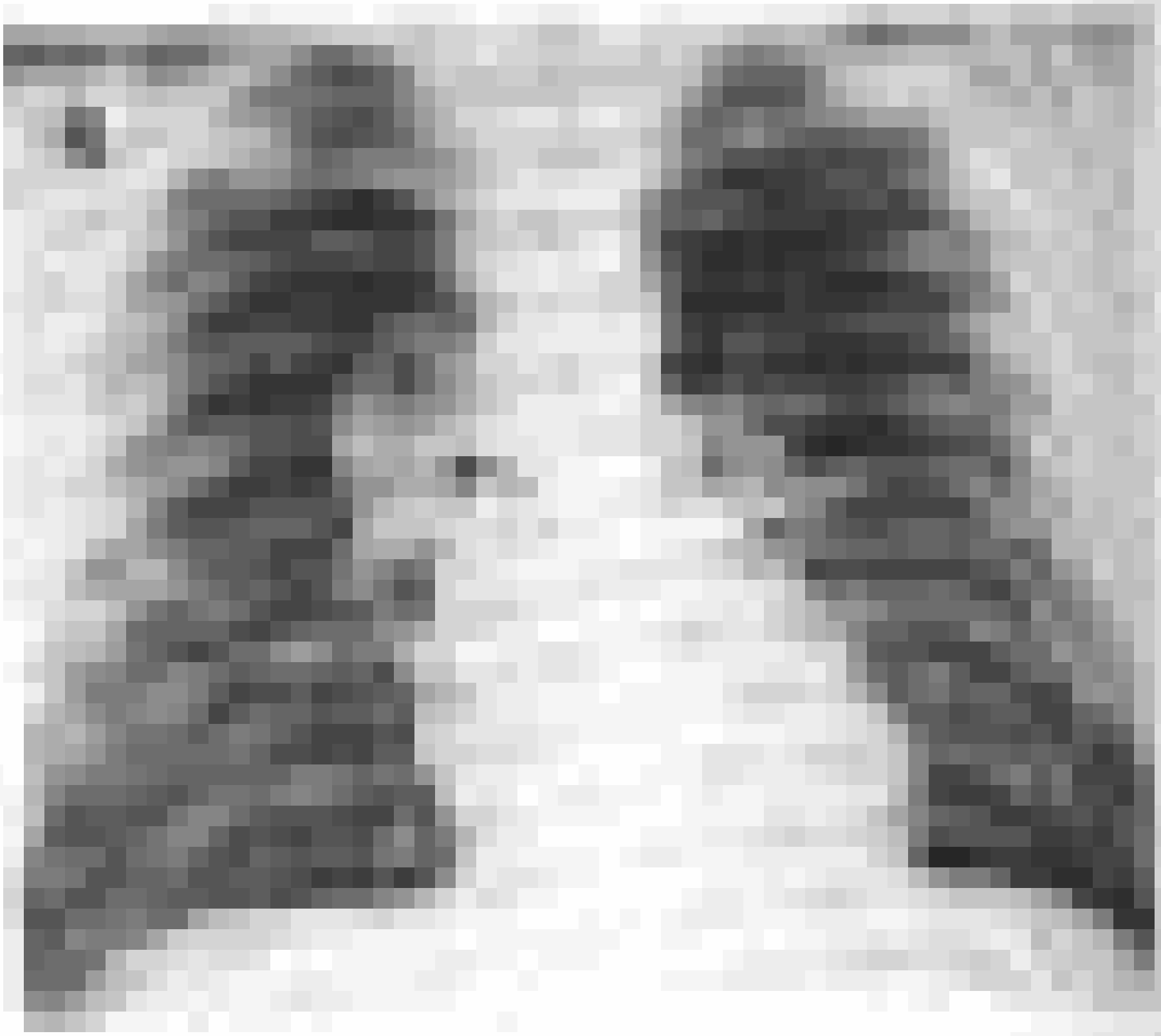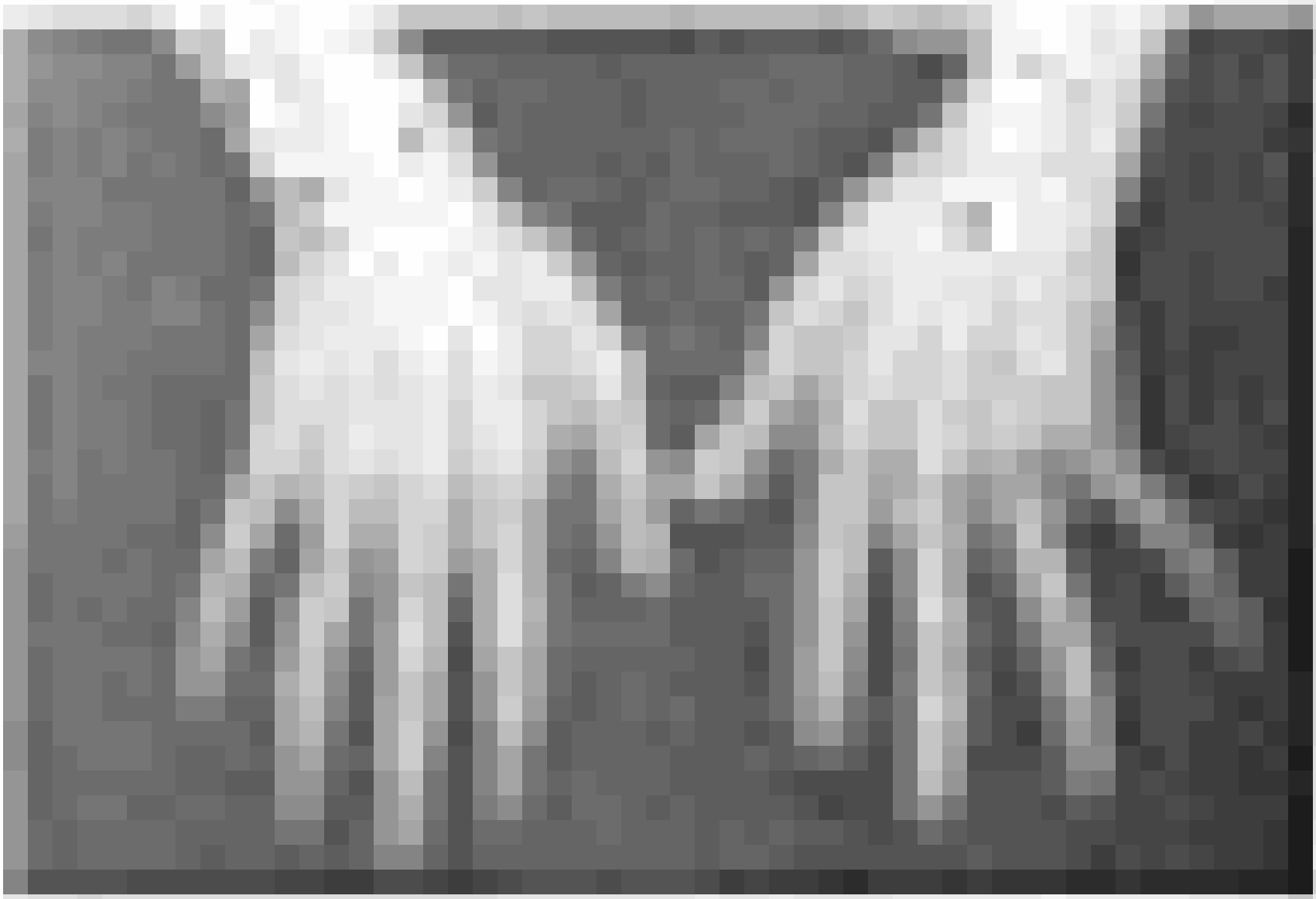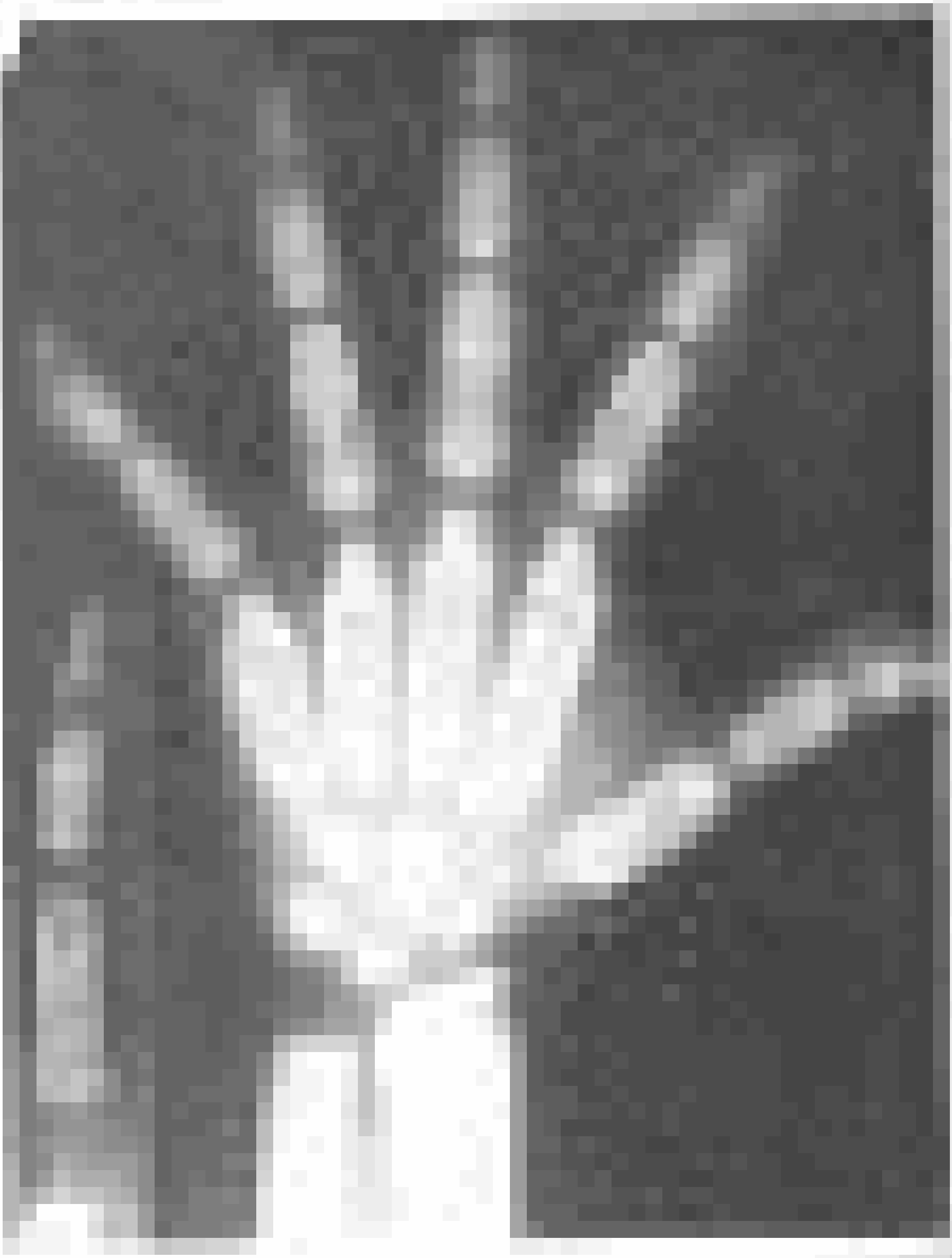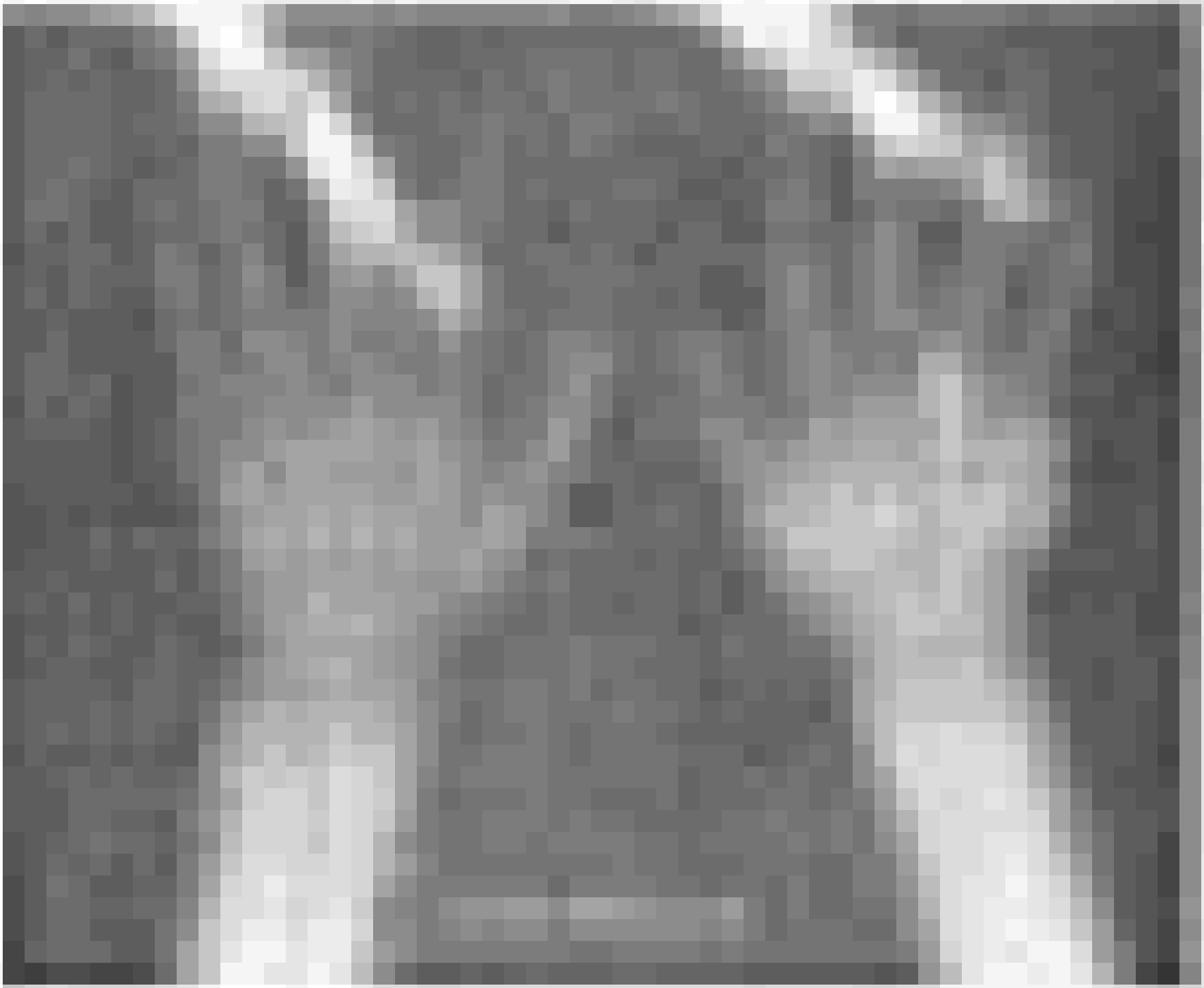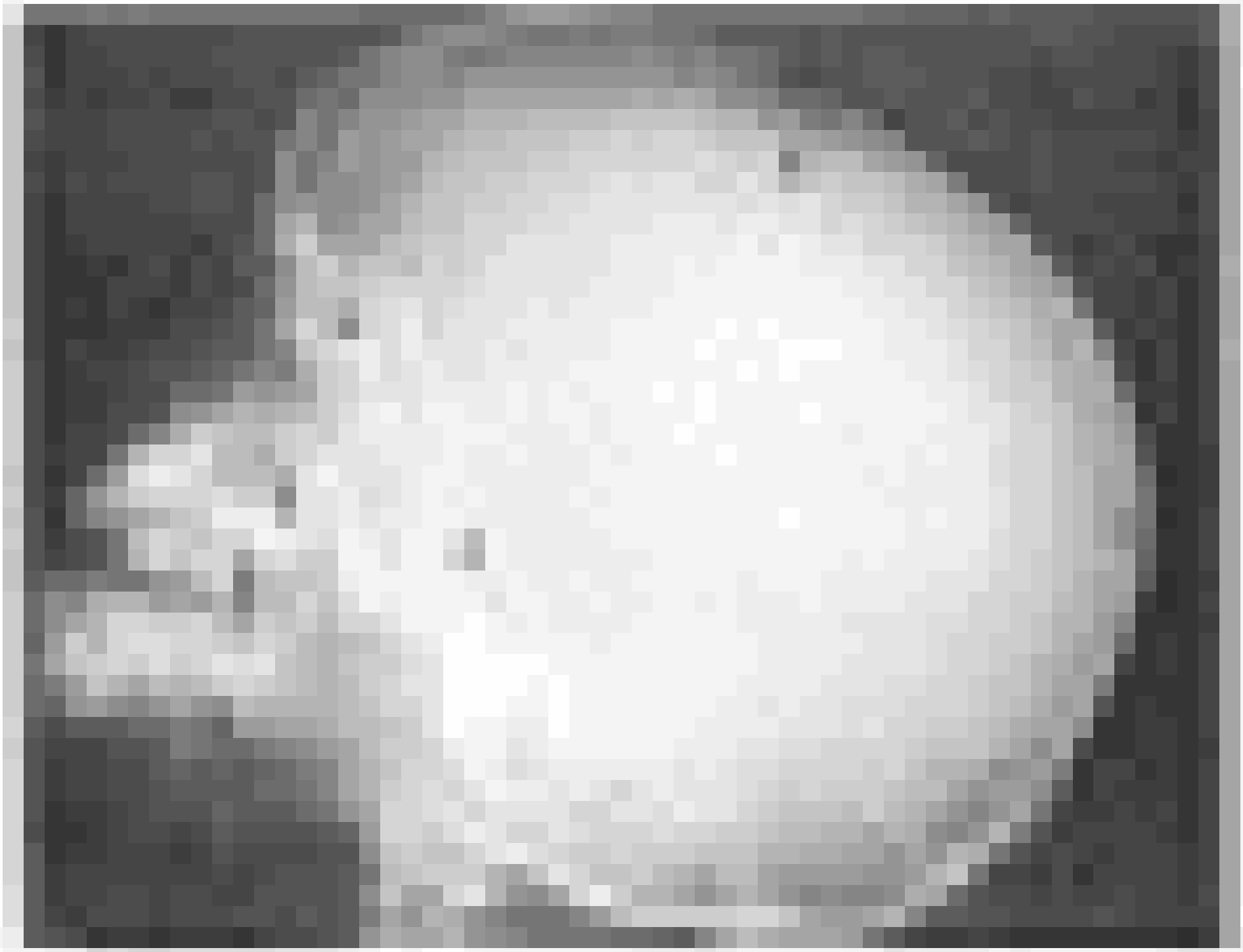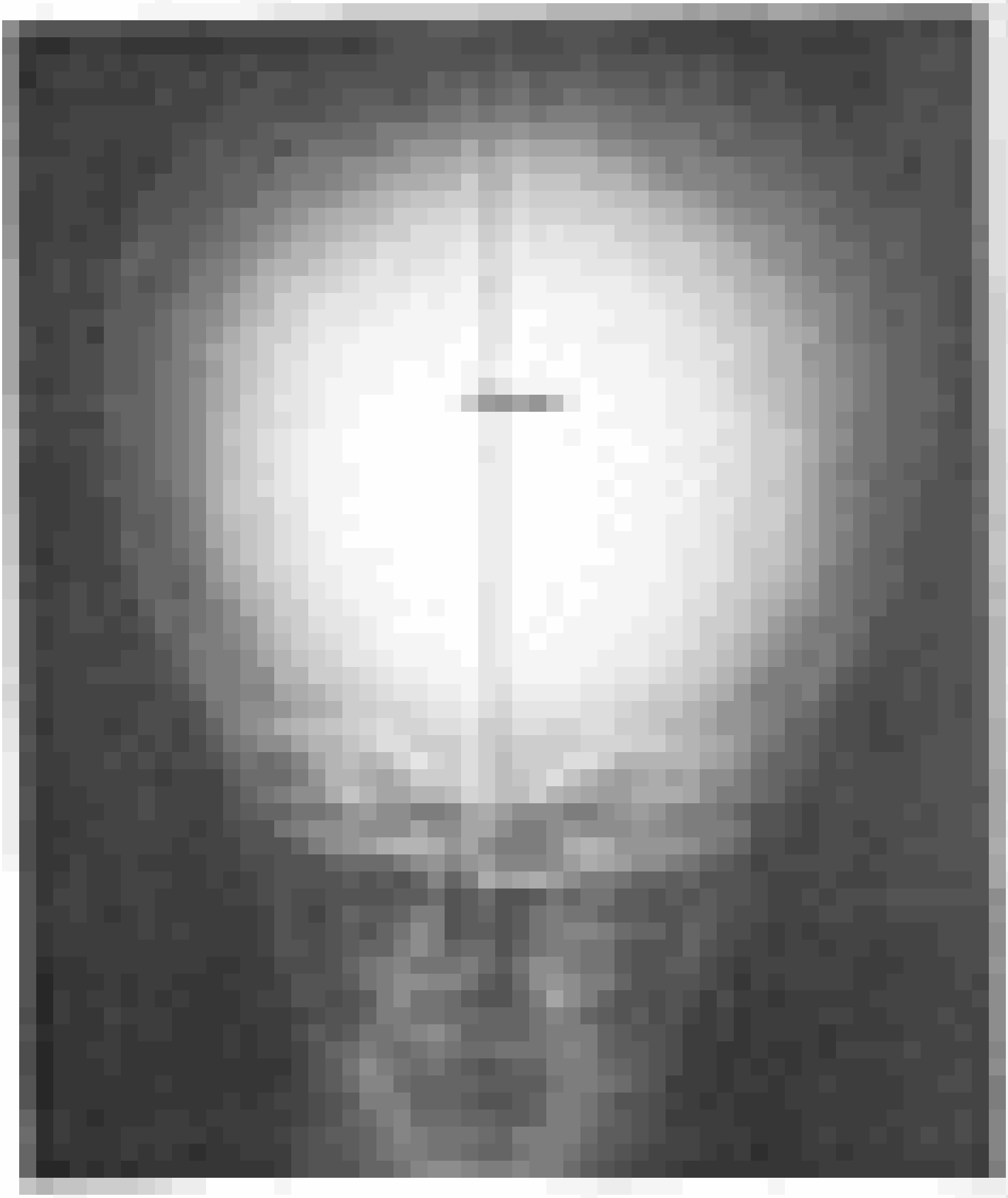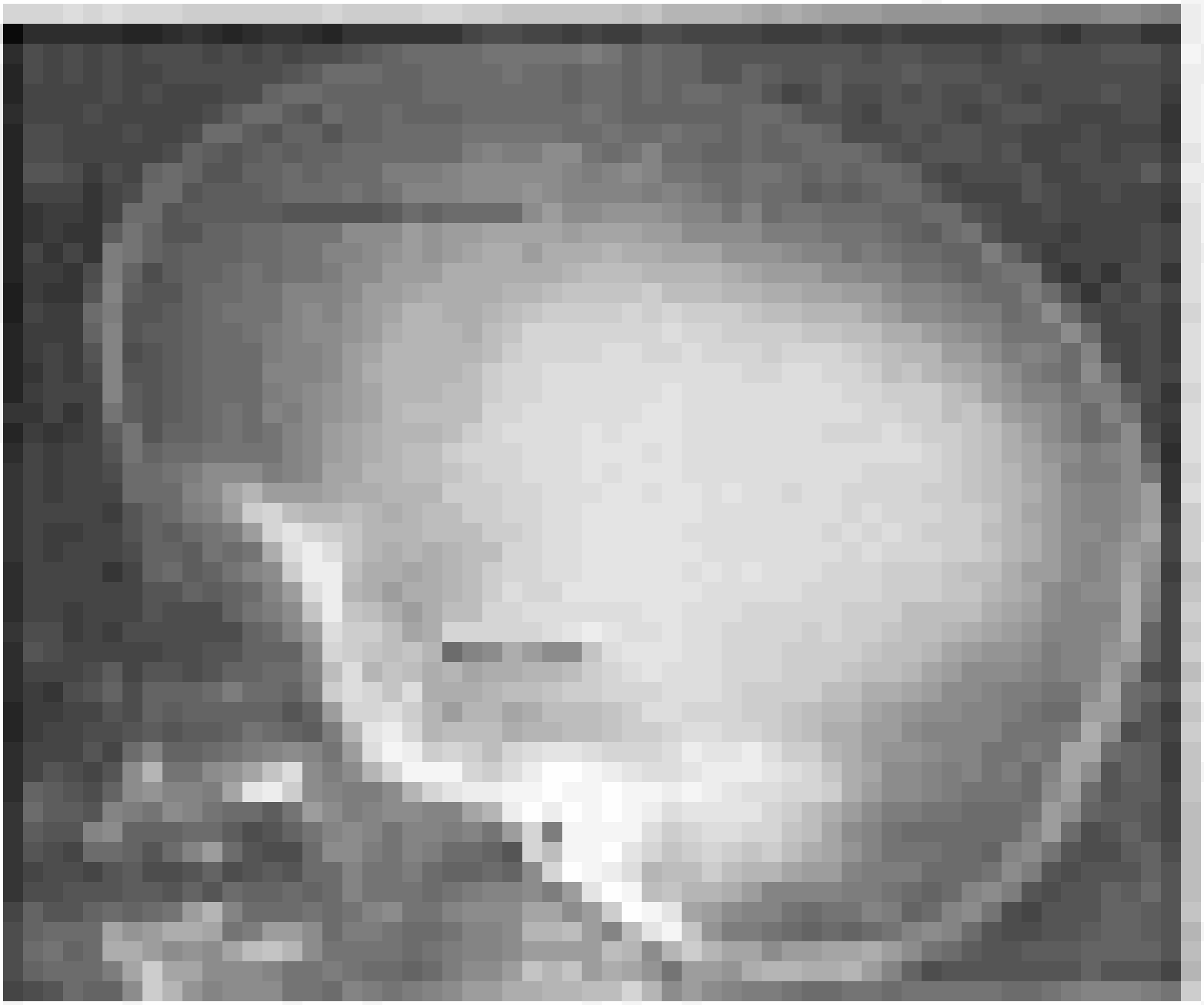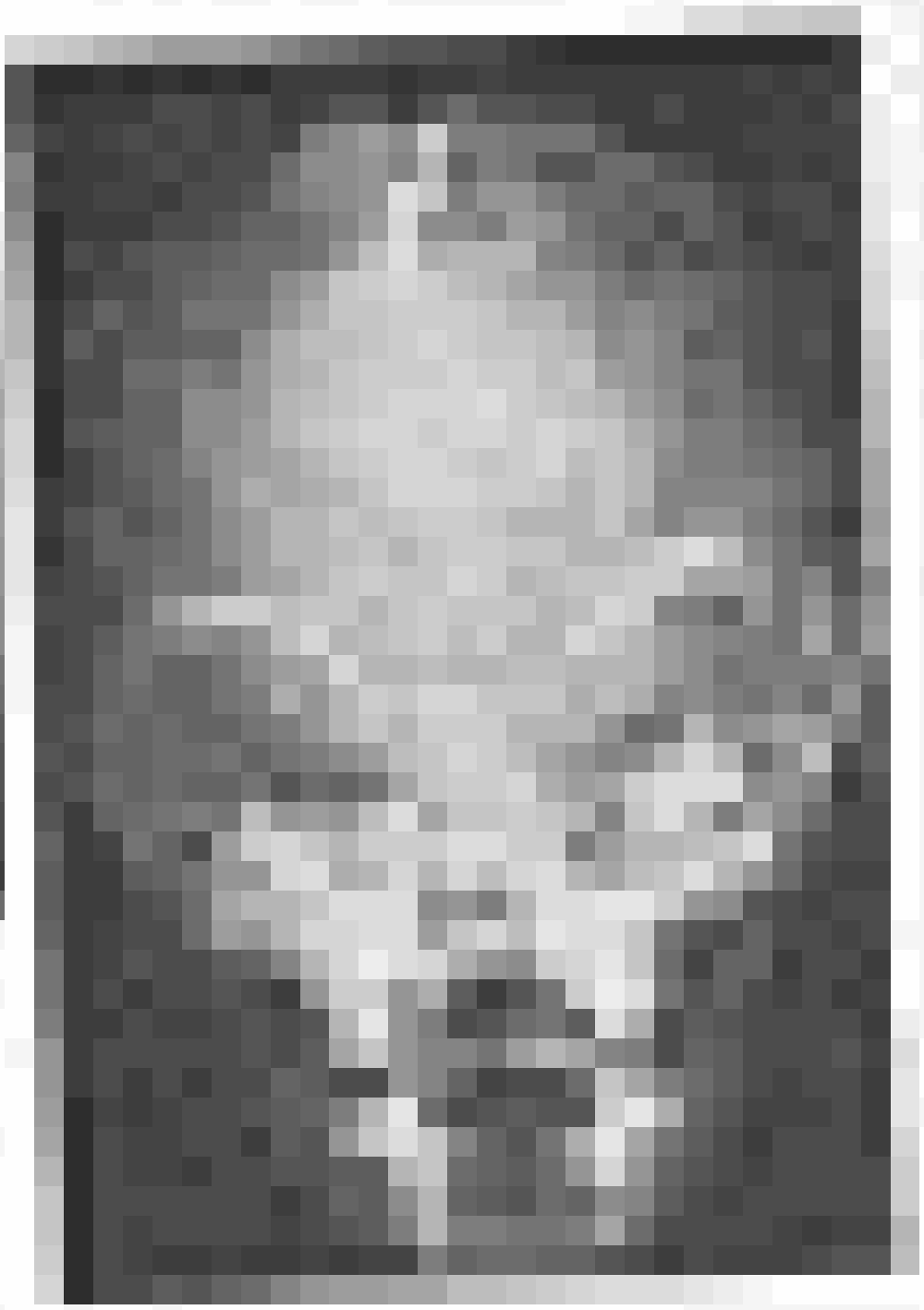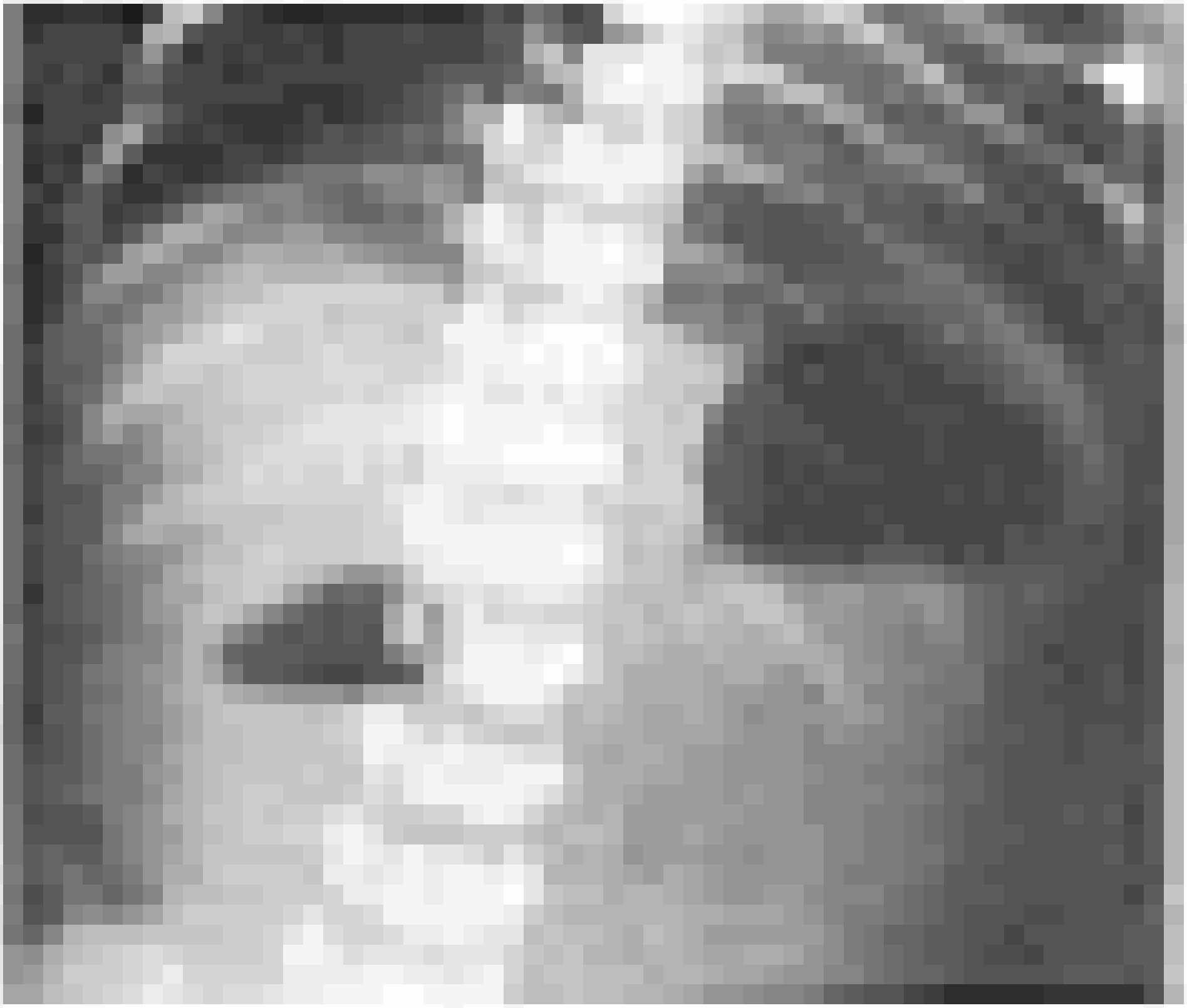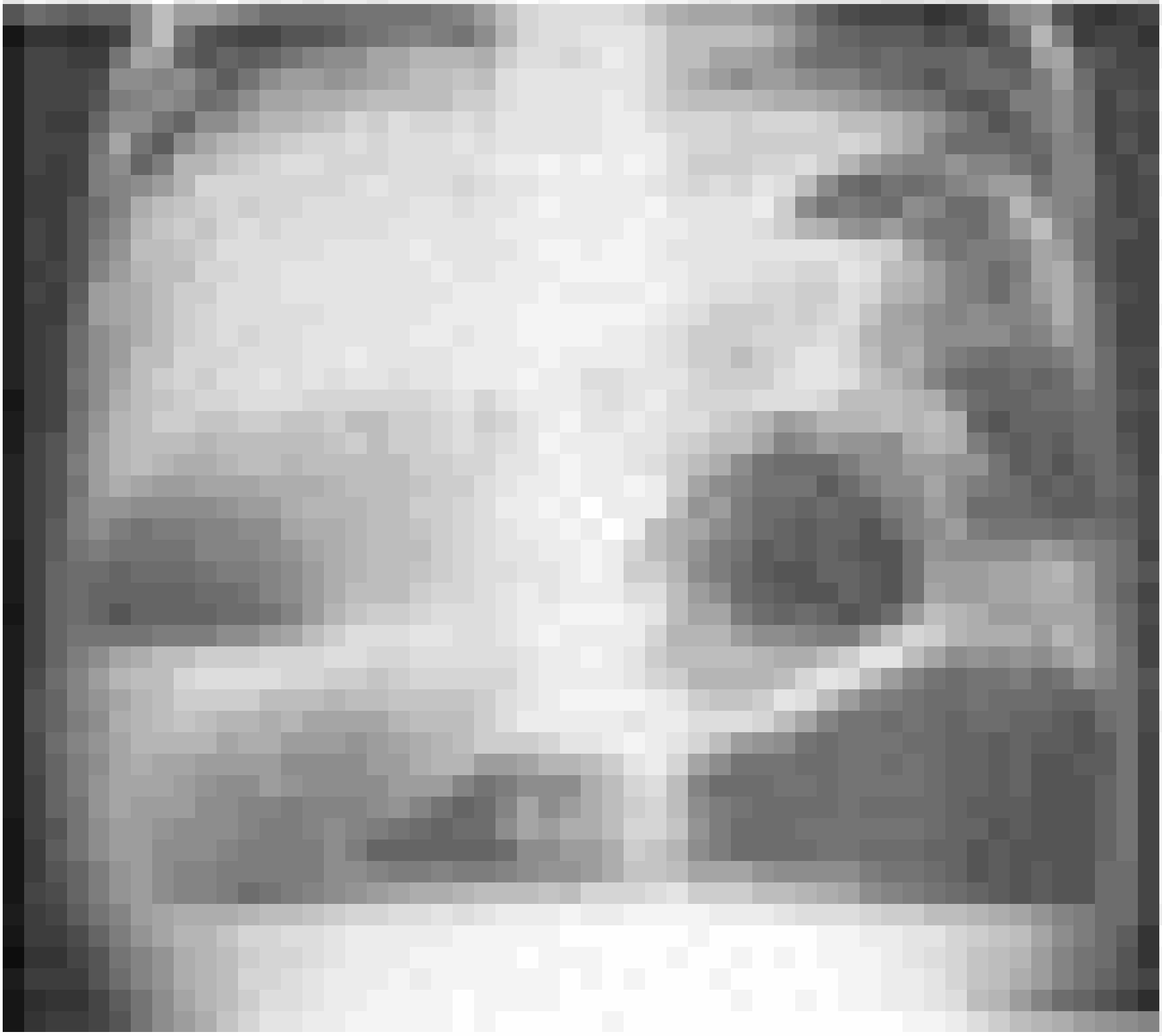
[illegible]